



# 30 Health Assessment

## LEARNING OUTCOMES

After completing this chapter, you will be able to:

1. Identify the purposes of the physical examination.
2. Explain the four techniques used in physical examination: inspection, palpation, percussion, and auscultation.
3. Identify expected findings during health assessment.
4. Verbalize the steps used in performing selected examination procedures:
  - a. Assessing appearance and mental status.
  - b. Assessing the skin.
  - c. Assessing the hair.
  - d. Assessing the nails.
  - e. Assessing the skull and face.
  - f. Assessing the eye structures and visual acuity.
  - g. Assessing the ears and hearing.
  - h. Assessing the nose and sinuses.
  - i. Assessing the mouth and oropharynx.
  - j. Assessing the neck.
  - k. Assessing the thorax and lungs.
  - l. Assessing the heart and central vessels.
  - m. Assessing the peripheral vascular system.
  - n. Assessing the breasts and axillae.
  - o. Assessing the abdomen.
  - p. Assessing the musculoskeletal system.
  - q. Assessing the neurologic system.
  - r. Assessing the female genitals and inguinal area.
  - s. Assessing the male genitals and inguinal area.
  - t. Assessing the anus.
5. Describe suggested sequencing to conduct a physical health examination in an orderly fashion.
6. Discuss variations in examination techniques appropriate for clients of different ages.
7. Recognize when it is appropriate to delegate assessment skills to unlicensed assistive personnel.
8. Demonstrate appropriate documentation and reporting of health assessment.

## KEY TERMS

- adventitious breath sounds, 555  
alopecia, 528  
angle of Louis, 553  
antihelix, 539  
aphasia, 580  
astigmatism, 533  
auricle, 539  
auscultation, 519  
blanch test, 530  
bruit, 562  
caries, 546  
cataracts, 533  
cerumen, 539  
clubbing, 530  
cochlea, 540  
conductive hearing loss, 540  
conjunctivitis, 533  
cyanosis, 523  
dacryocystitis, 533  
diastole, 561  
dullness, 519  
duration, 519  
edema, 523  
erythema, 523  
eustachian tube, 540  
exophthalmos, 532  
external auditory meatus, 539  
extinction, 582  
fasciculation, 577  
flatness, 519  
fremitus, 557  
gingivitis, 546  
glaucoma, 533  
glossitis, 546  
goniometer, 579  
helix, 539  
hernia, 593  
hordeolum (sty), 533  
hyperopia, 533  
hyperresonance, 519  
incus, 540  
inspection, 517  
intensity, 519  
intention tremor, 577  
jaundice, 523  
lift, 560  
lobule, 539  
malleus, 540  
manubrium, 554  
mastoid, 539  
miosis, 534  
mixed hearing loss, 540  
mydriasis, 534  
myopia, 533  
normocephalic, 531  
nystagmus, 536  
one-point discrimination, 582  
ossicles, 540  
otoscope, 539  
pallor, 523  
palpation, 517  
parotitis, 546  
percussion, 518  
perfusion, 566  
periodontal disease, 546  
PERRLA, 537  
pinna, 539  
pitch, 519  
plaque, 546  
pleximeter, 518  
plexor, 518  
precordium, 560  
presbyopia, 533  
proprioceptors, 581  
pyorrhea, 546  
quality, 519  
reflex, 581  
resonance, 519  
resting tremor, 577  
S<sub>1</sub>, 561  
S<sub>2</sub>, 561  
semicircular canals, 540  
sensorineural hearing loss, 540  
sordes, 546  
stapes, 540  
stereognosis, 582  
sternum, 554  
strabismus, 536  
systole, 561  
tartar, 546  
thrill, 562  
tragus, 539  
tremor, 577  
triangular fossa, 539  
two-point discrimination, 582  
tympanic membrane, 539  
tympany, 519  
vestibule, 540  
visual acuity, 533  
visual fields, 533  
vitiligo, 523

## INTRODUCTION

Assessing a client's health status is a major component of nursing care and has two aspects: (1) the nursing health history discussed in Chapter 11 ∞ and (2) the physical examination discussed in this chapter. A physical examination can be any of three types: (1) a complete assessment (e.g., when a client is admitted to a health care agency), (2) examination of a body system (e.g., the cardiovascular system), or (3) examination of a body area (e.g., the lungs, when difficulty with breathing is observed). *Note:* Some nurses consider *assessment* to be the broad term used in applying the nursing process to health data and *examination* to be the physical process used to gather the data. In this text, the terms *assessment* and *examination* are sometimes used interchangeably—both referring to a critical investigation and evaluation of client status.

## PHYSICAL HEALTH ASSESSMENT

A complete health assessment may be conducted starting at the head and proceeding in a systematic manner downward (head-to-toe assessment). However, the procedure can vary according to the age of the individual, the severity of the illness, the preferences of the nurse,

the location of the examination, and the agency's priorities and procedures. The order of head-to-toe assessment is given in Box 30–1. Regardless of the procedure used, the client's energy and time need to be considered. The health assessment is therefore conducted in a systematic and efficient manner that results in the fewest position changes for the client.

Frequently, nurses assess a specific body area instead of the entire body. These specific assessments are made in relation to client complaints, the nurse's own observation of problems, the client's presenting problem, nursing interventions provided, and medical therapies. Examples of these situations and assessments are provided in Table 30–1.

These are some of the purposes of the physical examination:

- To obtain baseline data about the client's functional abilities.
- To supplement, confirm, or refute data obtained in the nursing history.
- To obtain data that will help establish nursing diagnoses and plans of care.
- To evaluate the physiological outcomes of health care and thus the progress of a client's health problem.
- To make clinical judgments about a client's health status.
- To identify areas for health promotion and disease prevention.

### BOX 30–1 Head-to-Toe Framework

- |                                                                                                                                                                                                                                                                                                                                                                                                                                                                                                                                                                                                                                                                                                                                                                      |                                                                                                                                                                                                                                                                                                                                                                                                                                                                                                                                                                                                                                                                                                                      |
|----------------------------------------------------------------------------------------------------------------------------------------------------------------------------------------------------------------------------------------------------------------------------------------------------------------------------------------------------------------------------------------------------------------------------------------------------------------------------------------------------------------------------------------------------------------------------------------------------------------------------------------------------------------------------------------------------------------------------------------------------------------------|----------------------------------------------------------------------------------------------------------------------------------------------------------------------------------------------------------------------------------------------------------------------------------------------------------------------------------------------------------------------------------------------------------------------------------------------------------------------------------------------------------------------------------------------------------------------------------------------------------------------------------------------------------------------------------------------------------------------|
| <ul style="list-style-type: none"> <li>• General survey</li> <li>• Vital signs</li> <li>• Head               <ul style="list-style-type: none"> <li>• Hair, scalp, face</li> <li>• Eyes and vision</li> <li>• Ears and hearing</li> <li>• Nose</li> <li>• Mouth and oropharynx</li> </ul> </li> <li>• Neck               <ul style="list-style-type: none"> <li>• Muscles</li> <li>• Lymph nodes</li> <li>• Trachea</li> <li>• Thyroid gland</li> <li>• Carotid arteries</li> <li>• Neck veins</li> </ul> </li> <li>• Upper extremities               <ul style="list-style-type: none"> <li>• Skin and nails</li> <li>• Muscle strength and tone</li> <li>• Joint range of motion</li> <li>• Brachial and radial pulses</li> <li>• Sensation</li> </ul> </li> </ul> | <ul style="list-style-type: none"> <li>• Chest and back               <ul style="list-style-type: none"> <li>• Skin</li> <li>• Thorax shape and size</li> <li>• Lungs</li> <li>• Heart</li> <li>• Spinal column</li> <li>• Breasts and axillae</li> </ul> </li> <li>• Abdomen               <ul style="list-style-type: none"> <li>• Skin</li> <li>• Abdominal sounds</li> <li>• Femoral pulses</li> </ul> </li> <li>• External genitals</li> <li>• Anus</li> <li>• Lower extremities               <ul style="list-style-type: none"> <li>• Skin and toenails</li> <li>• Gait and balance</li> <li>• Joint range of motion</li> <li>• Popliteal, posterior tibial, and dorsalis pedis pulses</li> </ul> </li> </ul> |
|----------------------------------------------------------------------------------------------------------------------------------------------------------------------------------------------------------------------------------------------------------------------------------------------------------------------------------------------------------------------------------------------------------------------------------------------------------------------------------------------------------------------------------------------------------------------------------------------------------------------------------------------------------------------------------------------------------------------------------------------------------------------|----------------------------------------------------------------------------------------------------------------------------------------------------------------------------------------------------------------------------------------------------------------------------------------------------------------------------------------------------------------------------------------------------------------------------------------------------------------------------------------------------------------------------------------------------------------------------------------------------------------------------------------------------------------------------------------------------------------------|

TABLE 30–1 Nursing Assessments Addressing Selected Client Situations

| Situation                                                        | Physical Assessment                                                                                                                                                        |
|------------------------------------------------------------------|----------------------------------------------------------------------------------------------------------------------------------------------------------------------------|
| Client complains of abdominal pain.                              | Inspect, auscultate, percuss, and palpate the abdomen; assess vital signs.                                                                                                 |
| Client is admitted with a head injury.                           | Assess level of consciousness using Glasgow Coma Scale (see Table 30–10 later in this chapter); assess pupils for reaction to light and accommodation; assess vital signs. |
| The nurse prepares to administer a cardiotonic drug to a client. | Assess apical pulse and compare with baseline data.                                                                                                                        |
| The client has just had a cast applied to the lower leg.         | Assess peripheral perfusion of toes, capillary blanch test, pedal pulse if able, and vital signs.                                                                          |
| The client's fluid intake is minimal.                            | Assess tissue turgor, fluid intake and output, and vital signs.                                                                                                            |

**BOX 30–2 Cancer Screening Guidelines for Asymptomatic People****COLORECTAL CANCER (MALES AND FEMALES)**

- Fecal occult blood test or fecal immunochemical test annually beginning at age 50 **or**
- Stool DNA test may be done beginning at age 50.
- Flexible sigmoidoscopy every 5 years beginning at age 50 **or**
- Colonoscopy every 10 years beginning at age 50 **or**
- Double contrast barium enema every 5 years beginning at age 50.
- Computerized tomography colonography every 5 years beginning at age 50.

**BREAST CANCER (FEMALES)**

- Beginning in their early 20s, women should be told about the benefits and limitations of breast self-examination (BSE) and the importance of reporting breast symptoms to a health professional. Those who choose to perform BSE should receive instruction and have their technique reviewed regularly. Women may choose to perform BSE regularly, occasionally, or not at all.
- Clinical breast examination every 3 years from ages 20 to 40, and then annually beginning at age 40.
- Mammogram annually at age 40 and over.

**CERVICAL AND UTERINE CANCER (FEMALES)**

- For women ages 21 to 29, screening every 3 years with Pap tests.
- For women ages 30 to 65, screening every 5 years with both HPV test and the Pap test, or every 3 years with the Pap test alone.
- Women ages 65 and older who have had  $\geq 3$  consecutive negative Pap tests or  $\geq 2$  consecutive negative HPV and Pap tests in the last 10 years, the most recent test in the last 5 years, and women who have had a total hysterectomy should stop cervical cancer screening.

**PROSTATE CANCER (MALES)**

- For men who have at least a 10-year life expectancy, discussion with the primary care provider about the benefits, risks, and uncertainties associated with prostate cancer screening.

**HEALTH COUNSELING AND CANCER CHECKUP (MALES AND FEMALES) OVER AGE 20**

- Examination for cancers of the thyroid, testicles, ovaries, lymph nodes, oral region, and skin during the regular health examination

From "Cancer Screening in the United States, 2014: A Review of Current American Cancer Society Guidelines and Current Issues in Cancer Screening" by R. A. Smith, D. Manassaram-Baptiste, D. Brooks, V. Cokkinides, M. Doroshenko, D. Saslow, . . . O. W. Brawley, 2014, *CA: A Cancer Journal for Clinicians*, 64, pp. 31–51.

Nurses use national guidelines and evidence-based practice to focus health assessment on specific conditions. The nurse's judgment is key when the evidence is inconclusive or conflicting. For example, when screening for cancer, nurses should keep in mind the American Cancer Society's guidelines for early detection (Box 30–2). However, whereas those guidelines call for mammography every year beginning at age 40, the U.S. Preventive Services Task Force (2009) recommends breast mammography only every 2 years for women ages 50 to 74 and none thereafter.

**Preparing the Client**

Most people need an explanation of the physical examination. Often clients are anxious about what the nurse will find. They can be reassured during the examination by explanations at each step. The nurse should explain when and where the examination will take place, why it is important, and what will happen. Instruct the client that all information gathered and documented during the assessment is kept confidential in accordance with the Health Insurance Portability and Accountability Act (HIPAA). This means that only those health care providers who have a legitimate need to know the client's information will have access to it.

Health examinations are usually painless; however, it is important to determine in advance any positions that are contraindicated for a particular client. The nurse assists the client as needed to undress and put on a gown. Clients should empty their bladders before the examination. Doing so helps them feel more relaxed and facilitates palpation of the abdomen and pubic area. If a urinalysis is required, the urine should be collected in a container for that purpose.

When assessing adults it is important to recognize that people of the same age differ markedly. Box 30–3 provides special considerations for assessing adults, especially older adults.

The sequence of the assessment differs with children and adults. With children, always proceed from the least invasive or uncomfortable aspect of the exam to the more invasive. Examination of the head

**BOX 30–3 Health Assessment of the Adult**

- Be aware of normal physiological changes that occur with aging (see the Lifespan Considerations later in this chapter).
- Be aware of stiffness of muscles and joints from aging or history of orthopedic surgery. The client may need modification of the usual positioning necessary for examination and assessment.
- Expose only areas of the body to be examined in order to avoid chilling.
- Permit ample time for the client to answer your questions and assume the required positions.
- Be aware of cultural differences. The client may want a family member present during disrobing.
- Arrange for an interpreter if the client's language differs from that of the nurse.
- Ask clients how they wish to be addressed, such as "Mrs." or "Miss."
- Adapt assessment techniques to any sensory impairment; for example, make sure eyeglasses or hearing aids are nearby.
- If clients are older or frail, it is wise to conduct the assessment in several segments in order to not overtire them.

and neck, heart and lungs, and range of motion can be done early in the process, with the ears, mouth, abdomen, and genitals being left for the end of the exam.

**Preparing the Environment**

It is important to prepare the environment before starting the assessment. The time for the physical assessment should be convenient to both the client and the nurse. The environment needs to be well lighted and the equipment should be organized for efficient use. A client who is physically relaxed will usually experience little discomfort. The room should be warm enough to be comfortable for the client.

Providing privacy is important. Most people are embarrassed if their bodies are exposed or if others can overhear or view them during the assessment. Culture, age, and gender of both the client and the

nurse influence how comfortable the client will be and what special arrangements might be needed. For example, if the client and nurse are of different genders, the nurse should ask if it is acceptable to perform the physical examination. Family and friends should not be present unless the client asks for someone.

## Positioning

Several positions are frequently required during the physical assessment. It is important to consider the client's ability to assume a position. The client's physical condition, energy level, and age should also be taken into consideration. Some positions are embarrassing and uncomfortable and therefore should not be maintained for long. The assessment is organized so that several body areas can be assessed in one position, thus minimizing the number of position changes needed (Table 30–2).

## Draping

Drapes should be arranged so that the area to be assessed is exposed and other body areas are covered. Exposure of the body is frequently embarrassing to clients. Drapes provide not only a degree of privacy but also warmth. Drapes are made of paper, cloth, or bed linen.

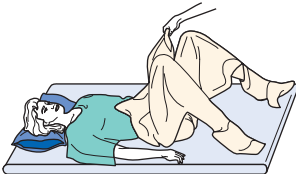

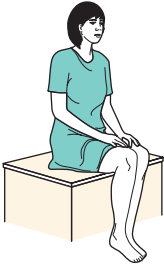
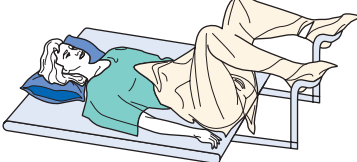
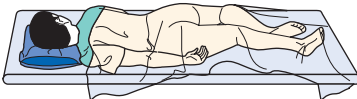
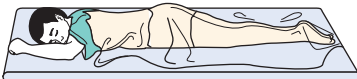
## Instrumentation

All equipment required for the health assessment should be clean, in good working order, and readily accessible. Equipment is frequently set up on trays, ready for use. Various instruments are shown in Table 30–3.









## Methods of Examining

Four primary techniques are used in the physical examination: inspection, palpation, percussion, and auscultation. These techniques

**TABLE 30–2** Client Positions and Body Areas Assessed

| Position                                                                                                             | Description                                                                                                                          | Areas Assessed                                                                                                                | Cautions                                                                                     |
|----------------------------------------------------------------------------------------------------------------------|--------------------------------------------------------------------------------------------------------------------------------------|-------------------------------------------------------------------------------------------------------------------------------|----------------------------------------------------------------------------------------------|
| Dorsal recumbent<br>               | Back-lying position with knees flexed and hips externally rotated; small pillow under the head; soles of feet on the surface         | Female genitals, rectum, and female reproductive tract                                                                        | May be contraindicated for clients who have cardiopulmonary problems.                        |
| Supine (horizontal recumbent)<br> | Back-lying position with legs extended; with or without pillow under the head                                                        | Head, neck, axillae, anterior thorax, lungs, breasts, heart, vital signs, abdomen, extremities, peripheral pulses             | Tolerated poorly by clients with cardiovascular and respiratory problems.                    |
| Sitting<br>                       | A seated position, back unsupported and legs hanging freely                                                                          | Head, neck, posterior and anterior thorax, lungs, breasts, axillae, heart, vital signs, upper and lower extremities, reflexes | Older adults and weak clients may require support.                                           |
| Lithotomy<br>                     | Back-lying position with feet supported in stirrups; the hips should be in line with the edge of the table                           | Female genitals, rectum, and female reproductive tract                                                                        | May be uncomfortable and tiring for older adults and often embarrassing.                     |
| Sims'<br>                         | Side-lying position with lowermost arm behind the body, uppermost leg flexed at hip and knee, upper arm flexed at shoulder and elbow | Rectum, vagina                                                                                                                | Difficult for older adults and people with limited joint movement.                           |
| Prone<br>                         | Lies on abdomen with head turned to the side, with or without a small pillow                                                         | Posterior thorax, hip joint movement                                                                                          | Often not tolerated by older adults and people with cardiovascular and respiratory problems. |

**TABLE 30–3** Equipment and Supplies Used for a Health Examination

| Supplies                   |                                                                                     | Purpose                                                                                                                                                    |
|----------------------------|-------------------------------------------------------------------------------------|------------------------------------------------------------------------------------------------------------------------------------------------------------|
| Flashlight or penlight     |    | To assist viewing of the pharynx or to determine the reactions of the pupils of the eye                                                                    |
| Ophthalmoscope             |    | A lighted instrument to visualize the interior of the eye                                                                                                  |
| Otoscope                   |    | A lighted instrument to visualize the eardrum and external auditory canal (a nasal speculum may be attached to the otoscope to inspect the nasal cavities) |
| Percussion (reflex) hammer |    | An instrument with a rubber head to test reflexes                                                                                                          |
| Tuning fork                |    | A two-pronged metal instrument used to test hearing acuity and vibratory sense                                                                             |
| Cotton applicators         |    | To obtain specimens                                                                                                                                        |
| Gloves                     |    | To protect the nurse                                                                                                                                       |
| Tongue blades (depressors) |  | To depress the tongue during assessment of the mouth and pharynx                                                                                           |

are discussed throughout this chapter as they apply to each body system.

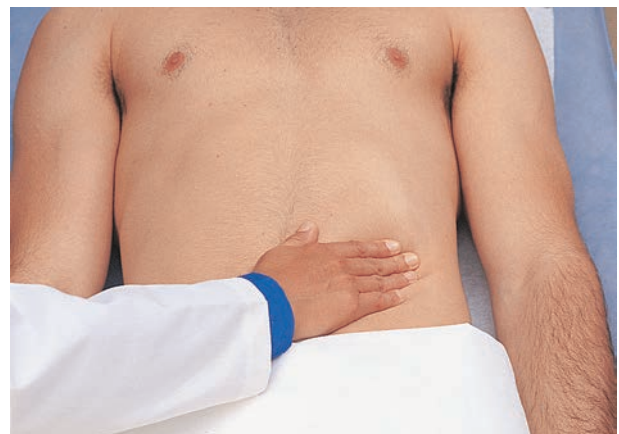## INSPECTION

**Inspection** is the visual examination, which is assessing by using the sense of sight. It should be deliberate, purposeful, and systematic. The nurse inspects with the naked eye and with a lighted instrument such as an otoscope (used to view the ear). In addition to visual observations, olfactory (smell) and auditory (hearing) cues are noted. Nurses frequently use visual inspection to assess moisture, color, and texture of body surfaces, as well as shape, position, size, color, and symmetry of the body. Lighting must be sufficient for the nurse to see clearly; either natural or artificial light can be used. When using the auditory senses, it is important to have a quiet environment for accurate hearing. Inspection can be combined with the other assessment techniques.

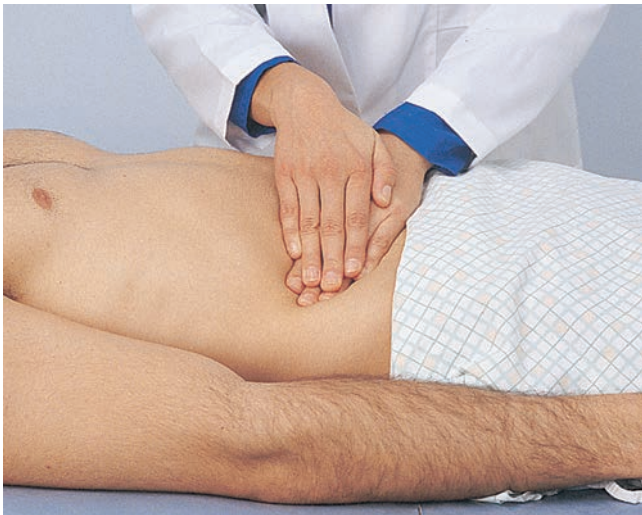## PALPATION

**Palpation** is the examination of the body using the sense of touch. The pads of the fingers are used because their concentration of nerve endings makes them highly sensitive to tactile discrimination. Palpation is used to determine (a) texture (e.g., of the hair); (b) temperature (e.g., of a skin area); (c) vibration (e.g., of a joint); (d) position, size, consistency, and mobility of organs or masses; (e) distention (e.g., of the urinary bladder); (f) pulsation; and (g) tenderness or pain.

There are two types of palpation: light and deep. *Light* (superficial) *palpation* should always precede *deep palpation* because heavy pressure on the fingertips can dull the sense of touch. For light palpation, the nurse extends the dominant hand's fingers parallel to the skin surface and presses gently while moving the hand in a circle (Figure 30–1 ■). With light palpation, the skin is slightly depressed. If it is necessary to determine the details of a mass, the nurse presses lightly several times rather than holding the pressure. See Box 30–4 for the characteristics of masses.



**Figure 30–1** ■ The position of the hand for light palpation.



**Figure 30-2** ■ The position of the hands for deep bimanual palpation.

#### BOX 30-4 Characteristics of Masses

*Location*—site on the body, dorsal/ventral surface  
*Size*—length and width in centimeters  
*Shape*—oval, round, elongated, irregular  
*Consistency*—soft, firm, hard  
*Surface*—smooth, nodular  
*Mobility*—fixed, mobile  
*Pulsatility*—present or absent  
*Tenderness*—degree of tenderness to palpation

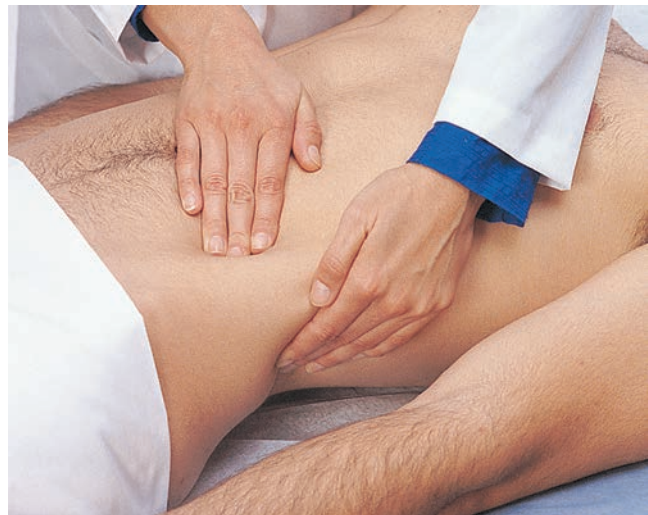*Deep palpation is usually not done during a routine examination and requires significant practitioner skill. It is performed with extreme caution because pressure can damage internal organs. It is usually not indicated in clients who have acute abdominal pain or pain that is not yet diagnosed.*

Deep palpation is done with two hands (bimanually) or one hand. In deep bimanual palpation, the nurse extends the dominant hand as for light palpation, then places the finger pads of the nondominant hand on the dorsal surface of the distal interphalangeal joint of the middle three fingers of the dominant hand (Figure 30-2 ■). The top hand applies pressure while the lower hand remains relaxed to perceive the tactile sensations. For deep palpation using one hand, the finger pads of the dominant hand press over the area to be palpated. Often the other hand is used to support from below (Figure 30-3 ■).

To test skin temperature, it is best to use the dorsum (back) of the hand and fingers, where the examiner's skin is thinnest. To test for vibration, the nurse should use the palmar surface of the hand. General guidelines for palpation include the following:

- The nurse's hands should be clean and warm, and the fingernails short.
- Areas of tenderness should be palpated last.
- Deep palpation should be done after superficial palpation.

The effectiveness of palpation depends largely on the client's relaxation. Nurses can assist a client to relax by (a) gowning and/or draping the client appropriately, (b) positioning the client comfortably, and (c) ensuring that their own hands are warm before beginning. During palpation, the nurse should be sensitive to the client's verbal and facial expressions indicating discomfort.



**Figure 30-3** ■ Deep palpation using the lower hand to support the body while the upper hand palpates the organ.

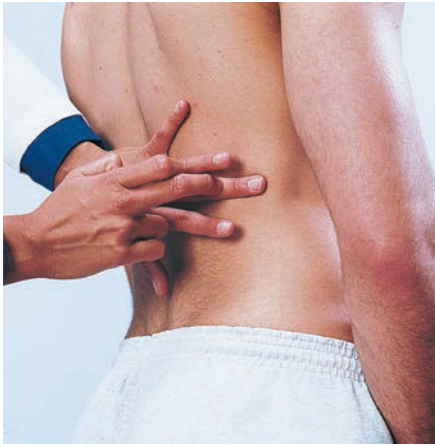## PERCUSSION

**Percussion** is the act of striking the body surface to elicit sounds that can be heard or vibrations that can be felt. There are two types of percussion: direct and indirect. In *direct percussion*, the nurse strikes the area to be percussed directly with the pads of two, three, or four fingers or with the pad of the middle finger. The strikes are rapid, and the movement is from the wrist. This technique is not generally used to percuss the thorax but is useful in percussing an adult's sinuses (Figure 30-4 ■).

*Indirect percussion* is the striking of an object (e.g., a finger) held against the body area to be examined. In this technique, the middle finger of the nondominant hand, referred to as the **pleximeter**, is placed firmly on the client's skin. Only the distal phalanx and joint of this finger should be in contact with the skin. Using the tip of the flexed middle finger of the other hand, called the **plexor**, the nurse strikes the pleximeter, usually at the distal interphalangeal joint or a point between the distal and proximal joints (Figure 30-5 ■). The striking motion comes from the wrist; the forearm remains



**Figure 30-4** ■ Direct percussion. Using one hand to strike the surface of the body.



**Figure 30-5** ■ Indirect percussion. Using the finger of one hand to tap the finger of the other hand.

stationary. The angle between the plexor and the pleximeter should be 90°, and the blows must be firm, rapid, and short to obtain a clear sound.

Percussion is used to determine the size and shape of internal organs by establishing their borders. It indicates whether tissue is fluid filled, air filled, or solid. Percussion elicits five types of sound: flatness, dullness, resonance, hyperresonance, and tympany. **Flatness** is an extremely dull sound produced by very dense tissue, such as muscle or bone. **Dullness** is a thudlike sound produced by dense tissue such as the liver, spleen, or heart. **Resonance** is a hollow sound such as that produced by lungs filled with air. **Hyperresonance** is not produced in the normal body. It is described as booming and can be heard over an emphysematous lung. **Tympany** is a musical or drumlike sound produced from an air-filled stomach. On a continuum, flatness reflects the most dense tissue (the least amount of air) and tympany the least dense tissue (the greatest amount of air). A percussion sound is described according to its intensity, pitch, duration, and quality (Table 30-4).

## AUSCULTATION

**Auscultation** is the process of listening to sounds produced within the body. Auscultation may be direct or indirect. *Direct auscultation* is performed using the unaided ear, for example, to listen to a respiratory wheeze or the grating of a moving joint. *Indirect auscultation* is performed using a stethoscope, which transmits sounds to the nurse's ears. A stethoscope is used primarily to listen to sounds from within the body, such as bowel sounds or valve sounds of the heart and blood pressure.

The stethoscope tubing should be 30 to 35 cm (12 to 14 in.) long, with an internal diameter of about 0.3 cm (1/8 in.). It should have both a flat-disk diaphragm and a bell-shaped amplifier (see Figure 4 in Skill 29-3 on page 493). The diaphragm best transmits high-pitched sounds (e.g., bronchial sounds), and the bell best transmits low-pitched sounds such as some heart sounds. The earpieces of the stethoscope should fit comfortably into the nurse's ears, facing forward. The amplifier of the stethoscope is placed firmly but lightly against the client's skin. If the client has excessive hair, it may be necessary to dampen the hairs with a moist cloth so that they will lie flat against the skin and not interfere with clear sound transmission.

Auscultated sounds are described according to their pitch, intensity, duration, and quality. The **pitch** is the frequency of the vibrations (the number of vibrations per second). Low-pitched sounds, such as some heart sounds, have fewer vibrations per second than high-pitched sounds, such as bronchial sounds. The **intensity** (amplitude) refers to the loudness or softness of a sound. Some body sounds are loud, for example, bronchial sounds heard from the trachea; others are soft, for example, normal breath sounds heard in the lungs. The **duration** of a sound is its length (long or short). The **quality** of sound is a subjective description of a sound, for example, whistling, gurgling, or snapping.

## GENERAL SURVEY

Health assessment begins with a general survey that involves observation of the client's general appearance, level of comfort, and mental status, and measurement of vital signs, height, and weight. Many components of the general survey are assessed while taking the client's health history, such as the client's body build, posture, hygiene, and mental status (see Chapter 11 ∞).

## Appearance and Mental Status

The general appearance and behavior of an individual must be assessed in relationship to culture, educational level, socioeconomic status, and current circumstances. For example, an individual who has recently experienced a personal loss may appropriately appear depressed (sad expression, slumped posture). The client's age, sex, and race are also useful factors in interpreting findings that suggest increased risk for known conditions. Skill 30-1 describes how to assess general appearance and mental status. Skill 30-17 later in this chapter describes a mental status examination in detail.

**TABLE 30-4** Percussion Sounds and Tones

| Sound          | Intensity | Pitch                                         | Duration  | Quality        | Example of Location           |
|----------------|-----------|-----------------------------------------------|-----------|----------------|-------------------------------|
| Flatness       | Soft      | High                                          | Short     | Extremely dull | Muscle, bone                  |
| Dullness       | Medium    | Medium                                        | Moderate  | Thudlike       | Liver, heart                  |
| Resonance      | Loud      | Low                                           | Long      | Hollow         | Normal lung                   |
| Hyperresonance | Very loud | Very low                                      | Very long | Booming        | Emphysematous lung            |
| Tympany        | Loud      | High (distinguished mainly by musical timbre) | Moderate  | Musical        | Stomach filled with gas (air) |

## Assessing Appearance and Mental Status

### PLANNING

#### DELEGATION

Due to the substantial knowledge and skill required, assessment of general appearance and mental status is not delegated to unlicensed assistive personnel (UAP). However, many aspects are observed during usual care and may be recorded by individuals other than the nurse. Abnormal findings must be validated and interpreted by the nurse.

#### Equipment

None

### IMPLEMENTATION

#### Performance

1. Prior to performing the procedure, introduce self and verify the client's identity using agency protocol. Explain to the client what you are going to do, why it is necessary, and how he or she can participate. Discuss how the results will be used in planning further care or treatments.
2. Perform hand hygiene and observe other appropriate infection prevention procedures.
3. Provide for client privacy.

| Assessment                                                                                                                                      | Normal Findings                                                              | Deviations from Normal                                                          |
|-------------------------------------------------------------------------------------------------------------------------------------------------|------------------------------------------------------------------------------|---------------------------------------------------------------------------------|
| 4. Observe for signs of distress in posture or facial expression.                                                                               | No distress noted                                                            | Bending over because of abdominal pain, wincing, frowning, or labored breathing |
| 5. Observe body build, height, and weight in relation to the client's age, lifestyle, and health.                                               | Proportionate, varies with lifestyle                                         | Excessively thin or obese                                                       |
| 6. Observe client's posture and gait, standing, sitting, and walking.                                                                           | Relaxed, erect posture; coordinated movement                                 | Tense, slouched, bent posture; uncoordinated movement; tremors, unbalanced gait |
| 7. Observe client's overall hygiene and grooming.                                                                                               | Clean, neat                                                                  | Dirty, unkempt                                                                  |
| 8. Note body and breath odor.                                                                                                                   | No body odor or minor body odor relative to work or exercise; no breath odor | Foul body odor; ammonia odor; acetone breath odor; foul breath                  |
| 9. Note obvious signs of health or illness (e.g., in skin color or breathing).                                                                  | Well developed, well nourished, intact skin, easy breathing                  | Pallor (paleness); weakness; lesions, cough                                     |
| 10. Assess the client's attitude (frame of mind).                                                                                               | Cooperative, able to follow instructions                                     | Negative, hostile, withdrawn, anxious                                           |
| 11. Note the client's affect/mood; assess the appropriateness of the client's responses.                                                        | Appropriate to situation                                                     | Inappropriate to situation, sudden mood change, paranoia                        |
| 12. Listen for quantity of speech (amount and pace), quality (loudness, clarity, inflection).                                                   | Understandable, moderate pace; clear tone and inflection                     | Rapid or slow pace; overly loud or soft                                         |
| 13. Listen for relevance and organization of thoughts.                                                                                          | Logical sequence; makes sense; has sense of reality                          | Illogical sequence; flight of ideas; confusion; generalizations; vague          |
| 14. Document findings in the client record using printed or electronic forms and checklists supplemented by narrative notes when appropriate. 1 |                                                                              |                                                                                 |

### EVALUATION

- Perform a detailed follow-up examination of specific systems based on findings that deviated from expected or normal for the client. Relate findings to previous assessment data if available.
- Report significant deviations from expected or normal findings to the primary care provider.

### INTERPROFESSIONAL PRACTICE

Assessing appearance and mental status is within the scope of practice of many health care providers other than nurses before, during, and after their treatments. Although these providers may verbally communicate their findings and plan to other health care team members, the nurse must also know where to locate their documentation in the client's medical record.



Assessing Appearance and Mental Status—continued

SKILL 30-1

Adult Admission Assessment - Sweda, Katherine

Performed on: 08/21/2014 0655 CDT By: Border, Cathy

**Subjective**

Assess symptoms relative to any new medications administered for the first time. Evaluate the need to notify the physician for dosage adjustments, discontinuation of the medication, or other interventions.

**Pain Present**

Unable to assess  
 No actual or suspected pain  
 Yes actual or suspected pain

**General Symptoms**

Activity intolerance     Edema     Nausea  
 Anorexia     Faintness     Weakness  
 Confusion/Disorientation     Fatigue     Other:  
 Dizziness     Heartburn  
 Drooling     Itching

Documentation of Activity Intolerance, Confusion/Disorientation, Dizziness, Faintness or Weakness will create an order for Morse Fall Risk Assessment if not done within the last 24 hours

**Activity Tolerance**

Dyspnea/Fatigue at levels limiting normal person     Dyspnea/Fatigue at rest  
 Dyspnea/Fatigue with ordinary activity  
 Dyspnea/Fatigue with less than ordinary activity

**Respiratory Symptoms**

Cough     Other:  
 Denies shortness of breath at rest  
 Denies shortness of breath with usual activity  
 Drooling  
 Shortness of breath

Any of the above symptoms may indicate a problem of Activity Intolerance

**Cardiovascular Symptoms**

Chest pain/pressure at rest     Dizziness     Fluid retention  
 Chest pain/pressure with activity     Edema     Palpitations  
 Claudication     Fatigue     Other:

Any of the above symptoms may indicate a problem of Activity Intolerance

**Gastrointestinal Symptoms**

Abdominal tenderness     Constipation     Flatulence     Impaction     Stools, black/bloody     Other:  
 Anorexia     Cramping     Heartburn     Incontinence     Vomiting

In Progress

1 Nursing assessment form.

"Nursing Assessment Form" from Cerner Electronic Health Record. Copyright © by Cerner Corporation. Used by permission of Cerner Corporation.

## Vital Signs

Vital signs are measured (a) to establish baseline data against which to compare future measurements and (b) to detect actual and potential health problems. See Chapter 29 ∞ for measurements of temperature, pulse, respirations, blood pressure, and oxygen saturation. See Chapter 46 ∞ for pain assessment.

## Height and Weight

In adults, the ratio of weight to height provides a general measure of health. By asking clients about their height and weight before actually measuring them, the nurse obtains some idea of the person's self-image. Excessive discrepancies between the client's responses and the measurements may provide clues to actual or potential problems in self-concept. Take note of any unintentional weight gain or loss lasting or progressing over several weeks.

The nurse measures height with a measuring stick attached to weight scales or to a wall. The client should remove the shoes and stand erect, with heels together, and the heels, buttocks, and back of the head against the measuring stick; eyes should be looking straight ahead. The nurse raises the L-shaped sliding arm until it rests on top of the client's head, or places a small flat object such as a ruler or book on the client's head. The edge of the flat object should abut the measuring guide.

Weight is usually measured when a client is admitted to a health care agency and then often regularly thereafter, for example, each morning before breakfast and after emptying the bladder. Scales measure in pounds (lb) or kilograms (kg), and the nurse may need to convert between the two systems. One kilogram is equal to 2.2 pounds. When accuracy is essential, the nurse should use the same scale each time (because every scale weighs slightly differently), take the measurements at the same time each day, and make sure the client has on a similar kind of clothing and no footwear. The weight is read from a digital display panel or a balancing arm. Clients who cannot stand are weighed on chair (Figure 30–6 ■) or bed scales. The bed scales (Figure 30–7 ■) have canvas straps or a stretcher-like apparatus to support the client. A machine lifts the client above the bed, and the weight is reflected either on a digital display panel or on a balance arm like that of a standing scale. Newer hospital beds have built-in scales.

### CLINICAL ALERT!

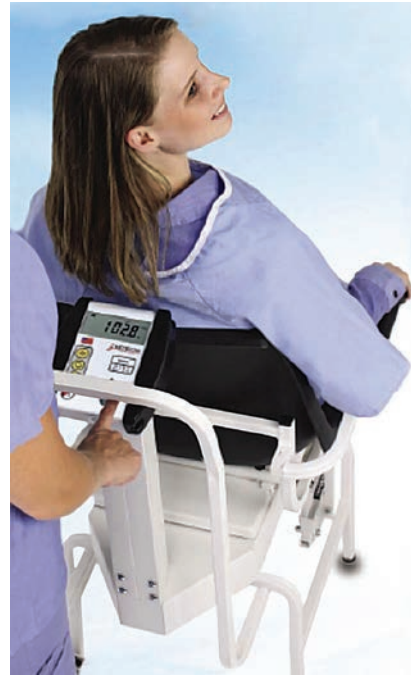Review the agency charting form before beginning your assessment to ensure that you know which data you will need to collect, have all the equipment you require, and know how to perform the assessment in a systematic manner.

## INTEGUMENT

The integument includes the skin, hair, and nails. The examination begins with a generalized inspection using a good source of lighting, preferably indirect natural daylight.

## Skin

Assessment of the skin involves inspection and palpation. The entire skin surface may be assessed at one time or as each aspect of the body



**Figure 30–6** ■ Chair scale.  
Courtesy DETECTO Scale.



**Figure 30–7** ■ Bed scale.

is assessed. In some instances, the nurse may also use the olfactory sense to detect unusual skin odors; these are usually most evident in the skinfolds or in the axillae. Pungent body odor is frequently related to poor hygiene, hyperhidrosis (excessive perspiration), or bromhidrosis (foul-smelling perspiration).

## LIFESPAN CONSIDERATIONS General Survey

### INFANTS

- Observation of children's behavior can provide important data for the general survey, including physical development, neuromuscular function, and social and interactional skills.
- It may be helpful to have parents hold older infants and very young children for part of the assessment.
- Measure height of children under age 2 in the supine position with knees fully extended.
- Weigh without clothing.
- Include measurement of head circumference until age 2. Standardized growth charts include head circumference up to age 3.

### CHILDREN

- Anxiety in preschool-age children can be decreased by letting them handle and become familiar with examination equipment.

- School-age children may be very modest and shy about exposing parts of the body.
- Adolescents should be examined without parents present.
- Weigh children without shoes and with as little clothing as possible.

### OLDER ADULTS

- Allow extra time for clients to answer questions.
- Adapt questioning techniques as appropriate for clients with hearing or visual limitations.
- Older adults can lose several inches in height. Be sure to document height and ask if they are aware of becoming shorter in height.
- When asking about weight loss, be specific about amount and time frame, for example, "Have you lost more than five pounds in the last two months?" "How much did you weigh one year ago?"

## Home Care Considerations General Survey

### PATIENT-CENTERED CARE

- Assess the client in private whenever possible. If a family member is needed to assist with recall of events or translation, obtain the client's permission to have the family member present.
- Use your own equipment when possible in measuring vital signs. Bring a tape measure for measuring height. Recognize that the client's home scale for measuring weight may not be accurate.

**Pallor** is the result of inadequate circulating blood or hemoglobin and subsequent reduction in tissue oxygenation. In clients with dark skin, it is usually characterized by the absence of underlying red tones in the skin and may be most readily seen in the buccal mucosa. In brown-skinned clients, pallor may appear as a yellowish brown tinge; in black-skinned clients, the skin may appear ashen gray. Pallor in all people is usually most evident in areas with the least pigmentation such as the conjunctiva, oral mucous membranes, nail beds, palms of the hand, and soles of the feet.

**Cyanosis** (a bluish tinge) is most evident in the nail beds, lips, and buccal mucosa. In dark-skinned clients, close inspection of the palpebral conjunctiva (the lining of the eyelids) and palms and soles may also show evidence of cyanosis. **Jaundice** (a yellowish tinge) may first be evident in the sclera of the eyes and then in the mucous membranes and the skin. Nurses should take care not to confuse jaundice with the normal yellow pigmentation in the sclera of a dark-skinned client. If jaundice is suspected, the posterior part of the hard palate should also be inspected for a yellowish color tone. **Erythema** is skin redness associated with a variety of rashes and other conditions.

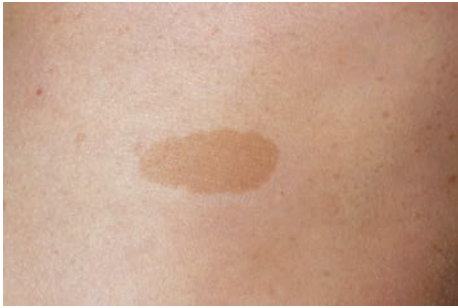Localized areas of hyperpigmentation (increased pigmentation) and hypopigmentation (decreased pigmentation) may occur as a result of changes in the distribution of melanin (the dark pigment) or in the function of the melanocytes in the epidermis. An example of hyperpigmentation in a defined area is a birthmark; an example of hypopigmentation is vitiligo. **Vitiligo**, seen as patches of

hypopigmented skin, is caused by the destruction of melanocytes in the area. Albinism is the complete or partial lack of melanin in the skin, hair, and eyes. Other localized color changes may indicate a problem such as edema or a localized infection. Dark-skinned clients normally have areas of lighter pigmentation, such as the palms, lips, and nail beds.

**Edema** is the presence of excess interstitial fluid. An area of edema appears swollen, shiny, and taut and tends to blanch the skin color or, if accompanied by inflammation, may redden the skin. Generalized edema is most often an indication of impaired venous circulation and in some cases reflects cardiac dysfunction or venous abnormalities.

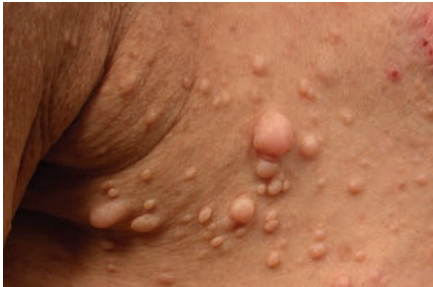A skin lesion is an alteration in a client's normal skin appearance. Primary skin lesions are those that appear initially in response to some change in the external or internal environment of the skin (Figure 30-8 ■, 1-3). Secondary skin lesions are those that do not appear initially but result from modifications such as chronicity, trauma, or infection of the primary lesion. For example, a vesicle or blister (primary lesion) may rupture and cause an erosion (secondary lesion). Table 30-5 illustrates secondary lesions. Nurses are responsible for describing skin lesions accurately in terms of location (e.g., face), distribution (i.e., body regions involved), and configuration (the arrangement or position of several lesions) as well as color, shape, size, firmness, texture, and characteristics of individual lesions. Skill 30-2 describes how to assess the skin.

**Macule, Patch** Flat, unelevated change in color. Macules are 1 mm to 1 cm (0.04 to 0.4 in.) in size and circumscribed. Examples: freckles, measles, petechiae, flat moles. Patches are larger than 1 cm (0.4 in.) and may have an irregular shape. Examples: port wine birthmark, vitiligo (white patches), rubella. **1**

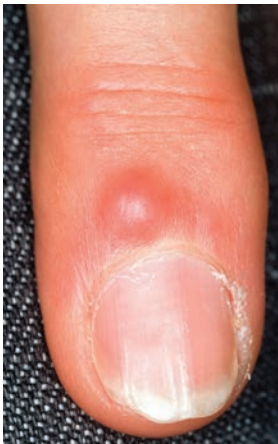

**1** A café-au-lait macule

**Nodule, Tumor** Elevated, solid, hard mass that extends deeper into the dermis than a papule. Nodules have a circumscribed border and are 0.5 to 2 cm (0.2 to 0.8 in.). Examples: squamous cell carcinoma, fibroma. Tumors are larger than 2 cm (0.8 in.) and may have an irregular border. Examples: malignant melanoma, hemangioma. **4**



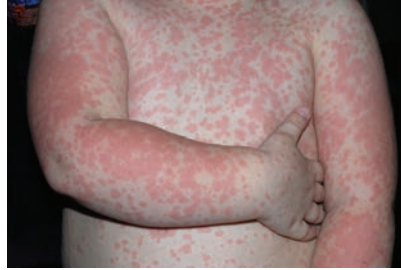**4** Nodules from Recklinghausen's Disease



**Cyst** A 1-cm (0.4 in.) or larger, elevated, encapsulated, fluid-filled or semisolid mass arising from the subcutaneous tissue or dermis. Examples: sebaceous and epidermoid cysts, chalazion of the eyelid. **7**

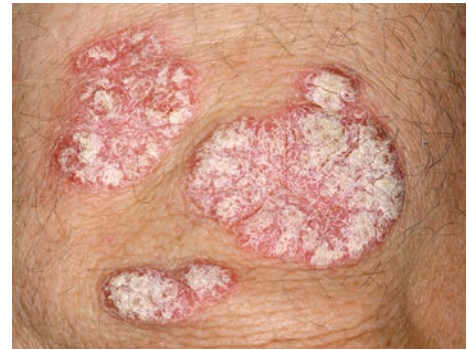**7** Digital mucous cyst

**Papule** Circumscribed, solid elevation of skin. Papules are less than 1 cm (0.4 in.). Examples: warts, acne, pimples, elevated moles. **2**



**2** Papular drug eruption

**Plaque** Plaques are larger than 1 cm (0.4 in.). Examples: psoriasis, rubeola. **3**

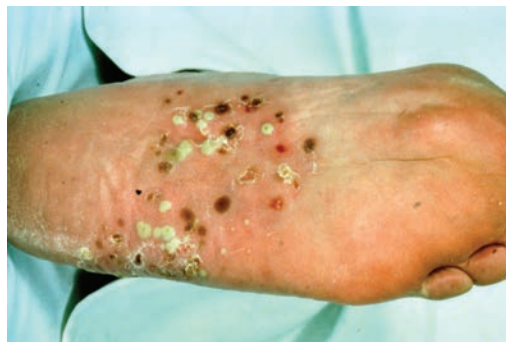

**3** Psoriasis

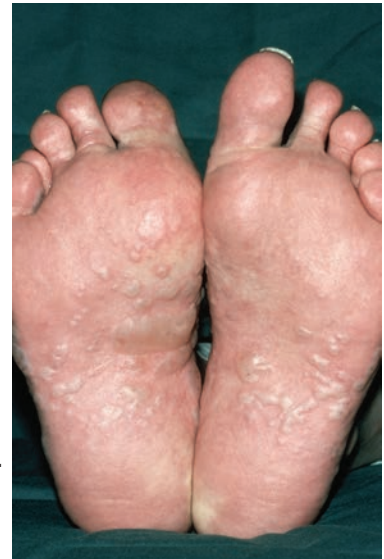**Vesicle, Bulla** A circumscribed, round or oval, thin translucent mass filled with serous fluid or blood.

Vesicles are less than 0.5 cm (0.2 in.). Examples: herpes simplex, early chicken pox, small burn blister. Bullae are larger than 0.5 cm (0.2 in.). Examples: large blister, second-degree burn, herpes simplex. **6**

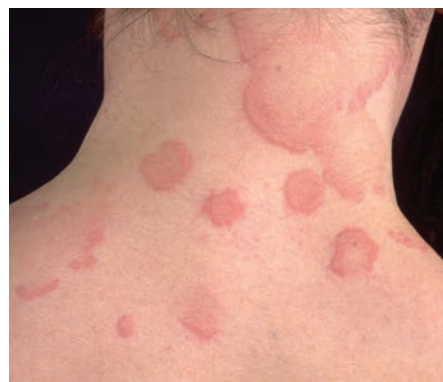**Pustule** Vesicle or bulla filled with pus. Examples: acne vulgaris, impetigo. **5**



**5** White pustules along with darker healing areas.



**6** Bullous pemphigoid



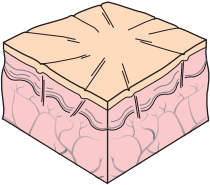
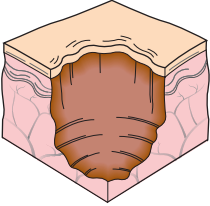
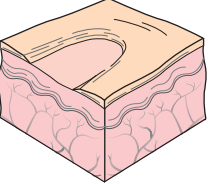
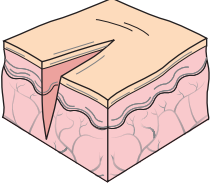
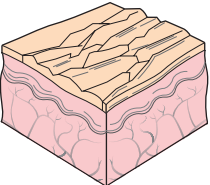
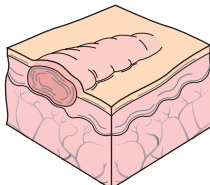
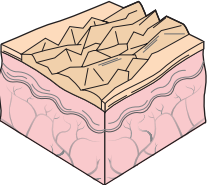
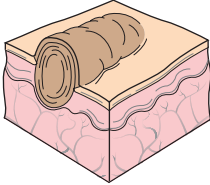
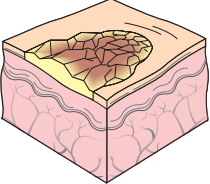
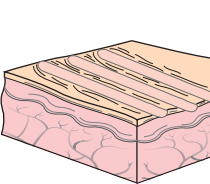
**Wheal** A reddened, localized collection of edema fluid; irregular in shape. Size varies. Examples: hives, mosquito bites. **8**

**8** Allergic wheals, urticaria

**Figure 30–8** ■ Primary skin lesions.

Figures **1** Dr. P. Marazzi/Science Source; **2** Scott Camazine/Alamy; **3** Mediscan/Alamy; **4** BSIP SA/Alamy; **5–6** Wellcome Image Library/Custom Medical Stock Photo; **7** Hercules Robinson/Alamy; **8** P. Marazzi/Photo Researchers/Science Source.

**TABLE 30–5 Secondary Skin Lesions**

|                                                                                     |                                                                                                                                                                                        |                                                                                      |                                                                                                                                                                                                                |
|-------------------------------------------------------------------------------------|----------------------------------------------------------------------------------------------------------------------------------------------------------------------------------------|--------------------------------------------------------------------------------------|----------------------------------------------------------------------------------------------------------------------------------------------------------------------------------------------------------------|
| <b>Atrophy</b>                                                                      | A translucent, dry, paper-like, sometimes wrinkled skin surface resulting from thinning or wasting of the skin due to loss of collagen and elastin.                                    | <b>Ulcer</b>                                                                         | Deep, irregularly shaped area of skin loss extending into the dermis or subcutaneous tissue. May bleed. May leave scar.                                                                                        |
|    | <b>Examples:</b> striae, aged skin                                                                                                                                                     |    | <b>Examples:</b> pressure ulcers, stasis ulcers, chancres                                                                                                                                                      |
| <b>Erosion</b>                                                                      | Wearing away of the superficial epidermis causing a moist, shallow depression. Because erosions do not extend into the dermis, they heal without scarring.                             | <b>Fissure</b>                                                                       | Linear crack with sharp edges, extending into the dermis.                                                                                                                                                      |
|    | <b>Examples:</b> scratch marks, ruptured vesicles                                                                                                                                      |    | <b>Examples:</b> cracks at the corners of the mouth or in the hands, athlete's foot                                                                                                                            |
| <b>Lichenification</b>                                                              | Rough, thickened, hardened area of epidermis resulting from chronic irritation such as scratching or rubbing.                                                                          | <b>Scar</b>                                                                          | Flat, irregular area of connective tissue left after a lesion or wound has healed. New scars may be red or purple; older scars may be silvery or white.                                                        |
|    | <b>Examples:</b> chronic dermatitis                                                                                                                                                    |    | <b>Examples:</b> healed surgical wound or injury, healed acne                                                                                                                                                  |
| <b>Scales</b>                                                                       | Shedding flakes of greasy, keratinized skin tissue. Color may be white, gray, or silver. Texture may vary from fine to thick.                                                          | <b>Keloid</b>                                                                        | Elevated, irregular, darkened area of excess scar tissue caused by excessive collagen formation during healing. Extends beyond the site of the original injury. Higher incidence in people of African descent. |
|   | <b>Examples:</b> dry skin, dandruff, psoriasis, and eczema                                                                                                                             |   | <b>Examples:</b> keloid from ear piercing or surgery                                                                                                                                                           |
| <b>Crust</b>                                                                        | Dry blood, serum, or pus left on the skin surface when vesicles or pustules burst. Can be red-brown, orange, or yellow. Large crusts that adhere to the skin surface are called scabs. | <b>Excoriation</b>                                                                   | Linear erosion.                                                                                                                                                                                                |
|  | <b>Examples:</b> eczema, impetigo, herpes, or scabs following abrasion                                                                                                                 |  | <b>Examples:</b> scratches, some chemical burns                                                                                                                                                                |

## Assessing the Skin

### PLANNING

- Review characteristics of primary and secondary skin lesions if necessary (see Figure 30–8 and Table 30–5).
- Ensure that adequate lighting is available.

### DELEGATION

Due to the substantial knowledge and skill required, assessment of the skin is not delegated to UAP. However, the skin is observed during usual care and UAPs should record their findings. Abnormal findings must be validated and interpreted by the nurse.

### Equipment

- Millimeter ruler
- Clean gloves
- Magnifying glass

### INTERPROFESSIONAL PRACTICE

Assessing the skin may be within the scope of practice of many health care providers other than nurses. For example, physical therapists and occupational therapists may notice edema or skin lesions during treatment. Although these other providers may verbally communicate their findings and plan to health care team members, the nurse must also know where to locate their documentation in the client's medical record.

## Assessing the Skin—continued

## IMPLEMENTATION

## Performance

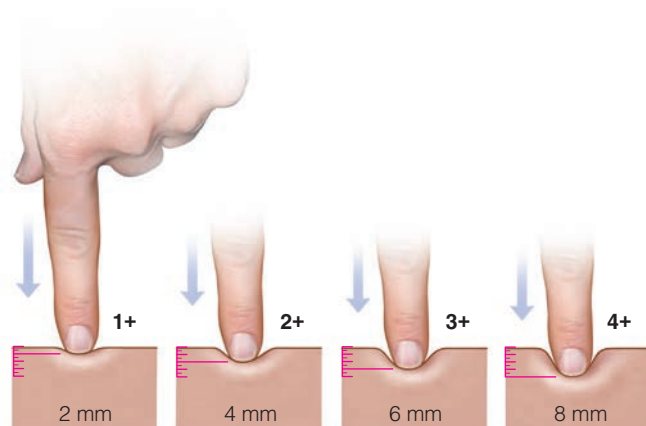
1. Prior to performing the procedure, introduce self and verify the client's identity using agency protocol. Explain to the client what you are going to do, why it is necessary, and how he or she can participate. Discuss how the results will be used in planning further care or treatments.
2. Perform hand hygiene and observe other appropriate infection prevention procedures.
3. Provide for client privacy.
4. Inquire if the client has any history of the following; pain or itching; presence and spread of lesions, bruises, abrasions, pigmented spots; previous experience with skin problems; associated clinical signs; family history; presence of problems in other family members; related systemic conditions; use of medications,

lotions, home remedies; excessively dry or moist feel to the skin; tendency to bruise easily; association of the problem to season of year, stress, occupation, medications, recent travel, housing, and so on; recent contact with allergens (e.g., metal paint).

## CLINICAL ALERT!

If you have not already gathered relevant information about the client's history as it relates to the specific area being assessed, do so before beginning the physical examination. This allows you to focus the examination, customized to the individual client history and current status.

| Assessment                                                                                                                                                                                                                                                                                                                                                                                              | Normal Findings                                                                                                                                                                                                   | Deviations from Normal                                                                                                                                                                                                                                                                                                                   |
|---------------------------------------------------------------------------------------------------------------------------------------------------------------------------------------------------------------------------------------------------------------------------------------------------------------------------------------------------------------------------------------------------------|-------------------------------------------------------------------------------------------------------------------------------------------------------------------------------------------------------------------|------------------------------------------------------------------------------------------------------------------------------------------------------------------------------------------------------------------------------------------------------------------------------------------------------------------------------------------|
| 5. Inspect skin color (best assessed under natural light and on areas not exposed to the sun).                                                                                                                                                                                                                                                                                                          | Varies from light to deep brown; from ruddy pink to light pink; from yellow overtones to olive                                                                                                                    | Pallor, cyanosis, jaundice, erythema                                                                                                                                                                                                                                                                                                     |
| 6. Inspect uniformity of skin color.                                                                                                                                                                                                                                                                                                                                                                    | Generally uniform except in areas exposed to the sun; areas of lighter pigmentation (palms, lips, nail beds) in dark-skinned people                                                                               | Areas of either hyperpigmentation or hypopigmentation                                                                                                                                                                                                                                                                                    |
| 7. Assess edema, if present (i.e., location, color, temperature, shape, and the degree to which the skin remains indented or pitted when pressed by a finger). Measuring the circumference of the extremity with a millimeter tape may be useful for future comparison.                                                                                                                                 | No edema                                                                                                                                                                                                          | See the scale for describing edema. ❶                                                                                                                                                                                                                                                                                                    |
| 8. Inspect, palpate, and describe skin lesions. Apply gloves if lesions are open or draining. Palpate lesions to determine shape and texture. Describe lesions according to location, distribution, color, configuration, size, shape, type, or structure (Box 30-5 on page 527). Use the millimeter ruler to measure lesions. If gloves were applied, remove and discard gloves. Perform hand hygiene. | Freckles, some birthmarks that have not changed since childhood, and some long-standing vascular birthmarks such as strawberry or port-wine hemangiomas, some flat and raised nevi; no abrasions or other lesions | Various interruptions in skin integrity; irregular, multicolored, or raised nevi, some pigmented birthmarks such as melanocytic nevi, and some vascular birthmarks such as cavernous hemangiomas. Even these deviations from normal may not be dangerous or require treatment. Assessment by an advanced-level practitioner is required. |
| 9. Observe and palpate skin moisture.                                                                                                                                                                                                                                                                                                                                                                   | Moisture in skinfolds and the axillae (varies with environmental temperature and humidity, body temperature, and activity)                                                                                        | Excessive moisture (e.g., in hyperthermia); excessive dryness (e.g., in dehydration)                                                                                                                                                                                                                                                     |



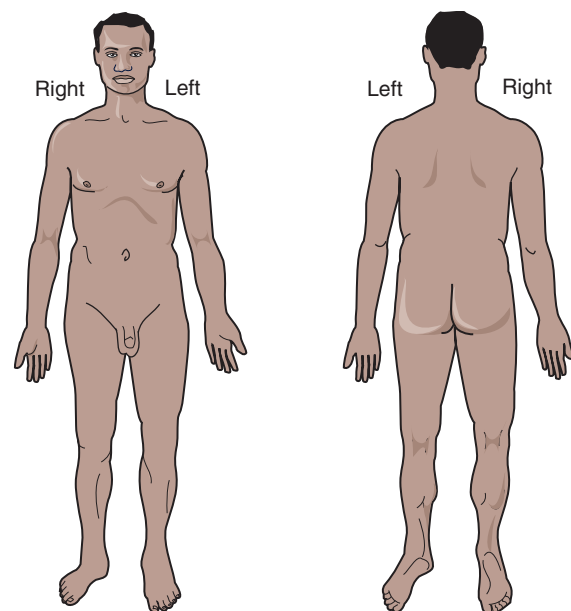
❶ Scale for grading edema.

## Assessing the Skin—continued

| Assessment                                                                                                                                                                                             | Normal Findings                                                                                | Deviations from Normal                                                                                                                                                                                                                                 |
|--------------------------------------------------------------------------------------------------------------------------------------------------------------------------------------------------------|------------------------------------------------------------------------------------------------|--------------------------------------------------------------------------------------------------------------------------------------------------------------------------------------------------------------------------------------------------------|
| 10. Palpate skin temperature. Compare the two feet and the two hands, using the backs of your fingers.                                                                                                 | Uniform; within normal range                                                                   | Generalized hyperthermia (e.g., in fever); generalized hypothermia (e.g., in shock); localized hyperthermia (e.g., in infection); localized hypothermia (e.g., in arteriosclerosis)                                                                    |
| 11. Note skin turgor (fullness or elasticity) by lifting and pinching the skin on an extremity or on the sternum.                                                                                      | When pinched, skin springs back to previous state (is elastic); may be slower in older adults. | Skin stays pinched or tented or moves back slowly (e.g., in dehydration). Count in seconds how long the skin remains tented. There is no widely accepted time span distinguishing normal from abnormal skin turgor (de Vries Feyens & de Jager, 2011). |
| 12. Remove and discard gloves. <ul style="list-style-type: none"> <li>• Perform hand hygiene.</li> </ul>                                                                                               |                                                                                                |                                                                                                                                                                                                                                                        |
| 13. Document findings in the client record using printed or electronic forms or checklists supplemented by narrative notes when appropriate. Draw location of skin lesions on body surface diagrams. ② |                                                                                                |                                                                                                                                                                                                                                                        |

**CLINICAL ALERT!**

If agency policy permits and the client agrees, take a digital or instant photograph of significant skin lesions for the client record. Include a measuring guide (ruler or tape) in the picture to demonstrate lesion size.



② Diagram for charting skin lesions.

**EVALUATION**

- Compare findings to previous skin assessment data if available to determine if lesions or abnormalities are changing.
- Report significant deviations from expected or normal findings to the primary care provider.

**BOX 30-5** Describing Skin Lesions

- **Type or structure.** Skin lesions are classified as primary (those that appear initially in response to some change in the external or internal environment of the skin) and secondary (those that do not appear initially but result from modifications such as chronicity, trauma, or infection of the primary lesion). For example, a vesicle (primary lesion) may rupture and cause an erosion (secondary lesion).
- **Size, shape, and texture.** Note size in millimeters and whether the lesion is circumscribed or irregular; round or oval shaped; flat, elevated, or depressed; solid, soft, or hard; rough or thickened; fluid filled or has flakes.
- **Color.** There may be no discoloration; one discrete color (e.g., red, brown, or black); or several colors, as with ecchymosis (a bruise), in which an initial dark red or blue color fades to a yellow color. When color changes are limited to the edges of a lesion, they are described as *circumscribed*; when spread over a large area, they are described as *diffuse*.
- **Distribution.** Distribution is described according to the location of the lesions on the body and symmetry or asymmetry of findings in comparable body areas.
- **Configuration.** Configuration refers to the arrangement of lesions in relation to each other. Configurations of lesions may be annular (arranged in a circle), clustered together (grouped), linear (arranged in a line), arc or bow shaped, or merged (indiscrete); may follow the course of cutaneous nerves; or may be meshed in the form of a network.

## LIFESPAN CONSIDERATIONS Assessing the Skin

### INFANTS

- Physiological jaundice may appear in newborns 2 to 3 days after birth and usually lasts about 1 week. Pathologic jaundice, or that which indicates a disease, appears within 24 hours of birth and may last more than 8 days.
- Newborns may have milia (whiteheads), small white nodules over the nose and face, and vernix caseosa (white cheesy, greasy material on the skin).
- Premature infants may have lanugo, a fine downy hair covering their shoulders and back.
- In dark-skinned infants, areas of hyperpigmentation may be found on the back, especially in the sacral area.
- Diaper dermatitis may be seen in infants.
- If a rash is present, inquire in detail about immunization history.
- Assess skin turgor by pinching the skin on the abdomen.

### CHILDREN

- Children normally have minor skin lesions (e.g., bruising or abrasions) on arms and legs due to their high activity level. Lesions on other parts of the body may be signs of disease or abuse, and a thorough history should be taken.
- Secondary skin lesions may occur frequently as children scratch or expose a primary lesion to microbes.
- With puberty, oil glands become more productive, and children may develop acne. Most individuals ages 12 to 24 have some acne.
- In dark-skinned children, areas of hyperpigmentation may be found on the back, especially in the sacral area.
- If a rash is present, inquire in detail about immunization history.

### OLDER ADULTS

- Changes in lighter colored skin occur at an earlier age than in darker skin.

- The skin loses its elasticity, resulting in wrinkles. Wrinkles first appear on the skin of the face and neck, which are abundant in collagen and elastic fibers.
- The skin appears thin and translucent because of loss of dermis and subcutaneous fat.
- The skin is dry and flaky because sebaceous and sweat glands are less active. Dry skin is more prominent over the extremities.
- The skin takes longer to return to its natural shape after being tented between the thumb and finger.
- Due to the normal loss of peripheral skin turgor in older adults, assess for hydration by checking skin turgor over the sternum or clavicle.
- Flat tan to brown-colored macules, referred to as *senile lentiginos* or *melanotic freckles*, are normally apparent on the back of the hand and other skin areas that are exposed to the sun. These macules may be as large as 1 to 2 cm (0.4 to 0.8 in.).
- Warty lesions (*seborrheic keratosis*) with irregularly shaped borders and a scaly surface often occur on the face, shoulders, and trunk. These benign lesions begin as yellowish to tan and progress to a dark brown or black.
- *Vitiligo* tends to increase with age and is thought to result from an autoimmune response.
- Cutaneous tags (*acrochordons*) are most commonly seen in the neck and axillary regions. These skin lesions vary in size and are soft, often flesh colored, and pedicled.
- Visible, bright red, fine dilated blood vessels (*telangiectasias*) commonly occur as a result of the thinning of the dermis and the loss of support for the blood vessel walls.
- Pink to slightly red lesions with indistinct borders (*actinic keratoses*) may appear at about age 50, often on the face, ears, backs of the hands, and arms. They may become malignant if untreated.

## Home Care Considerations Assessing the Skin

### PATIENT-CENTERED CARE

- When making a home visit, take a penlight or examination lamp with you in case the home has inadequate lighting.
- If skin lesions are suggestive of physical abuse, follow state regulations for follow-up and reporting. Signs of abuse may include a pattern of bruises, unusual location of burns, or lesions that are not easily explainable. If lesions are present in adults or verbal-age children, conduct the interview and assessment in private.
- Document lesions in the health record by taking a photo (if agency policy permits and client consents). Because digital cameras are common (including on cell phones and tablet

computers), clients can be encouraged to take pictures of their lesions in order to check changes over time or to send to the health care provider.

- Another method that can be used to record lesion size and shape is to lay clean double-thick clear plastic (such as a grocery bag) over the lesion or wound and trace the shape with a permanent marker. Cut away and dispose of the bottom layer that came in contact with the client and place the top layer in the client record. Use this method only if contact with the plastic does not contaminate the wound.

## Hair

Assessing a client's hair includes inspecting the hair, considering developmental changes and ethnic differences, and determining the individual's hair care practices and factors influencing them. Much of the information about hair can be obtained by questioning the client.

Normal hair is resilient and evenly distributed. In people with severe protein deficiency (kwashiorkor), the hair color is faded and appears reddish or bleached, and the texture is coarse and dry. Some therapies cause **alopecia** (hair loss), and some disease conditions and medications affect the coarseness of hair.

For example, hypothyroidism can cause very thin and brittle hair. Skill 30–3 describes how to assess the hair.

## Nails

Nails are inspected for nail plate shape, angle between the fingernail and the nail bed, nail texture, nail bed color, and the intactness of the tissues around the nails. The parts of the nail are shown in Figure 30–9 ■.

The nail plate is normally colorless and has a convex curve. The angle between the fingernail and the nail bed is normally 160 degrees (Figure 30–10A ■). One nail abnormality is the spoon shape, in which the nail curves upward from the nail bed (Figure 30–10, B).



## Assessing the Hair

### PLANNING

#### DELEGATION

Due to the substantial knowledge and skill required, assessment of the hair is not delegated to UAP. However, many aspects are observed during usual care and may be recorded by individuals other than the nurse. Abnormal findings must be validated and interpreted by the nurse.

#### Equipment

- Clean gloves

### IMPLEMENTATION

#### Performance

1. Prior to performing the procedure, introduce self and verify the client's identity using agency protocol. Explain to the client what you are going to do, why it is necessary, and how he or she can participate. Discuss how the results will be used in planning further care or treatments.
2. Perform hand hygiene, apply gloves, and observe other appropriate infection prevention procedures.
3. Provide for client privacy.
4. Inquire if the client has any history of the following: recent use of hair dyes, rinses, or curling or straightening preparations; recent chemotherapy (if alopecia is present); presence of disease, such as hypothyroidism, which can be associated with dry, brittle hair.

#### Assessment

#### Normal Findings

#### Deviations from Normal

|                                                                                                                                                   |                             |                                                                                                  |
|---------------------------------------------------------------------------------------------------------------------------------------------------|-----------------------------|--------------------------------------------------------------------------------------------------|
| 5. Inspect the evenness of growth over the scalp.                                                                                                 | Evenly distributed hair     | Patches of hair loss (i.e., alopecia)                                                            |
| 6. Inspect hair thickness or thinness.                                                                                                            | Thick hair                  | Very thin hair (e.g., in hypothyroidism)                                                         |
| 7. Inspect hair texture and oiliness.                                                                                                             | Silky, resilient hair       | Brittle hair (e.g., hypothyroidism); excessively oily or dry hair                                |
| 8. Note presence of infections or infestations by parting the hair in several areas, checking behind the ears and along the hairline at the neck. | No infection or infestation | Flaking, sores, lice, nits (lice eggs), and ringworm                                             |
| 9. Inspect amount of body hair.                                                                                                                   | Variable                    | Hirsutism (excessive hairiness) in women; naturally absent or sparse leg hair (poor circulation) |
| 10. Remove and discard gloves. <ul style="list-style-type: none"> <li>• Perform hand hygiene.</li> </ul>                                          |                             |                                                                                                  |
| 11. Document findings in the client record using printed or electronic forms or checklists supplemented by narrative notes when appropriate.      |                             |                                                                                                  |

### EVALUATION

- Perform a detailed follow-up examination based on findings that deviated from expected or normal for the client. Relate findings to previous assessment data if available.
- Report significant deviations from expected or normal findings to the primary care provider.

## LIFESPAN CONSIDERATIONS Assessing the Hair

### INFANTS

- It is normal for infants to have either very little or a great deal of body and scalp hair.

### CHILDREN

- As puberty approaches, axillary and pubic hair will appear (see Box 30-9 later in this chapter).

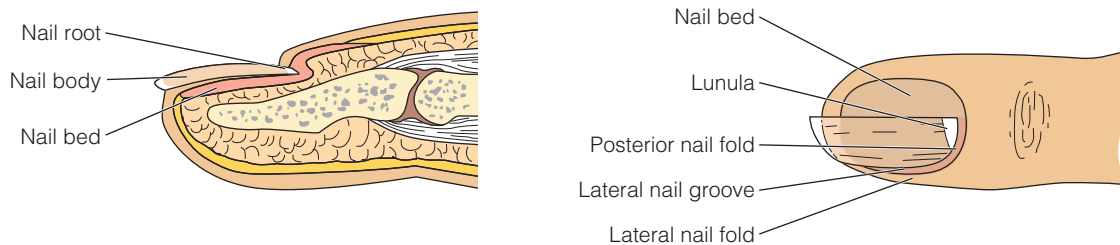
### OLDER ADULTS

- Older adults may experience a loss of scalp, pubic, and axillary hair.
- Hairs of the eyebrows, ears, and nostrils become bristle-like and coarse.

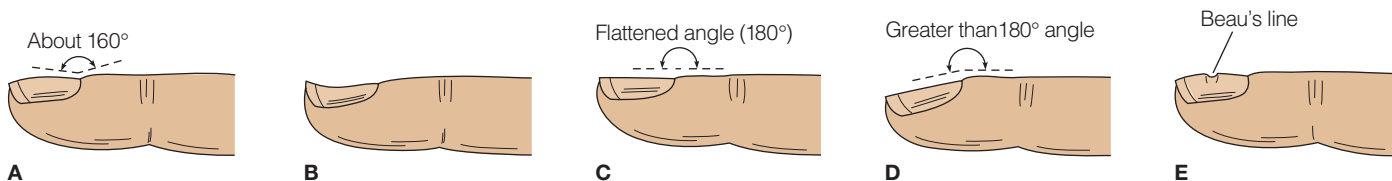
## Home Care Considerations Assessing the Hair

### PATIENT-CENTERED CARE

- When making a home visit, ask to see the products the client usually uses on the hair. Assist the client to determine if the products are appropriate for the client's type of hair and scalp (e.g., for dry or oily hair). Provide education regarding hygiene of the hair and scalp.
- When making a home visit, examine the equipment that the client uses on the hair. Provide client teaching regarding appropriate combs and brushes and regarding safety in using electric hair styling appliances such as hair dryers.



**Figure 30-9** ■ The parts of a nail.



**Figure 30-10** ■ A, A normal nail, showing the convex shape and the nail plate angle of about 160°; B, a spoon-shaped nail, which may be seen in clients with iron deficiency anemia; C, early clubbing; D, late clubbing (may be caused by long-term oxygen deficit); E, Beau's line on nail (may result from severe injury or illness).

This condition, called koilonychia, may be seen in clients with iron deficiency anemia. **Clubbing** is a condition in which the angle between the nail and the nail bed is 180 degrees, or greater (Figure 30-10C and D). Clubbing may be caused by a long-term lack of oxygen.

Nail texture is normally smooth. Excessively thick nails can appear in older adults, in the presence of poor circulation, or in relation to a chronic fungal infection. Excessively thin nails or the presence of grooves or furrows can reflect prolonged iron deficiency anemia. Beau's lines are horizontal depressions in the nail that can result from injury or severe illness (Figure 30-10E). The nail bed is highly vascular, a characteristic that accounts for its color. A bluish or purplish tint to the nail bed may reflect cyanosis, and pallor may reflect poor arterial circulation. Should the client report a history of

nail fungus (onychomycosis), a referral to a podiatrist or dermatologist for treatment of nail fungus may be appropriate. Symptoms of nail fungus include brittleness, discoloration, thickening, distortion of nail shape, crumbling of the nail, and loosening (detaching) of the nail.

The tissue surrounding the nails is normally intact epidermis. Paronychia is an inflammation of the tissues surrounding a nail. The tissues appear inflamed and swollen, and tenderness is usually present.

A **blanch test** can be carried out to test the capillary refill, that is, peripheral circulation. Normal nail bed capillaries blanch when pressed, but quickly turn pink or their usual color when pressure is released. A slow rate of capillary refill may indicate circulatory problems. Skill 30-4 describes how to assess the nails.

## Assessing the Nails

### PLANNING DELEGATION

Due to the substantial knowledge and skill required, assessment of the nails is not delegated to UAP. However, many aspects are observed during usual care and may be recorded by individuals other than the nurse. Abnormal findings must be validated and interpreted by the nurse.

### Equipment

None

### IMPLEMENTATION Performance

1. Prior to performing the procedure, introduce self and verify the client's identity using agency protocol. Explain to the client what you are going to do, why it is necessary, and how he or she can participate. Discuss how the results will be used in planning further care or treatments. In most situations, clients with artificial nails or polish on fingernails or toenails are not required to remove these for assessment; however, if the assessment cannot

### INTERPROFESSIONAL PRACTICE

Assessing the nails is within the scope of practice for many health care providers other than nurses. Although these providers may verbally communicate their findings and plan to other health care team members, the nurse must also know where to locate their documentation in the client's medical record.

- be conducted due to the presence of polish or artificial nails, document this in the record.
2. Perform hand hygiene and observe other appropriate infection prevention procedures.
3. Provide for client privacy.
4. Inquire if the client has any history of the following: presence of diabetes mellitus, peripheral circulatory disease, previous injury, or severe illness.

## Assessing the Nails—continued

| Assessment                                                                                                                                                                                                    | Normal Findings                                                                                                                      | Deviations from Normal                                                                                                       |
|---------------------------------------------------------------------------------------------------------------------------------------------------------------------------------------------------------------|--------------------------------------------------------------------------------------------------------------------------------------|------------------------------------------------------------------------------------------------------------------------------|
| 5. Inspect fingernail plate shape to determine its curvature and angle.                                                                                                                                       | Convex curvature; angle of nail plate about 160° (Figure 30-10A)                                                                     | Spoon nail (Figure 30-10B); clubbing (180° or greater) (Figure 30-10C and D)                                                 |
| 6. Inspect fingernail and toenail texture.                                                                                                                                                                    | Smooth texture                                                                                                                       | Excessive thickness or thinness or presence of grooves or furrows; Beau's lines (Figure 30-10E); discolored or detached nail |
| 7. Inspect fingernail and toenail bed color.                                                                                                                                                                  | Highly vascular and pink in light-skinned clients; dark-skinned clients may have brown or black pigmentation in longitudinal streaks | Bluish or purplish tint (may reflect cyanosis); pallor (may reflect poor arterial circulation)                               |
| 8. Inspect tissues surrounding nails.                                                                                                                                                                         | Intact epidermis                                                                                                                     | Hangnails; paronychia (inflammation)                                                                                         |
| 9. Perform blanch test of capillary refill. Press the nails between your thumb and index finger; look for blanching and return of pink color to nail bed. Perform on at least one nail on each hand and foot. | Prompt return of pink or usual color (generally less than 2 seconds)                                                                 | Delayed return of pink or usual color (may indicate circulatory impairment)                                                  |
| 10. Document findings in the client record using printed or electronic forms or checklists supplemented by narrative notes when appropriate.                                                                  |                                                                                                                                      |                                                                                                                              |

### EVALUATION

- Perform a detailed follow-up examination of other systems based on findings that deviated from expected or normal for the client. Relate findings to previous assessment data if available.
- Report significant deviations from expected or normal to the primary care provider.

## LIFESPAN CONSIDERATIONS Assessing the Nails

### INFANTS

- Newborns nails grow very quickly, are extremely thin, and tear easily.

### CHILDREN

- Bent, bruised, or ingrown toenails may indicate shoes that are too tight.
- Nail biting should be discussed with an adult family member because it may be a symptom of stress.

### OLDER ADULTS

- The nails grow more slowly and thicken.
- Longitudinal bands commonly develop, and the nails tend to split.
- Bands across the nails may indicate protein deficiency; white spots, zinc deficiency; spoon-shaped nails may indicate iron deficiency.
- Toenail fungus is more common and difficult to eliminate (although not dangerous to health).

## Home Care Considerations Assessing the Nails

### PATIENT-CENTERED CARE

- If indicated, teach the client or family member about proper nail care including how to trim and shape the nails to avoid paronychia. To avoid cutting the skin accidentally, file infant nails instead of clipping.
- If eyesight, fine motor control, or cognition prevents the client from safely trimming the nails, refer the client to a podiatrist or manicurist if the client requires assistance with nail care.

## HEAD

During assessment of the head, the nurse inspects and palpates simultaneously and also auscultates. The nurse examines the skull, face, eyes, ears, nose, sinuses, mouth, and pharynx.

### Skull and Face

There is a large range of normal shapes of skulls. A normal head size is referred to as **normocephalic**. If head size appears to be outside of the normal range, the circumference can be compared to standard size tables. Measurements more than two standard deviations from the norm for the age, sex, and race of the client are abnormal and should be reported to the primary care provider. Names of areas of the head are derived from names of the underlying bones: frontal, parietal, occipital, mastoid process, mandible, maxilla, and zygomatic (Figure 30-11 ■).

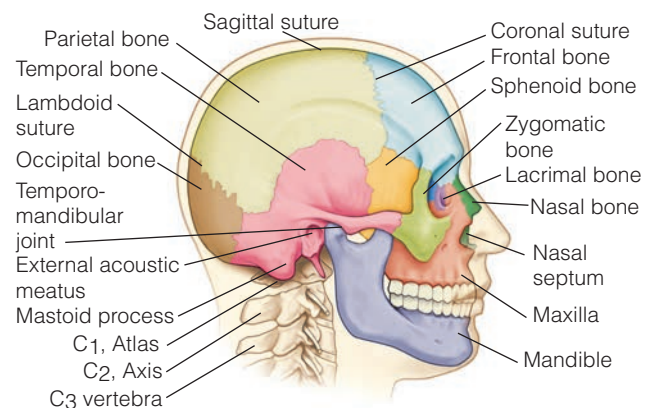


Figure 30-11 ■ Bones of the head.

Many disorders cause a change in facial shape or condition. Kidney or cardiac disease can cause edema of the eyelids. Hyperthyroidism can cause **exophthalmos**, a protrusion of the eyeballs with elevation of the upper eyelids, resulting in a startled or staring expression. Hypothyroidism, or myxedema, can cause a dry, puffy face with dry skin and coarse features and thinning of scalp hair and eyebrows.

Increased adrenal hormone production or administration of steroids can cause a round face with reddened cheeks, referred to as *moon face*, and excessive hair growth on the upper lips, chin, and sideburn areas. Prolonged illness, starvation, and dehydration can result in sunken eyes, cheeks, and temples. Skill 30–5 describes how to assess the skull and face.

## Assessing the Skull and Face

### PLANNING DELEGATION

Due to the substantial knowledge and skill required, assessment of the skull and face is not delegated to UAP. However, many aspects are observed during usual care and may be recorded by individuals other than the nurse. Abnormal findings must be validated and interpreted by the nurse.

#### Equipment

None

### IMPLEMENTATION

#### Performance

1. Prior to performing the procedure, introduce self and verify the client's identity using agency protocol. Explain to the client what you are going to do, why it is necessary, and how he or she can participate. Discuss how the results will be used in planning further care or treatments.
2. Perform hand hygiene and observe other appropriate infection prevention procedures.

### INTERPROFESSIONAL PRACTICE

Assessing the skull and face is within the scope of practice of many health care providers other than nurses. Although these other providers may verbally communicate their findings and plan to health care team members, the nurse must also know where to locate their documentation in the client's medical record.

3. Provide for client privacy.
4. Inquire if the client has any history of the following: past problems with lumps or bumps, itching, scaling, or dandruff; history of loss of consciousness, dizziness, seizures, headache, facial pain, or injury; when and how any lumps occurred; length of time any other problem existed; any known cause of problem; associated symptoms, treatment, and recurrences.

#### Assessment

| Assessment                                                                                                                                                                         | Normal Findings                                                                                                | Deviations from Normal                                                                                                                                            |
|------------------------------------------------------------------------------------------------------------------------------------------------------------------------------------|----------------------------------------------------------------------------------------------------------------|-------------------------------------------------------------------------------------------------------------------------------------------------------------------|
| 5. Inspect the skull for size, shape, and symmetry.                                                                                                                                | Rounded (normocephalic and symmetric, with frontal, parietal, and occipital prominences); smooth skull contour | Lack of symmetry; increased skull size with more prominent nose and forehead; longer mandible (may indicate excessive growth hormone or increased bone thickness) |
| 6. Inspect the facial features (e.g., symmetry of structures and of the distribution of hair).                                                                                     | Symmetric or slightly asymmetric facial features; palpebral fissures equal in size; symmetric nasolabial folds | Increased facial hair; low hair line; thinning of eyebrows; asymmetric features; exophthalmos; myxedema facies; moon face                                         |
| 7. Inspect the eyes for edema or hollowness.                                                                                                                                       | No edema                                                                                                       | Periorbital edema; sunken eyes                                                                                                                                    |
| 8. Note symmetry of facial movements. Ask the client to elevate the eyebrows, frown, or lower the eyebrows, close the eyes tightly, puff the cheeks, and smile and show the teeth. | Symmetric facial movements                                                                                     | Asymmetric facial movements (e.g., eye cannot close completely); drooping of lower eyelid and mouth; involuntary facial movements (i.e., tics or tremors)         |
| 9. Document findings in the client record using printed or electronic forms or checklists supplemented by narrative notes when appropriate.                                        |                                                                                                                |                                                                                                                                                                   |

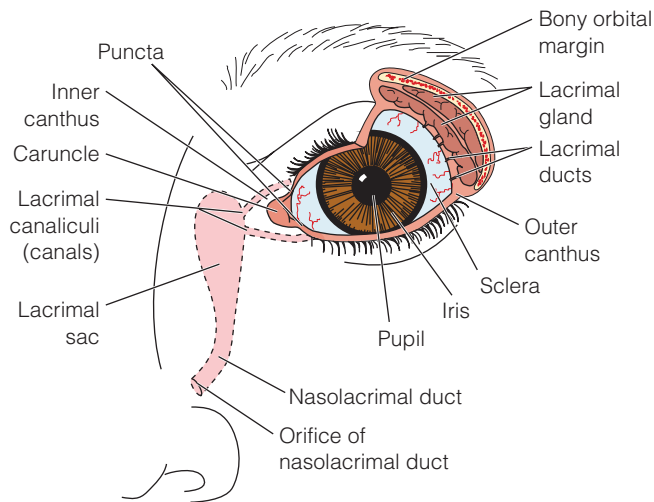
### EVALUATION

- Perform a detailed follow-up examination of other systems based on findings that deviated from expected or normal for the client. Relate findings to previous assessment data if available.
- Report deviations from expected or normal findings to the primary care provider.

## LIFESPAN CONSIDERATIONS Assessing the Skull and Face

### INFANTS

- Newborns delivered vaginally can have elongated, molded heads, which take on more rounded shapes after a week or two. Infants born by cesarean section tend to have smooth, rounded heads.
- The posterior fontanel (soft spot) is about 1 cm (0.4 in.) in size and usually closes by 8 weeks. The anterior fontanel is larger, about 2 to 3 cm (0.8 to 1.2 in.) in size. It closes by 18 months.
- Newborns can lift their heads slightly and turn them from side to side. Voluntary head control is well established by 4 to 6 months.



**Figure 30-12** ■ The external structures and lacrimal apparatus of the left eye.

## Eyes and Vision

To maintain optimum vision, people need to have their eyes examined regularly throughout life. It is recommended that people under age 40 have their eyes tested every 3 to 5 years, or more frequently if there is a family history of diabetes, hypertension, blood dyscrasia, or eye disease (e.g., glaucoma). After age 40, an eye examination is recommended every 2 years.

Examination of the eyes includes assessment of the external structures, **visual acuity** (the degree of detail the eye can discern in an image), ocular movement, and **visual fields** (the area an individual can see when looking straight ahead). Most eye assessment procedures involve inspection. Consideration is also given to developmental changes and to individual hygienic practices, if the client wears contact lenses or has an artificial eye. For the anatomic structures of the eye, see Figure 30-12 ■ and Figure 30-13 ■.

Many people wear eyeglasses or contact lenses to correct common refractive errors of the lens of the eye. These errors include **myopia** (nearsightedness), **hyperopia** (farsightedness), and **presbyopia** (loss of elasticity of the lens and thus loss of ability to see close objects). Presbyopia begins at about 45 years of age. People notice that they have difficulty reading newsprint. When both far

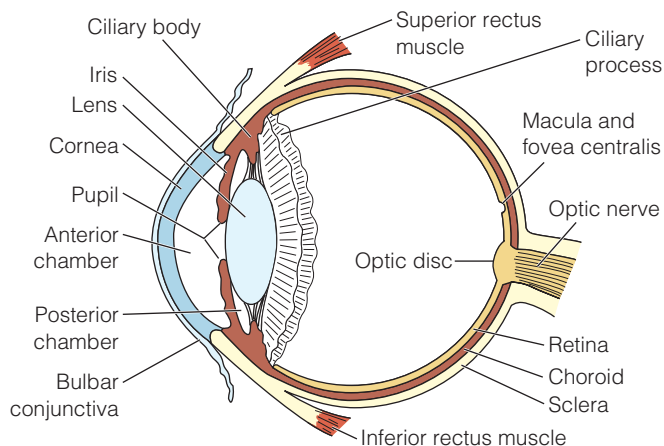
and near vision require correction, two lenses (bifocals) are required. **Astigmatism**, an uneven curvature of the cornea that prevents horizontal and vertical rays from focusing on the retina, is a common problem that may occur in conjunction with myopia and hyperopia. Astigmatism may be corrected with glasses or surgery.

Three types of eye charts are available to test visual acuity (Figure 30-14 ■). People with denominators of 40 or more on the Snellen chart with or without corrective lenses need to be referred to an optometrist or ophthalmologist.

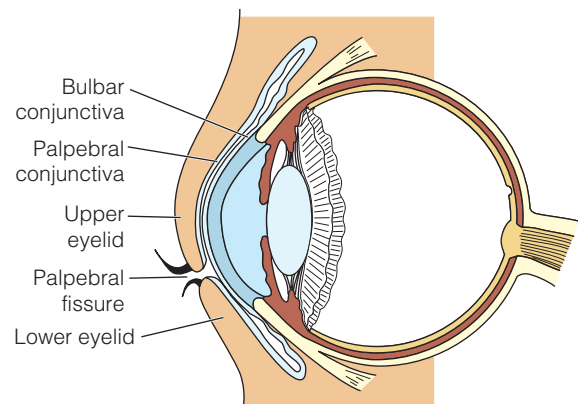
Common inflammatory visual problems that nurses may encounter in clients include conjunctivitis, dacryocystitis, hordeolum, iritis, and contusions or hematomas of the eyelids and surrounding structures. **Conjunctivitis** (inflammation of the bulbar and palpebral conjunctiva) may result from foreign bodies, chemicals, allergenic agents, bacteria, or viruses. Redness, itching, tearing, and mucopurulent discharge occur. During sleep, the eyelids may become encrusted and matted together. **Dacryocystitis** (inflammation of the lacrimal sac) is manifested by tearing and a discharge from the nasolacrimal duct. **Hordeolum (sty)** is a redness, swelling, and tenderness of the hair follicle and glands that empty at the edge of the eyelids. **Iritis** (inflammation of the iris) may be caused by local or systemic infections and results in pain, tearing, and photophobia (sensitivity to light). Contusions or hematomas are “black eyes” resulting from injury.

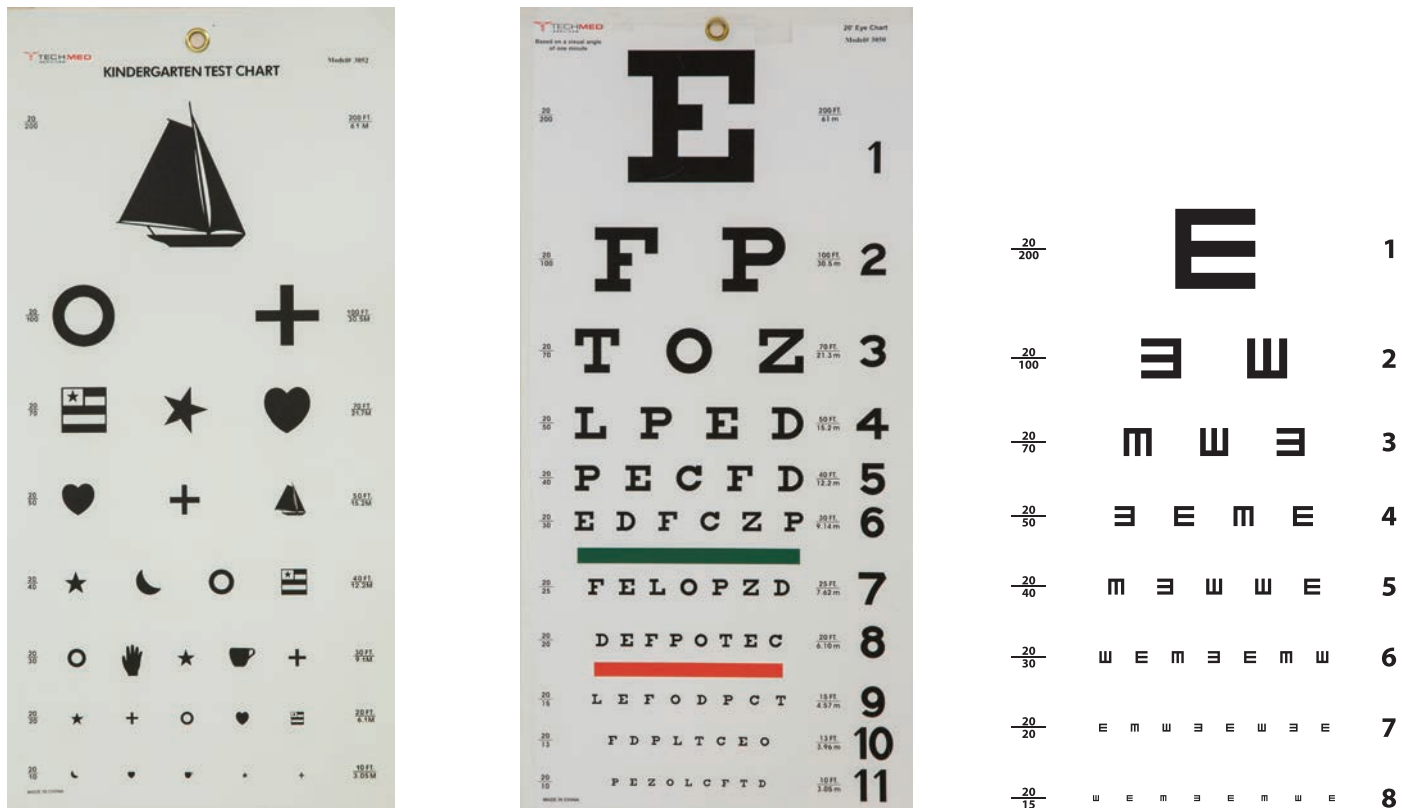
**Cataracts** tend to occur in individuals over 65 years old although they may be present at any age. This opacity of the lens or its capsule, which blocks light rays, is frequently removed and replaced by a lens implant. Cataracts may also occur in infants due to a malformation of the lens if the mother contracted rubella in the first trimester of pregnancy. **Glaucoma** (a disturbance in the circulation of aqueous fluid, which causes an increase in intraocular pressure) is the most frequent cause of blindness in people over age 40 although it can occur at younger ages. It can be controlled if diagnosed early. Danger signs of glaucoma include blurred or foggy vision, loss of peripheral vision, difficulty focusing on close objects, difficulty adjusting to dark rooms, and seeing rainbow-colored rings around lights.

Upper eyelids that lie at or below the pupil margin are referred to as ptosis and are usually associated with aging, edema from drug allergy or systemic disease (e.g., kidney disease), congenital lid muscle



**Figure 30-13** ■ Anatomic structures of the right eye, lateral view.





**Figure 30-14** ■ Three types of eye charts: *left*, the preschool children's chart; *center*, the Snellen standard chart; *right*, Snellen E chart for clients unable to read.  
right, Roman Sotola/Shutterstock.

dysfunction, neuromuscular disease (e.g., myasthenia gravis), and third cranial nerve impairment. Eversion, an outturning of the eyelid, is called ectropion; inversion, an inturning of the lid, is called entropion. These abnormalities are often associated with scarring injuries or the aging process.

Pupils are normally black, are equal in size (about 3 to 7 mm in diameter), and have round, smooth borders. Cloudy pupils are often indicative of cataracts. **Mydriasis** (enlarged pupils) may indicate injury or glaucoma, or result from certain drugs (e.g., atropine,

cocaine, amphetamines). **Miosis** (constricted pupils) may indicate an inflammation of the iris or result from such drugs as morphine/heroin and other narcotics, barbiturates, or pilocarpine. It is also an age-related change in older adults. **Anisocoria** (unequal pupils) may result from a central nervous system disorder; however, slight variations may be normal. The iris is normally flat and round. A bulging toward the cornea can indicate increased intraocular pressure. Skill 30-6 describes how to assess a client's eye structures and visual acuity.

## Assessing the Eye Structures and Visual Acuity

### PLANNING

Place the client in an appropriate room for assessing the eyes and vision. The nurse must be able to control natural and overhead lighting during some portions of the examination.

### Equipment

- Millimeter ruler
- Penlight
- Snellen or E chart
- Opaque card

### DELEGATION

Due to the substantial knowledge and skill required, assessment of the eyes and vision is not delegated to UAP. However, many aspects are observed during usual care and may be recorded by individuals other than the nurse. Abnormal findings must be validated and interpreted by the nurse.

### INTERPROFESSIONAL PRACTICE


Assessing the eyes and vision may be within the scope of practice of other health care providers. Although these providers may verbally communicate their findings and plan to other health care team members, the nurse must also know where to locate their documentation in the client's medical record.

## Assessing the Eye Structures and Visual Acuity—continued

### IMPLEMENTATION

#### Performance

- Prior to performing the procedure, introduce self and verify the client's identity using agency protocol. Explain to the client what you are going to do, why it is necessary, and how he or she can participate. Discuss how the results will be used in planning further care or treatments.
- Perform hand hygiene, apply gloves, and observe other appropriate infection prevention procedures.
- Provide for client privacy.
- Inquire if the client has any history of the following: family history of diabetes, hypertension, blood dyscrasia, or eye disease, injury, or surgery; client's last visit to a provider who specifically assessed the eyes (e.g., ophthalmologist or optometrist); current use of eye medications; use of contact lenses or eye-glasses; hygienic practices for corrective lenses; current symptoms of eye problems (e.g., changes in visual acuity, blurring of vision, tearing, spots, photophobia, itching, or pain).

| Assessment                                                                                                                                                                                                                                                                                                                                                                                                                                                                                                                                                                                                            | Normal Findings                                                                                                                                                                         | Deviations from Normal                                                                                                                                                                                                                       |
|-----------------------------------------------------------------------------------------------------------------------------------------------------------------------------------------------------------------------------------------------------------------------------------------------------------------------------------------------------------------------------------------------------------------------------------------------------------------------------------------------------------------------------------------------------------------------------------------------------------------------|-----------------------------------------------------------------------------------------------------------------------------------------------------------------------------------------|----------------------------------------------------------------------------------------------------------------------------------------------------------------------------------------------------------------------------------------------|
| <b>EXTERNAL EYE STRUCTURES</b>                                                                                                                                                                                                                                                                                                                                                                                                                                                                                                                                                                                        |                                                                                                                                                                                         |                                                                                                                                                                                                                                              |
| 5. Inspect the eyebrows for hair distribution and alignment and skin quality and movement (ask client to raise and lower the eyebrows).                                                                                                                                                                                                                                                                                                                                                                                                                                                                               | Hair evenly distributed; skin intact<br>Eyebrows symmetrically aligned; equal movement                                                                                                  | Loss of hair; scaling and flakiness of skin<br>Unequal alignment and movement of eyebrows                                                                                                                                                    |
| 6. Inspect the eyelashes for evenness of distribution and direction of curl.                                                                                                                                                                                                                                                                                                                                                                                                                                                                                                                                          | Equally distributed; curled slightly outward                                                                                                                                            | Turned inward                                                                                                                                                                                                                                |
| 7. Inspect the eyelids for surface characteristics (e.g., skin quality and texture), position in relation to the cornea, ability to blink, and frequency of blinking. Inspect the lower eyelids while the client's eyes are closed.                                                                                                                                                                                                                                                                                                                                                                                   | Skin intact; no discharge; no discoloration<br>Lids close symmetrically                                                                                                                 | Redness, swelling, flaking, crusting, plaques, discharge, nodules, lesions<br>Lids close asymmetrically, incompletely, or painfully                                                                                                          |
| 8. Remove and discard gloves. <ul style="list-style-type: none"> <li>Perform hand hygiene.</li> </ul>                                                                                                                                                                                                                                                                                                                                                                                                                                                                                                                 | Approximately 15 to 20 involuntary blinks per minute; bilateral blinking<br>When lids open, no visible sclera above corneas, and upper and lower borders of cornea are slightly covered | Rapid, monocular, absent, or infrequent blinking<br>Ptosis, ectropion, or entropion; rim of sclera visible between lid and iris                                                                                                              |
| <b>EXTERNAL EYE STRUCTURES</b>                                                                                                                                                                                                                                                                                                                                                                                                                                                                                                                                                                                        |                                                                                                                                                                                         |                                                                                                                                                                                                                                              |
| 9. Inspect the bulbar conjunctiva (that lying over the sclera) for color, texture, and the presence of lesions.                                                                                                                                                                                                                                                                                                                                                                                                                                                                                                       | Transparent; capillaries sometimes evident; sclera appears white (darker or yellowish and with small brown macules in dark-skinned clients)                                             | Jaundiced sclera (e.g., in liver disease); excessively pale sclera (e.g., in anemia); reddened sclera (marijuana use, rheumatoid disease); lesions or nodules (may indicate damage by mechanical, chemical, allergenic, or bacterial agents) |
| 10. Inspect the cornea for clarity and texture. Ask the client to look straight ahead. Hold a penlight at an oblique angle to the eye, and move the light slowly across the corneal surface.                                                                                                                                                                                                                                                                                                                                                                                                                          | Transparent, shiny, and smooth; details of the iris are visible<br>In older people, a thin, grayish white ring around the margin, called arcus senilis, may be evident                  | Opaque; surface not smooth (may be the result of trauma or abrasion)<br>Arcus senilis in clients under age 40                                                                                                                                |
| 11. Inspect the pupils for color, shape, and symmetry of size. Pupil charts are available in some agencies. See 1 for variations in pupil diameters.                                                                                                                                                                                                                                                                                                                                                                                                                                                                  | Black in color; equal in size; normally 3 to 7 mm in diameter; round, smooth border, iris flat and round                                                                                | Cloudiness, mydriasis, miosis, anisocoria; bulging of iris toward cornea                                                                                                                                                                     |
|  <p>1 Variations in pupil diameters in millimeters.</p>                                                                                                                                                                                                                                                                                                                                                                                                                                                                           |                                                                                                                                                                                         |                                                                                                                                                                                                                                              |
| 12. Assess each pupil's direct and consensual reaction to light to determine the function of the third (oculomotor) and fourth (trochlear) cranial nerves. <ul style="list-style-type: none"> <li>Partially darken the room.</li> <li>Ask the client to look straight ahead.</li> <li>Using a penlight and approaching from the side, shine a light on the pupil.</li> <li>Observe the response of the illuminated pupil. It should constrict (direct response).</li> <li>Shine the light on the pupil again, and observe the response of the other pupil. It should also constrict (consensual response).</li> </ul> | Illuminated pupil constricts (direct response)<br>Nonilluminated pupil constricts (consensual response)<br>Response is brisk                                                            | Neither pupil constricts<br>Unequal responses<br>Response is sluggish<br>Absent responses                                                                                                                                                    |

## Assessing the Eye Structures and Visual Acuity—continued

## Assessment

13. Assess each pupil's reaction to accommodation.
- Hold an object (a penlight or pencil) about 10 cm (4 in.) from the bridge of the client's nose.
  - Ask the client to look first at the top of the object and then at a distant object (e.g., the far wall) behind the penlight. Alternate the gaze from the near to the far object. Observe the pupil response.
  - Next, ask the client to look at the near object and then move the penlight or pencil toward the client's nose.

## Normal Findings

Pupils constrict when looking at near object; pupils dilate when looking at far object

Pupils converge when near object is moved toward nose. To record normal assessment of the pupils, use the abbreviation **PERRLA** (pupils equally round and react to light and accommodation).

## Deviations from Normal

One or both pupils fail to constrict, dilate, or converge

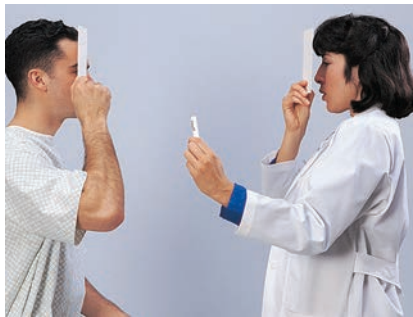## VISUAL FIELDS

14. Assess peripheral visual fields to determine function of the retina and neuronal visual pathways to the brain and second (optic) cranial nerve.
- Have the client sit directly facing you at a distance of 60 to 90 cm (2 to 3 ft).
  - Ask the client to cover the right eye with a card and look directly at your nose.
  - Cover or close your eye directly opposite the client's covered eye (i.e., your left eye), and look directly at the client's nose.
  - Hold an object (e.g., a penlight or pencil) in your fingers, extend your arm, and move the object into the visual field from various points in the periphery. The object should be at an equal distance from the client and yourself. Ask the client to tell you when the moving object is first spotted.
    - To test the temporal field of the left eye, extend and move your right arm in from the client's right periphery.
    - To test the upward field of the left eye, extend and move the right arm down from the upward periphery.
    - To test the downward field of the left eye, extend and move the right arm up from the lower periphery.
    - To test the nasal field of the left eye, extend and move your left arm in from the periphery. ②
  - Repeat the above steps for the right eye, reversing the process.

When looking straight ahead, client can see objects in the periphery

Temporally, peripheral objects can be seen at right angles (90°) to the central point of vision. The upward field of vision is normally 50°, because the orbital ridge is in the way. The downward field of vision is normally 70°, because the cheekbone is in the way. The nasal field of vision is normally 50° away from the central point of vision because the nose is in the way.

Visual field smaller than normal (possible glaucoma); one-half vision in one or both eyes (possible nerve damage)



② Assessing the client's left peripheral visual field.

## EXTRAOCULAR MUSCLE TESTS

15. Assess six ocular movements to determine eye alignment and coordination.
- Stand directly in front of the client and hold the penlight at a comfortable distance, such as 30 cm (1 ft) in front of the client's eyes.
  - Ask the client to hold the head in a fixed position facing you and to follow the movements of the penlight with the eyes only.

Both eyes coordinated, move in unison, with parallel alignment

Eye movements not coordinated or parallel; one or both eyes fail to follow a penlight in specific directions, e.g., **strabismus** (cross-eye)

**Nystagmus** (rapid involuntary rhythmic eye movement) other than at end point may indicate neurologic impairment

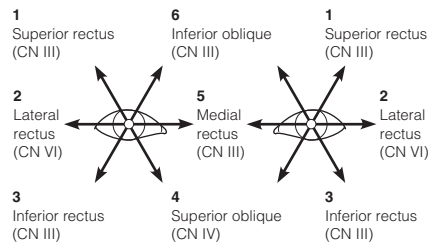


## Assessing the Eye Structures and Visual Acuity—continued

### Assessment

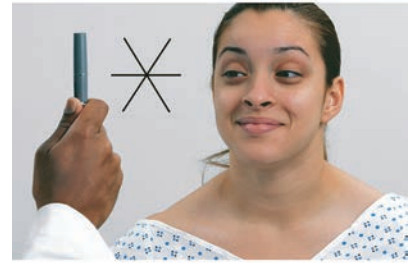
- Move the penlight in a slow, orderly manner through the six cardinal fields of gaze, that is, from the center of the eye along the lines of the arrows in 3 and back to the center.
- Stop the movement of the penlight periodically so that nystagmus can be detected.

### Normal Findings



3 The six muscles that govern eye movement.

### Deviations from Normal



16. Assess for location of light reflex by shining penlight on the corneal surface (Hirschberg test).
17. Have client fixate on a near or far object. Cover one eye and observe for movement in the uncovered eye (cover test).

Light falls symmetrically (e.g., at “6 o’clock” on both pupils)

Light falls off center on one eye

Uncovered eye does not move

If misalignment is present, when dominant eye is covered, the uncovered eye will move to focus on object

### VISUAL ACUITY

18. If the client can read, assess near vision by providing adequate lighting and asking the client to read from a magazine or newspaper held at a distance of 36 cm (14 in.). If the client normally wears corrective lenses, the glasses or lenses should be worn during the test. The document must be in a language the client can read.

Able to read newsprint

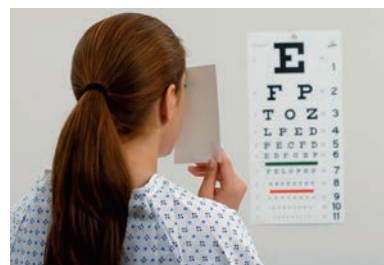Difficulty reading newsprint unless due to aging process

### CLINICAL ALERT!

A Rosenbaum eye chart may be used to test near vision. It consists of paragraphs of text or characters in different sizes. Be sure the client has a literacy level appropriate for the text used.

19. Assess distance vision by asking the client to wear corrective lenses, unless they are used for reading only (i.e., for distances of only 36 cm [14 in.]).
  - Ask the client to stand or sit 6 m (20 ft) from a Snellen or character chart 4, cover the eye not being tested, and identify the letters or characters on the chart.
  - Take three readings: right eye, left eye, both eyes.
  - Record the readings of each eye and both eyes (i.e., the smallest line from which the person is able to read one-half or more of the letters).

20/20 vision on Snellen-type chart



4 Testing distance vision.

Denominator of 40 or more on Snellen-type chart with corrective lenses

## Assessing the Eye Structures and Visual Acuity—continued

| Assessment                                                                                                                                                                                                                                                                                                                                                                                                                                                                                                                                                                                                                                                                                                                                                                                                                                                                                                                                                                                                                                        | Normal Findings | Deviations from Normal                                                                         |
|---------------------------------------------------------------------------------------------------------------------------------------------------------------------------------------------------------------------------------------------------------------------------------------------------------------------------------------------------------------------------------------------------------------------------------------------------------------------------------------------------------------------------------------------------------------------------------------------------------------------------------------------------------------------------------------------------------------------------------------------------------------------------------------------------------------------------------------------------------------------------------------------------------------------------------------------------------------------------------------------------------------------------------------------------|-----------------|------------------------------------------------------------------------------------------------|
| <p>At the end of each line of the chart are standardized numbers (fractions). The top line is 20/200. The numerator (top number) is always 20, the distance the person stands from the chart. The denominator (bottom number) is the distance from which the normal eye can read the chart. Therefore, a person who has 20/40 vision can see at 20 feet from the chart what a normal-sighted person can see at 40 feet from the chart. Visual acuity is recorded as “S-c” (without correction), or “C-c” (with correction). You can also indicate how many letters were misread in the line, e.g., “visual acuity 20/40 – 2 C-c” indicates that two letters were misread in the 20/40 line by a client wearing corrective lenses.</p> <p><b>20.</b> If the client is unable to see even the top line (20/200) of the Snellen-type chart, perform selected vision tests (Box 30-6).</p> <p><b>21.</b> Document findings in the client record using printed or electronic forms or checklists supplemented by narrative notes when appropriate.</p> |                 |                                                                                                |
|                                                                                                                                                                                                                                                                                                                                                                                                                                                                                                                                                                                                                                                                                                                                                                                                                                                                                                                                                                                                                                                   |                 | Limited vision only (e.g., light perception, hand movements, counting fingers at 30 cm (1 ft)) |
| <p><b>EVALUATION</b></p> <ul style="list-style-type: none"> <li>Perform a detailed follow-up examination of other systems based on findings that deviated from expected or normal for the client. Relate findings to previous assessment data if available.</li> <li>Report deviations from expected or normal findings to the primary care provider. Individuals with denominators of 40 or more on the Snellen or character chart, with or without corrective lenses, may need to be referred to an optometrist or ophthalmologist.</li> </ul>                                                                                                                                                                                                                                                                                                                                                                                                                                                                                                  |                 |                                                                                                |

### LIFESPAN CONSIDERATIONS Assessing the Eyes and Vision

#### INFANTS

- Infants 4 weeks of age should gaze at and follow objects.
- Ability to focus with both eyes should be present by 6 months of age.
- Infants do not have tears until about 3 months of age.
- Visual acuity is about 20/300 at 4 months and progressively improves.

#### CHILDREN

- Epicanthal folds, common in individuals of Asian cultures, may cover the medial canthus and cause eyes to appear misaligned. Epicanthal folds may also be seen in young children of any race before the bridge of the nose begins to elevate.
- Preschool children's acuity can be checked with picture cards or the Snellen E chart. Acuity should approach 20/20 by 6 years of age.
- A cover test and the corneal light reflex (Hirschberg) test should be conducted on young children to detect misalignment early and prevent amblyopia.
- Always perform the acuity test with glasses on if a child has prescription lenses.

- Children should be tested for color vision deficit. From 8% to 10% of Caucasian males and from 0.5% to 1% of Caucasian females have this deficit; it is much less common in non-Caucasian children. The Ishihara or Hardy-Rand-Rittler test can be used.

#### OLDER ADULTS

##### Visual Acuity

- Visual acuity decreases as the lens of the eye ages and becomes more opaque and loses elasticity.
- The ability of the iris to accommodate to darkness and dim light diminishes.
- Peripheral vision diminishes.
- The adaptation to light (glare) and dark decreases.
- Accommodation to far objects often improves, but accommodation to near objects decreases.
- Color vision declines; older people are less able to perceive purple colors and to discriminate pastel colors.
- Many older adults wear corrective lenses; they are most likely to have hyperopia. Visual changes are due to loss of elasticity (presbyopia) and transparency of the lens.

**LIFESPAN CONSIDERATIONS** Assessing the Eyes and Vision—*continued***External Eye Structures**

- The skin around the orbit of the eye may darken.
  - The eyeball may appear sunken because of the decrease in orbital fat.
  - Skinfolds of the upper lids may seem more prominent, and the lower lids may sag.
  - The eyes may appear dry and dull because of the decrease in tear production from the lacrimal glands.
  - A thin, grayish white arc or ring (*arcus senilis*) appears around part or all of the cornea. It results from an accumulation of a lipid substance on the cornea. The cornea tends to cloud with age.
- The iris may appear pale with brown discolorations as a result of pigment degeneration.
  - The conjunctiva of the eye may appear paler than that of younger adults and may take on a slightly yellow appearance because of the deposition of fat.
  - Pupil reaction to light and accommodation is normally symmetrically equal but may be less brisk.
  - The pupils can appear smaller in size, unequal, and irregular in shape because of sclerotic changes in the iris.

**Home Care Considerations** Assessing the Eyes and Vision**PATIENT-CENTERED CARE**

- When making a home visit, take your equipment and charts with you. Also include a tape measure to lay out the 6 meters (20 feet) needed for distance vision testing.
- Use the assessment as an opportunity to reinforce proper eye care and need for regular vision testing.

**BOX 30-6** Performing Selected Vision Tests**LIGHT PERCEPTION (LP)**

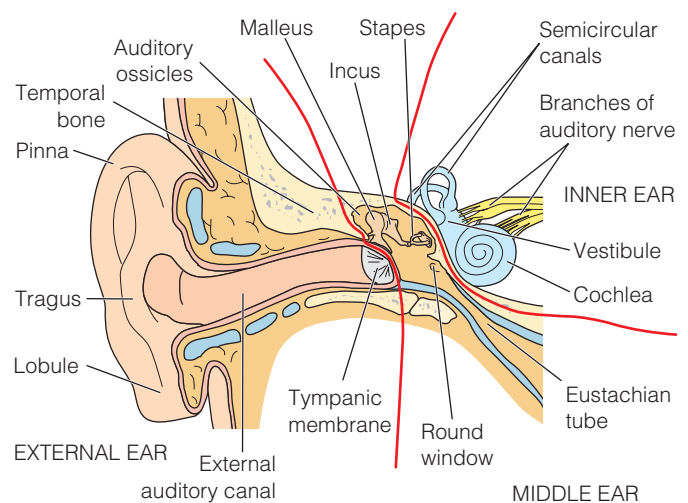
Shine a penlight into the client's eye from a lateral position, and then turn the light off. Ask the client to tell you when the light is on or off. If the client knows when the light is on or off, the client has light perception, and the vision is recorded as "LP."

**HAND MOVEMENTS (H/M)**

Hold your hand 30 cm (1 ft) from the client's face and move it slowly back and forth, stopping it periodically. Ask the client to tell you when your hand stops moving. If the client knows when your hand stops moving, record the vision as "H/M 1 ft."

**COUNTING FINGERS (C/F)**

Hold up some of your fingers 30 cm (1 ft) from the client's face, and ask the client to count your fingers. If the client can do so, note on the vision record "C/F 1 ft."



**Figure 30-15** ■ Anatomic structures of the external, middle, and inner ear.

**Ears and Hearing**

Assessment of the ear includes direct inspection and palpation of the external ear, inspection of the internal parts of the ear by an **otoscope** (instrument for examining the interior of the ear, especially the eardrum, consisting essentially of a magnifying lens and a light), and determination of auditory acuity. The ear is usually assessed during an initial physical examination; periodic reassessments may be necessary for long-term clients or those with hearing problems. In some practice settings, only advanced practice nurses perform otoscopic examinations.

The ear is divided into three parts: external ear, middle ear, and inner ear. Many of the structures discussed next are illustrated in Figure 30-15 ■. The external ear includes the **auricle** or **pinna**, the external auditory canal, and the **tympanic membrane**, or

eardrum. Landmarks of the auricle include the **lobule** (earlobe), **helix** (the posterior curve of the auricle's upper aspect), **antihelix** (the anterior curve of the auricle's upper aspect), **tragus** (the cartilaginous protrusion at the entrance to the ear canal), **triangular fossa** (a depression of the antihelix), and **external auditory meatus** (the entrance to the ear canal). Although not part of the ear, the **mastoid**, a bony prominence behind the ear, is another important landmark. The external ear canal is curved, is about 2.5 cm (1 in.) long in the adult, and ends at the tympanic membrane. It is covered with skin that has many fine hairs, glands, and nerve endings. The glands secrete **cerumen** (earwax), which lubricates and protects the canal.

The curvature of the external ear canal differs with age. In the infant and toddler, the canal has an upward curvature. By age 3, the ear canal assumes the more downward curvature of adulthood.

The middle ear is an air-filled cavity that starts at the tympanic membrane and contains three **ossicles** (bones of sound transmission): the **malleus** (hammer), the **incus** (anvil), and the **stapes** (stirrups). The **eustachian tube**, another part of the middle ear, connects the middle ear to the nasopharynx. The tube stabilizes the air pressure between the external atmosphere and the middle ear, thus preventing rupture of the tympanic membrane and discomfort produced by marked pressure differences.

The inner ear contains the **cochlea**, a seashell-shaped structure essential for sound transmission and hearing, and the **vestibule** and **semicircular canals**, which contain the organs of equilibrium.

Sound transmission and hearing are complex processes. In brief, sound can be transmitted by air conduction or bone conduction. Air-conducted transmission occurs by this process:

1. A sound stimulus enters the external canal and reaches the tympanic membrane.
2. The sound waves vibrate the tympanic membrane and reach the ossicles.
3. The sound waves travel from the ossicles to the opening in the inner ear (oval window).
4. The cochlea receives the sound vibrations.
5. The stimulus travels to the auditory nerve (the eighth cranial nerve) and the cerebral cortex.

Bone-conducted sound transmission occurs when skull bones transport the sound directly to the auditory nerve.

Audiometric evaluations, which measure hearing at various decibels, are recommended for children and older adults. A common hearing deficit with age is loss of ability to hear high-frequency sounds, such as *f*, *s*, *sh*, and *ph*. This neurosensory hearing deficit does not respond well to use of a hearing aid.

**Conductive hearing loss** is the result of interrupted transmission of sound waves through the outer and middle ear structures. Possible causes are a tear in the tympanic membrane or an obstruction, due to swelling or other causes, in the auditory canal. **Sensorineural hearing loss** is the result of damage to the inner ear, the auditory nerve, or the hearing center in the brain. **Mixed hearing loss** is a combination of conduction and sensorineural loss. Skill 30–7 describes how to assess the ears and hearing.

## Assessing the Ears and Hearing

### PLANNING

It is important to conduct the ear and hearing examination in an area that is quiet. In addition, the location should allow the client to be positioned sitting or standing at the same level as the nurse.

### DELEGATION

Due to the substantial knowledge and skill required, assessment of the ears and hearing is not delegated to UAP. However, many aspects are observed during usual care and may be recorded by individuals other than the nurse. Abnormal findings must be validated and interpreted by the nurse.

### IMPLEMENTATION

#### Performance

1. Prior to performing the procedure, introduce self and verify the client's identity using agency protocol. Explain to the client what you are going to do, why it is necessary, and how he or she can participate. Discuss how the results will be used in planning further care or treatments.
2. Perform hand hygiene and observe other appropriate infection prevention procedures.
3. Provide for client privacy.
4. Inquire if the client has any history of the following: family history of hearing problems or loss; presence of ear problems or pain; medication history, especially if there are complaints of ringing in the ears (tinnitus); hearing difficulty: its onset, factors contributing to it, and how it interferes with activities of daily living; use of a corrective hearing device: when and from whom it was obtained.
5. Position the client comfortably, seated if possible.

### Equipment

- Otoscope with several sizes of ear specula
- Tuning fork

### INTERPROFESSIONAL PRACTICE

Assessing the ears and hearing are within the scope of practice for many health care providers other than nurses. For example, audiologists and physician assistants may check the client's hearing. Although these providers may verbally communicate their findings and plan to other health care team members, the nurse must also know where to locate their documentation in the client's medical record.

## Assessing the Ears and Hearing—continued

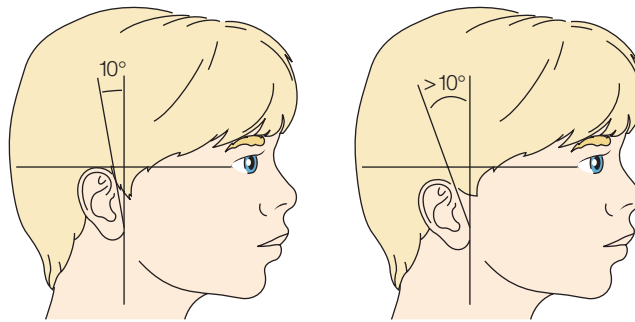
| Assessment | Normal Findings | Deviations from Normal |
|------------|-----------------|------------------------|
|------------|-----------------|------------------------|

### AURICLES

6. Inspect the auricles for color, symmetry of size, and position. To inspect position, note the level at which the superior aspect of the auricle attaches to the head in relation to the eye.

Color same as facial skin  
Symmetrical  
Auricle aligned with outer canthus of eye, about 10°, from vertical ❶

Bluish color of earlobes (e.g., cyanosis); pallor (e.g., frostbite); excessive redness (inflammation or fever)  
Asymmetry  
Low-set ears (associated with a congenital abnormality, such as Down syndrome)



Normal alignment

Low-set ears and deviation in alignment

❶ Alignment of the ears.

7. Palpate the auricles for texture, elasticity, and areas of tenderness.

- Gently pull the auricle upward, downward, and backward.
- Fold the pinna forward (it should recoil).
- Push in on the tragus.
- Apply pressure to the mastoid process.

Mobile, firm, and not tender; pinna recoils after it is folded

Lesions (e.g., cysts); flaky, scaly skin (e.g., seborrhea); tenderness when moved or pressed (may indicate inflammation or infection of external ear)

### EXTERNAL EAR CANAL AND TYMPANIC MEMBRANE

8. Inspect the external ear canal for cerumen, skin lesions, pus, and blood.

Distal third contains hair follicles and glands  
Dry cerumen, grayish-tan color; or sticky, wet cerumen in various shades of brown

Redness and discharge  
Scaling  
Excessive cerumen obstructing canal

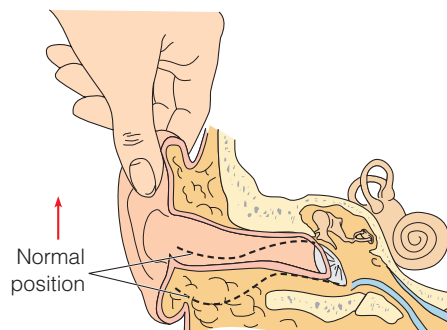
9. Visualize the tympanic membrane using an otoscope.

- Attach a speculum to the otoscope. Use the largest diameter that will fit the ear canal without causing discomfort.

**Rationale:** This achieves maximum vision of the entire ear canal and tympanic membrane.

- Tip the client's head away from you, and straighten the ear canal. For an adult, straighten the ear canal by pulling the pinna up and back. ❷

**Rationale:** Straightening the ear canal facilitates vision of the ear canal and the tympanic membrane.



❷ Straightening the ear canal of an adult by pulling the pinna up and back.

## Assessing the Ears and Hearing—continued

## Assessment

## Normal Findings

## Deviations from Normal

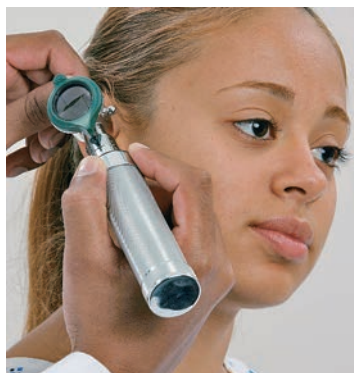- Hold the otoscope either (a) right side up, with your fingers between the otoscope handle and the client's head, or (b) upside down, with your fingers and the ulnar surface of your hand against the client's head. **3**

**Rationale:** This stabilizes the head and protects the eardrum and canal from injury if a quick head movement occurs.

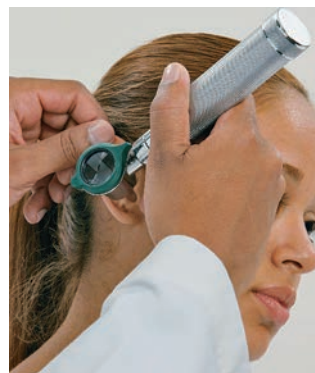- Gently insert the tip of the otoscope into the ear canal, avoiding pressure by the speculum against either side of the ear canal.

**Rationale:** The inner two thirds of the ear canal is bony; if the speculum is pressed against either side, the client will experience discomfort.

- 10.** Inspect the tympanic membrane for color and gloss.



**3** Inserting an otoscope.



Pearly gray color, semitransparent

Pink to red, some opacity  
Yellow-amber  
White  
Blue or deep red  
Dull surface

## GROSS HEARING ACUITY TESTS

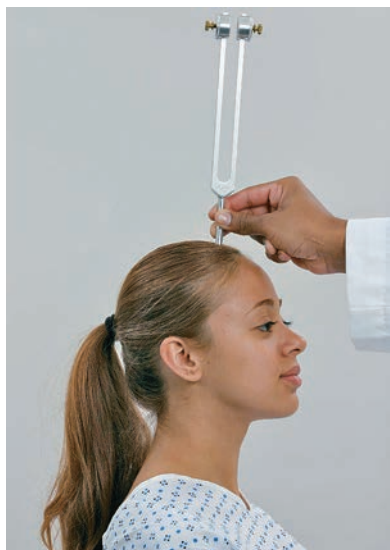- 11.** Assess client's response to normal voice tones. If client has difficulty hearing the normal voice, proceed with the following tests.
- 11A.** Perform the whisper test to assess high-frequency hearing.
- Have the client occlude one ear. Out of the client's sight, at a distance of 0.3 to 0.6 m (1 to 2 ft), whisper a simple phrase such as "The weather is hot today."
  - Ask the client to repeat the phrase.
  - Repeat with the other ear using a different phrase.
- 11B. Tuning Fork Tests.** Perform Weber's test to assess bone conduction by examining the lateralization (sideward transmission) of sounds.
- Hold the tuning fork at its base. Activate it by tapping the fork gently against the back of your hand near the knuckles or by stroking the fork between your thumb and index fingers. It should be made to ring softly.
  - Place the base of the vibrating tuning fork on top of the client's head **4** and ask where the client hears the noise.

Conduct the Rinne test to compare air conduction to bone conduction.

Normal voice tones audible

Able to repeat the phrases correctly in both ears

Sound is heard in both ears or is localized at the center of the head (Weber negative)





Normal voice tones not audible (e.g., requests nurse to repeat words or statements, leans toward the speaker, turns the head, cups the ears, or speaks in loud tone of voice)  
Unable to repeat the phrases in one or both ears

Sound is heard better in impaired ear, indicating a bone-conductive hearing loss; or sound is heard better in ear without a problem, indicating a sensorineural disturbance (Weber positive)

**4** Placing the base of the tuning fork on the client's skull (Weber's test).

## Assessing the Ears and Hearing—continued

| Assessment                                                                                                                                                                                                                                                                                                                                                                                                                                                                                                                                                                                                                                                                                                           | Normal Findings                                                                                                                                                                                                                 | Deviations from Normal                                                                                                                                                                                                                                                                          |
|----------------------------------------------------------------------------------------------------------------------------------------------------------------------------------------------------------------------------------------------------------------------------------------------------------------------------------------------------------------------------------------------------------------------------------------------------------------------------------------------------------------------------------------------------------------------------------------------------------------------------------------------------------------------------------------------------------------------|---------------------------------------------------------------------------------------------------------------------------------------------------------------------------------------------------------------------------------|-------------------------------------------------------------------------------------------------------------------------------------------------------------------------------------------------------------------------------------------------------------------------------------------------|
| <ul style="list-style-type: none"> <li>Hold the handle of the activated tuning fork on the mastoid process of one ear <b>5</b> A until the client states that the vibration can no longer be heard.</li> <li>Immediately hold the still vibrating fork prongs in front of the client's ear canal. <b>5</b> B Push aside the client's hair if necessary. Ask whether the client now hears the sound. Sound conducted by air is heard more readily than sound conducted by bone. The tuning fork vibrations conducted by air are normally heard longer.</li> </ul> <p>12. Document findings in the client record using printed or electronic forms or checklists supplemented by narrative notes when appropriate.</p> | <p>Air-conducted (AC) hearing is greater than bone-conducted (BC) hearing, i.e., <math>AC &gt; BC</math> (positive Rinne)</p>  <p><b>A</b></p> | <p>Bone conduction time is equal to or longer than the air conduction time, i.e., <math>BC &gt; AC</math> or <math>BC = AC</math> (negative Rinne; indicates a conductive hearing loss)</p>  <p><b>B</b></p> |

**5** Rinne test tuning fork placement: A, base of the tuning fork on the mastoid process; B, tuning fork prongs placed in front of client's ear.

## EVALUATION

- Perform a detailed follow-up examination of other systems based on findings that deviated from expected or normal for the client. Relate findings to previous assessment data if available.
- Report deviations from expected or normal findings to the primary care provider.

## LIFESPAN CONSIDERATIONS Assessing the Ears and Hearing

## INFANTS

- To assess gross hearing, ring a bell from behind the infant or have the parent call the child's name to check for a response. Newborns will quiet to the sound and may open their eyes wider. By 3 to 4 months of age, the child will turn head and eyes toward the sound.
- All newborns should be assessed for hearing prior to discharge from the hospital. Most states and many countries have a law or regulation requiring universal newborn hearing screening.

## CHILDREN

- To inspect the external canal and tympanic membrane in children less than 3 years old, pull the pinna down and back. Insert the speculum only 0.6 to 1.25 cm (0.25 to 0.5 in.).
- Perform routine hearing checks and follow up on abnormal results. In addition to congenital or infection-related causes of hearing loss, noise-induced hearing loss is becoming more common in adolescents and young adults as a result of exposure to loud music and prolonged use of headsets at extremely loud volumes (Weichbold, Holzer, Newesely, & Stephan, 2012).

Teach that music loud enough to prevent hearing a normal conversation can damage hearing.

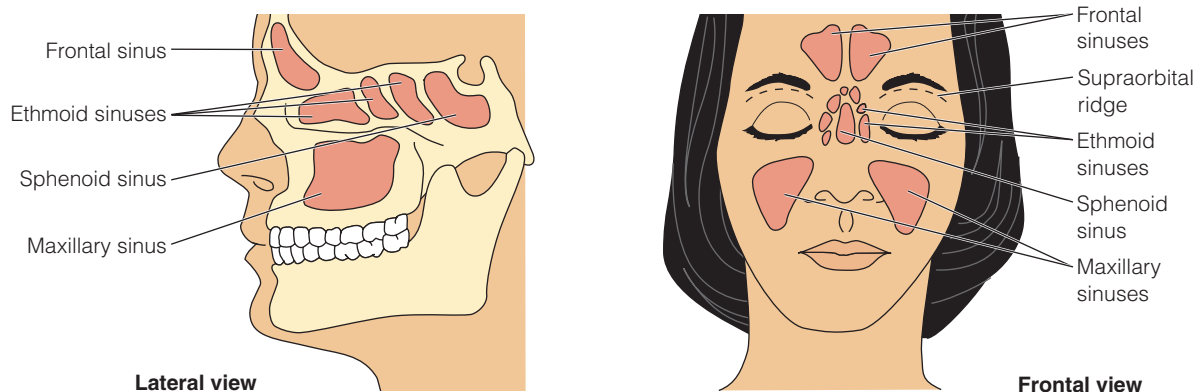
## OLDER ADULTS

- The skin of the ear may appear dry and be less resilient because of the loss of connective tissue.
- Increased coarse and wirelike hair growth occurs along the helix, antihelix, and tragus.
- The pinna increases in both width and length, and the earlobe elongates.
- Earwax is drier.
- The tympanic membrane is more translucent and less flexible. The intensity of the light reflex may diminish slightly.
- Sensorineural hearing loss occurs.
- Generalized hearing loss (presbycusis) occurs in all frequencies, although the first symptom is the loss of high-frequency sounds: the *f*, *s*, *sh*, and *ph* sounds. To such individuals, conversation can be distorted and result in what appears to be inappropriate or confused behavior.

## Home Care Considerations Assessing the Ears and Hearing

## PATIENT-CENTERED CARE

- Ensure that the examination is conducted in a quiet place. In particular, older adults will have difficulty accurately reporting results of hearing tests if excessive noise is present.
- If necessary, ask the adult present with an infant or child to assist in holding the child still during the examination.



**Figure 30-16** ■ The facial sinuses.

## Nose and Sinuses

A nurse can inspect the nasal passages very simply with a flashlight. However, a nasal speculum and a penlight or an otoscope with a nasal attachment facilitates examination of the nasal cavity.

Assessment of the nose includes inspection and palpation of the external nose (the upper third of the nose is bone; the remainder is cartilage); patency of the nasal cavities; and inspection of the nasal cavities.

If the client reports difficulty or abnormality in smell, the nurse may test the client's olfactory sense by asking the client to identify common odors such as coffee or mint. This is done by asking the client to close the eyes and placing vials containing the scent under the client's nose.

The nurse also inspects and palpates the facial sinuses (Figure 30-16 ■). Skill 30-8 describes how to assess the nose and sinuses.

## Assessing the Nose and Sinuses

### PLANNING DELEGATION

Due to the substantial knowledge and skill required, assessment of the nose and sinuses is not delegated to UAP. However, many aspects are observed during usual care and may be recorded by individuals other than the nurse. Abnormal findings must be validated and interpreted by the nurse.

#### Equipment

- Nasal speculum
- Flashlight/penlight

### IMPLEMENTATION

#### Performance

1. Prior to performing the procedure, introduce self and verify the client's identity using agency protocol. Explain to the client what you are going to do, why it is necessary, and how he or she can participate. Discuss how the results will be used in planning further care or treatments.
2. Perform hand hygiene and observe other appropriate infection prevention procedures.

### INTERPROFESSIONAL PRACTICE

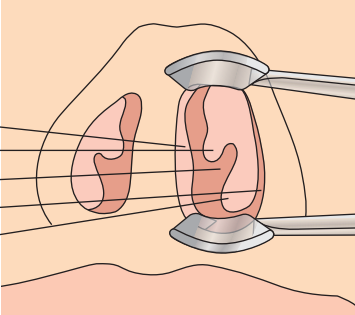
Assessing the nose and sinuses may be within the scope of practice for health care providers other than nurses, such as physician assistants. Although these providers may verbally communicate their findings and plan to other health care team members, the nurse must also know where to locate their documentation in the client's medical record.

3. Provide for client privacy.
4. Inquire if the client has any history of the following: allergies, difficulty breathing through the nose, sinus infections, injuries to nose or face, nosebleeds; medications taken; changes in sense of smell.
5. Position the client comfortably, seated if possible.

| Assessment                                                                                                                  | Normal Findings                                                    | Deviations from Normal                                                                       |
|-----------------------------------------------------------------------------------------------------------------------------|--------------------------------------------------------------------|----------------------------------------------------------------------------------------------|
| <b>NOSE</b>                                                                                                                 |                                                                    |                                                                                              |
| 6. Inspect the external nose for any deviations in shape, size, or color and flaring or discharge from the nares.           | Symmetric and straight<br>No discharge or flaring<br>Uniform color | Asymmetric<br>Discharge from nares<br>Localized areas of redness or presence of skin lesions |
| 7. Lightly palpate the external nose to determine any areas of tenderness, masses, and displacements of bone and cartilage. | Not tender; no lesions                                             | Tenderness on palpation; presence of lesions                                                 |



## Assessing the Nose and Sinuses—continued

| Assessment                                                                                                                                                                                                                                                                                                                                                                                                                                                                                                                                                                                                                                                                                                                                                                                                                                                                                                                                  | Normal Findings                                                                                                                                                                                                                                                                                                                          | Deviations from Normal                                                                                                                                                                                        |
|---------------------------------------------------------------------------------------------------------------------------------------------------------------------------------------------------------------------------------------------------------------------------------------------------------------------------------------------------------------------------------------------------------------------------------------------------------------------------------------------------------------------------------------------------------------------------------------------------------------------------------------------------------------------------------------------------------------------------------------------------------------------------------------------------------------------------------------------------------------------------------------------------------------------------------------------|------------------------------------------------------------------------------------------------------------------------------------------------------------------------------------------------------------------------------------------------------------------------------------------------------------------------------------------|---------------------------------------------------------------------------------------------------------------------------------------------------------------------------------------------------------------|
| <p>8. Determine patency of both nasal cavities. Ask the client to close the mouth, exert pressure on one naris, and breathe through the opposite naris. Repeat the procedure to assess patency of the opposite naris.</p> <p>9. Inspect the nasal cavities using a flashlight or a nasal speculum.</p> <ul style="list-style-type: none"> <li>Hold the speculum in your right hand to inspect the client's left nostril and your left hand to inspect the client's right nostril.</li> <li>Tip the client's head back.</li> <li>Facing the client, insert the tip of the speculum about 1 cm (0.4 in.). Care must be taken to avoid pressure on the sensitive nasal septum.</li> <li>Inspect the lining of the nares and the integrity and the position of the nasal septum. ❶</li> </ul> <p>10. Observe for the presence of redness, swelling, growths, and discharge.</p> <p>11. Inspect the nasal septum between the nasal chambers.</p> | <p>Air moves freely as the client breathes through the nares</p>  <p>❶ The nasal septum, inferior and middle turbinates of the nasal passage.</p> <p>Mucosa pink<br/>Clear, watery discharge<br/>No lesions<br/>Nasal septum intact and in midline</p> | <p>Air movement is restricted in one or both nares</p> <p>Mucosa red, edematous<br/>Abnormal discharge (e.g., pus)<br/>Presence of lesions (e.g., polyps)<br/>Septum deviated to the right or to the left</p> |
| <p><b>FACIAL SINUSES</b></p> <p>12. Palpate the maxillary and frontal sinuses for tenderness. Not tender Tenderness in one or more sinuses</p> <p>13. Document findings in the client record using printed or electronic forms or checklists supplemented by narrative notes when appropriate.</p>                                                                                                                                                                                                                                                                                                                                                                                                                                                                                                                                                                                                                                          |                                                                                                                                                                                                                                                                                                                                          |                                                                                                                                                                                                               |
| <p><b>EVALUATION</b></p> <ul style="list-style-type: none"> <li>Perform a detailed follow-up examination of other systems based on findings that deviated from expected or normal for the client. Relate findings to previous assessment data if available.</li> <li>Report deviations from expected or normal findings to the primary care provider.</li> </ul>                                                                                                                                                                                                                                                                                                                                                                                                                                                                                                                                                                            |                                                                                                                                                                                                                                                                                                                                          |                                                                                                                                                                                                               |

### LIFESPAN CONSIDERATIONS Assessing the Nose and Sinuses

#### INFANTS

- A speculum is usually not necessary to examine the septum, turbinates, and vestibule. Instead, push the tip of the nose upward with the thumb and shine a light into the nares.
- Ethmoid and maxillary sinuses are present at birth; frontal sinuses begin to develop by 1 to 2 years of age; and sphenoid sinuses develop later in childhood. Infants and young children have fewer sinus problems than older children and adolescents.

#### CHILDREN

- A speculum is usually not necessary to examine the septum, turbinates, and vestibule. It might cause the child to be apprehensive. Instead, push the tip of the nose upward with the thumb and shine a light into the nares.

- Ethmoid sinuses continue to develop until age 12.
- Cough and runny nose are the most common signs of sinusitis in preadolescent children.
- Adolescents may have headaches, facial tenderness, and swelling, similar to the signs seen in adults.

#### OLDER ADULTS

- The sense of smell markedly diminishes because of a decrease in the number of olfactory nerve fibers and atrophy of the remaining fibers. Older adults are less able to identify and discriminate odors.
- Nosebleeds may result from hypertensive disease or other arterial vessel changes.

## Mouth and Oropharynx

The mouth and oropharynx are composed of a number of structures: lips, oral mucosa, the tongue and floor of the mouth, teeth and gums, hard and soft palate, uvula, salivary glands, tonsillar pillars, and tonsils. Anatomic structures of the mouth are shown in Figure 30-17. By age 25, most people have all their permanent teeth. For information about structures of the teeth, see Chapter 33.

Normally, three pairs of salivary glands empty into the oral cavity: the parotid, submandibular, and sublingual glands. The *parotid gland* is the largest and empties through Stensen's duct opposite the second molar. The *submandibular gland* empties through Wharton's duct, which is situated on either side of the frenulum on the floor of the mouth. The *sublingual salivary gland* lies in the floor of the mouth and has numerous openings.

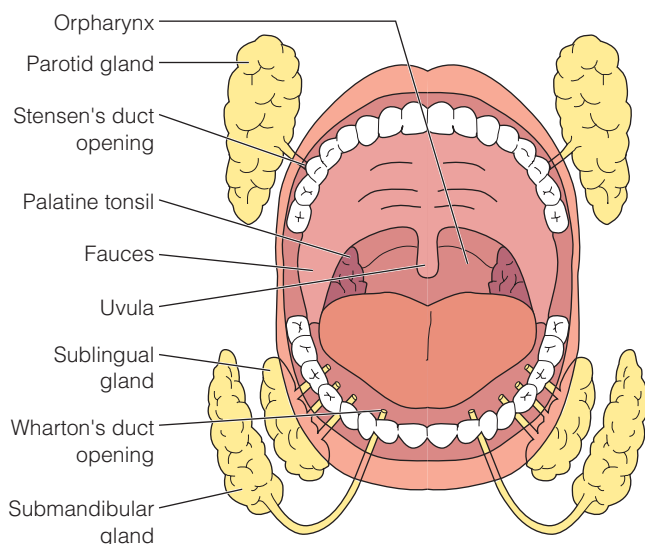


Figure 30–17 ■ Anatomic structures of the mouth.

Dental **caries** (cavities) and **periodontal disease** (or **pyorrhea**) are the two problems that most frequently affect the teeth. Both problems are commonly associated with plaque and tartar deposits. **Plaque** is an invisible soft film that adheres to the enamel surface of teeth; it consists of bacteria, molecules of saliva, and remnants of epithelial cells and leukocytes. When plaque is unchecked, tartar (dental calculus) forms. **Tartar** is a visible, hard deposit of plaque and dead bacteria that forms at the gum lines. Tartar buildup can alter the fibers that attach the teeth to the gum and eventually disrupt bone tissue. Periodontal disease is characterized by **gingivitis** (red, swollen gingiva [gum]), bleeding, receding gum lines, and the formation of pockets between the teeth and gums. In advanced periodontal disease, the teeth are loose and pus is evident when the gums are pressed.

Other problems nurses may see are **glossitis** (inflammation of the tongue), **stomatitis** (inflammation of the oral mucosa), and **parotitis** (inflammation of the parotid salivary gland). The accumulation of foul matter (food, microorganisms, and epithelial elements) on the teeth and gums is referred to as **sordes**. Skill 30–9 describes assessment of the mouth and oropharynx.

## Assessing the Mouth and Oropharynx

### PLANNING

If possible, arrange for the client to sit with the head against a firm surface such as a headrest or examination table. This makes it easier for the client to hold the head still during the examination.

### DELEGATION

Due to the substantial knowledge and skill required, assessment of the mouth and oropharynx is not delegated to UAP. However, many aspects are observed during usual care and may be recorded by individuals other than the nurse. Abnormal findings must be validated and interpreted by the nurse.

### IMPLEMENTATION

#### Performance

1. Prior to performing the procedure, introduce self and verify the client's identity using agency protocol. Explain to the client what you are going to do, why it is necessary, and how he or she can participate. Discuss how the results will be used in planning further care or treatments.
2. Perform hand hygiene and observe other appropriate infection prevention procedures.

### Equipment

- Clean gloves
- Tongue depressor
- 2×2 gauze pads
- Penlight

### INTERPROFESSIONAL PRACTICE

Assessing the mouth and oropharynx is within the scope of practice for many health care providers other than nurses, such as physician assistants. Although these providers may verbally communicate their findings and plan to other health care team members, the nurse must also know where to locate their documentation in the client's medical record.

3. Provide for client privacy.
4. Inquire if the client has any history of the following: routine pattern of dental care, last visit to dentist; length of time ulcers or other lesions have been present; denture discomfort; medications client is receiving.
5. Position the client comfortably, seated if possible.

### Assessment




### Normal Findings

### Deviations from Normal

#### LIPS AND BUCCAL MUCOSA

- |                                                                                                                                                                                                   |                                                                                                                                                                                          |                                                                                                                                                                                                                                                    |
|---------------------------------------------------------------------------------------------------------------------------------------------------------------------------------------------------|------------------------------------------------------------------------------------------------------------------------------------------------------------------------------------------|----------------------------------------------------------------------------------------------------------------------------------------------------------------------------------------------------------------------------------------------------|
| <p>6. Inspect the outer lips for symmetry of contour, color, and texture. Ask the client to purse the lips as if to whistle.</p>                                                                  | <p>Uniform pink color (darker, e.g., bluish hue, in Mediterranean groups and dark-skinned clients)<br/>Soft, moist, smooth texture<br/>Symmetry of contour<br/>Ability to purse lips</p> | <p>Pallor; cyanosis<br/>Blisters; generalized or localized swelling; fissures, crusts, or scales (may result from excessive moisture, nutritional deficiency, or fluid deficit)<br/>Inability to purse lips (may indicate facial nerve damage)</p> |
| <p>7. Inspect and palpate the inner lips and buccal mucosa for color, moisture, texture, and the presence of lesions.</p> <ul style="list-style-type: none"> <li>• Apply clean gloves.</li> </ul> | <p>Uniform pink color (freckled brown pigmentation in dark-skinned clients)</p>                                                                                                          | <p>Pallor; leukoplakia (white patches), red, bleeding</p>                                                                                                                                                                                          |

## Assessing the Mouth and Oropharynx—continued

| Assessment                                                                                                                                                                                                                                                                                                                                                                                                                                                                                                                                                                                                                                                                                                                                                                                                                                                                                                                                                                                                                                                                                                        | Normal Findings                                                                                                                                                                                                                                                                                                                                                      | Deviations from Normal                                                                                                                                                                                                                                                                                                                                                                                |
|-------------------------------------------------------------------------------------------------------------------------------------------------------------------------------------------------------------------------------------------------------------------------------------------------------------------------------------------------------------------------------------------------------------------------------------------------------------------------------------------------------------------------------------------------------------------------------------------------------------------------------------------------------------------------------------------------------------------------------------------------------------------------------------------------------------------------------------------------------------------------------------------------------------------------------------------------------------------------------------------------------------------------------------------------------------------------------------------------------------------|----------------------------------------------------------------------------------------------------------------------------------------------------------------------------------------------------------------------------------------------------------------------------------------------------------------------------------------------------------------------|-------------------------------------------------------------------------------------------------------------------------------------------------------------------------------------------------------------------------------------------------------------------------------------------------------------------------------------------------------------------------------------------------------|
| <ul style="list-style-type: none"> <li>Ask the client to relax the mouth, and, for better visualization, pull the lip outward and away from the teeth.</li> <li>Grasp the lip on each side between the thumb and index finger. ❶</li> </ul>                                                                                                                                                                                                                                                                                                                                                                                                                                                                                                                                                                                                                                                                                                                                                                                                                                                                       | <p>Moist, smooth, soft, glistening, and elastic texture (drier oral mucosa in older clients due to decreased salivation)</p>                                                                                                                                                        | <p>Excessive dryness<br/>Mucosal cysts; irritations from dentures; abrasions, ulcerations; nodules</p>                                                                                                                                                                                                                                                                                                |
| <b>TEETH AND GUMS</b>                                                                                                                                                                                                                                                                                                                                                                                                                                                                                                                                                                                                                                                                                                                                                                                                                                                                                                                                                                                                                                                                                             |                                                                                                                                                                                                                                                                                                                                                                      |                                                                                                                                                                                                                                                                                                                                                                                                       |
| <p>8. Inspect the teeth and gums while examining the inner lips and buccal mucosa.</p> <ul style="list-style-type: none"> <li>Ask the client to open the mouth. Using a tongue depressor, retract the cheek. ❷ View the surface buccal mucosa from top to bottom and back to front. A flashlight or penlight will help illuminate the surface. Repeat the procedure for the other side.</li> <li>Examine the back teeth. For proper vision of the molars, use the index fingers of both hands to retract the cheek. ❸ Ask the client to relax the lips and first close, then open, the jaw.<br/><b>Rationale:</b> <i>Closing the jaw assists in observation of tooth alignment and loss of teeth; opening the jaw assists in observation of dental fillings and caries.</i> Observe the number of teeth, tooth color, the state of fillings, dental caries, and tartar along the base of the teeth. Note the presence and fit of partial or complete dentures.</li> <li>Inspect the gums around the molars. Observe for bleeding, color, retraction (pulling away from the teeth), edema, and lesions.</li> </ul> | <p>32 adult teeth<br/>Smooth, white, shiny tooth enamel</p> <p>Pink gums (bluish or brown patches in dark-skinned clients)<br/>Moist, firm texture to gums</p> <p>No retraction of gums</p>   | <p>Missing teeth; ill-fitting dentures<br/>Brown or black discoloration of the enamel (may indicate staining or the presence of caries)<br/>Excessively red gums</p> <p>Spongy texture; bleeding; tenderness (may indicate periodontal disease)<br/>Receding, atrophied gums; swelling that partially covers the teeth</p>                                                                            |
| <p>9. Inspect the dentures. Ask the client to remove complete or partial dentures. Inspect their condition, noting in particular broken or worn areas.</p>                                                                                                                                                                                                                                                                                                                                                                                                                                                                                                                                                                                                                                                                                                                                                                                                                                                                                                                                                        | <p>Smooth, intact dentures</p>                                                                                                                                                                                                                                                                                                                                       | <p>Ill-fitting dentures; irritated and excoriated area under dentures</p>                                                                                                                                                                                                                                                                                                                             |
| <b>TONGUE/FLOOR OF THE MOUTH</b>                                                                                                                                                                                                                                                                                                                                                                                                                                                                                                                                                                                                                                                                                                                                                                                                                                                                                                                                                                                                                                                                                  |                                                                                                                                                                                                                                                                                                                                                                      |                                                                                                                                                                                                                                                                                                                                                                                                       |
| <p>10. Inspect the surface of the tongue for position, color, and texture. Ask the client to protrude the tongue.</p>                                                                                                                                                                                                                                                                                                                                                                                                                                                                                                                                                                                                                                                                                                                                                                                                                                                                                                                                                                                             | <p>Central position<br/>Pink color (some brown pigmentation on tongue borders in dark-skinned clients); moist; slightly rough; thin whitish coating<br/>Smooth, lateral margins; no lesions<br/>Raised papillae (taste buds)</p>                                                                                                                                     | <p>Deviated from center (may indicate damage to hypoglossal [12th cranial] nerve); excessive trembling<br/>Smooth red tongue (may indicate iron, vitamin B<sub>12</sub>, or vitamin B<sub>3</sub> deficiency)<br/>Dry, furry tongue (associated with fluid deficit), white coating (may be oral yeast infection)<br/>Nodes, ulcerations, discolorations (white or red areas); areas of tenderness</p> |

## Assessing the Mouth and Oropharynx—continued

| Assessment                                                                                                                                                                                                                                                                                                                                         | Normal Findings                                                                                                                                                                                | Deviations from Normal                                                                                                                                                                                                                                      |
|----------------------------------------------------------------------------------------------------------------------------------------------------------------------------------------------------------------------------------------------------------------------------------------------------------------------------------------------------|------------------------------------------------------------------------------------------------------------------------------------------------------------------------------------------------|-------------------------------------------------------------------------------------------------------------------------------------------------------------------------------------------------------------------------------------------------------------|
| 11. Inspect tongue movement. Ask the client to roll the tongue upward and move it from side to side.                                                                                                                                                                                                                                               | Moves freely; no tenderness                                                                                                                                                                    | Restricted mobility                                                                                                                                                                                                                                         |
| 12. Inspect the base of the tongue, the mouth floor, and the frenulum. Ask the client to place the tip of the tongue against the roof of the mouth.                                                                                                                                                                                                | Smooth tongue base with prominent veins                                                                                                                                                        | Swelling, ulceration                                                                                                                                                                                                                                        |
| <b>PALATES AND UVULA</b>                                                                                                                                                                                                                                                                                                                           |                                                                                                                                                                                                |                                                                                                                                                                                                                                                             |
| 13. Inspect the hard and soft palate for color, shape, texture, and the presence of bony prominences. Ask the client to open the mouth wide and tilt the head backward. Then, depress tongue with a tongue depressor as necessary, and use a penlight for appropriate visualization.                                                               | Light pink, smooth, soft palate<br>Lighter pink hard palate, more irregular texture                                                                                                            | Discoloration (e.g., jaundice or pallor)<br>Palates the same color<br>Irritations<br>Exostoses (bony growths) growing from the hard palate                                                                                                                  |
| 14. Inspect the uvula for position and mobility while examining the palates. To observe the uvula, ask the client to say “ah” so that the soft palate rises.                                                                                                                                                                                       | Positioned in midline of soft palate, rises during vocalization                                                                                                                                | Deviation to one side from tumor or trauma; immobility (may indicate damage to trigeminal [5th cranial] nerve or vagus [10th cranial] nerve)                                                                                                                |
| <b>OROPHARYNX AND TONSILS</b>                                                                                                                                                                                                                                                                                                                      |                                                                                                                                                                                                |                                                                                                                                                                                                                                                             |
| 15. Inspect the oropharynx for color and texture. Inspect one side at a time to avoid eliciting the gag response. To expose one side of the oropharynx, press a tongue depressor against the tongue on the same side about halfway back while the client tilts the head back and opens the mouth wide. Use a penlight for illumination, if needed. | Pink and smooth posterior wall                                                                                                                                                                 | Reddened or edematous; presence of lesions, plaques, or drainage                                                                                                                                                                                            |
| 16. Inspect the tonsils (behind the fauces) for color, discharge, and size.                                                                                                                                                                                                                                                                        | Pink and smooth<br>No discharge<br>Of normal size or not visible<br>• <i>Grade 1 (normal)</i> : The tonsils are behind the tonsillar pillars (the soft structures supporting the soft palate). | Inflamed<br>Presence of discharge<br>Swollen<br>• <i>Grade 2</i> : The tonsils are between the pillars and the uvula.<br>• <i>Grade 3</i> : The tonsils touch the uvula.<br>• <i>Grade 4</i> : One or both tonsils extend to the midline of the oropharynx. |
| 17. Remove and discard gloves.<br>• Perform hand hygiene.                                                                                                                                                                                                                                                                                          |                                                                                                                                                                                                |                                                                                                                                                                                                                                                             |
| 18. Document findings in the client record using printed or electronic forms or checklists supplemented by narrative notes when appropriate.                                                                                                                                                                                                       |                                                                                                                                                                                                |                                                                                                                                                                                                                                                             |

**EVALUATION**

- Perform a detailed follow-up examination of other systems based on findings that deviated from expected or normal for the client. Relate findings to previous assessment data if available.
- Report deviations from expected or normal findings to the primary care provider.

**LIFESPAN CONSIDERATIONS** Assessing the Mouth and Oropharynx**INFANTS**

- Inspect the palate and uvula for a cleft. A bifid (forked) uvula may indicate an unsuspected cleft palate (i.e., a cleft in the cartilage that is covered by skin).
- Newborns may have a pearly white nodule on their gums, which resolves without treatment.
- The first teeth erupt at about 6 to 7 months of age. Assess for dental hygiene; parents should cleanse the infant's teeth daily with a soft cloth or soft toothbrush.

- Fluoride supplements should be given by 6 months if the child's drinking water contains less than 0.3 parts per million (ppm) fluoride.
- Children should see a dentist by 1 year of age.

**CHILDREN**

- Tooth development should be appropriate for age.
- White spots on the teeth may indicate excessive fluoride ingestion.

**LIFESPAN CONSIDERATIONS** Assessing the Mouth and Oropharynx—*continued*

- Drooling is common up to 2 years of age.
- The tonsils are normally larger in children than in adults and commonly extend beyond the palatine arch until the age of 11 or 12 years.

**OLDER ADULTS**

- The oral mucosa may be drier than that of younger people because of decreased salivary gland activity. Decreased salivation occurs in older people taking prescribed medications such as antidepressants, antihistamines, decongestants, diuretics, antihypertensives, tranquilizers, antispasmodics, and antineoplastics. Extreme dryness is associated with dehydration.
- Some receding of the gums occurs, giving an appearance of increased toothiness.
- Taste sensations diminish. Sweet and salty tastes are lost first. Older people may add more salt and sugar to food than they did when they were younger. Diminished taste sensation is due to atrophy of the taste buds and a decreased sense of smell. It indicates diminished function of the fifth and seventh cranial nerves.
- Tiny purple or bluish black swollen areas (varicosities) under the tongue, known as *caviar spots*, are not uncommon.
- The teeth may show signs of staining, erosion, chipping, and abrasions due to loss of dentin. Medicare does not cover dental cleanings or treatments. Older adults with limited incomes may delay or avoid professional dental care.
- Tooth loss occurs as a result of dental disease but is preventable with good dental hygiene.
- Check that full or removable partial dentures fit properly. Bone loss and weight loss or gain can change the way these prosthetics fit.
- The gag response may be slightly sluggish.
- Older adults who are homebound or are in long-term care facilities often have teeth or dentures in need of repair, due to the difficulty of obtaining dental care in these situations. Do a thorough assessment of missing teeth and those in need of repair, whether they are natural teeth or dentures.

**Home Care Considerations** Assessing the Mouth and Oropharynx**PATIENT-CENTERED CARE**

- Although clients may be sensitive to discussion of their personal hygiene practices, use the assessment as an opportunity to provide teaching regarding appropriate oral and

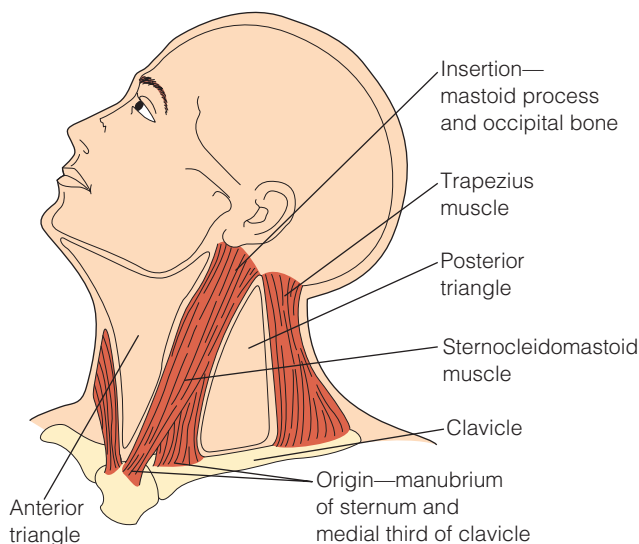
dental care for the entire family. Refer clients to a dentist if indicated.

**NECK**

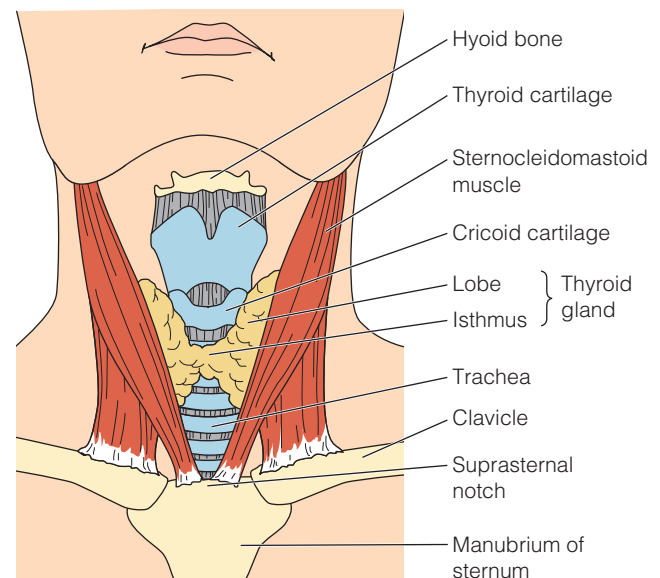
Examination of the neck includes the muscles, lymph nodes, trachea, thyroid gland, carotid arteries, and jugular veins. Areas of the neck are defined by the sternocleidomastoid muscles, which divide each side of the neck into two triangles: the anterior and posterior (Figure 30–18 ■). The trachea, thyroid gland, anterior cervical nodes, and carotid artery lie within the anterior triangle (Figure 30–19 ■); the carotid artery runs parallel and anterior to the sternocleidomastoid muscle. The posterior lymph nodes lie within the posterior triangle (Figure 30–20 ■).

Each sternocleidomastoid muscle extends from the upper sternum and the medial third of the clavicle to the mastoid process of the temporal bone behind the ear. These muscles turn and laterally flex the head. Each trapezius muscle extends from the occipital bone of the skull to the lateral third of the clavicle. These muscles draw the head to the side and back, elevate the chin, and elevate the shoulders to shrug them.

Lymph nodes in the neck that collect lymph from the head and neck structures are grouped serially and referred to as *chains*. See Figure 30–20 and Table 30–6. The deep cervical



**Figure 30–18** ■ Major muscles of the neck.



**Figure 30–19** ■ Structures of the neck.

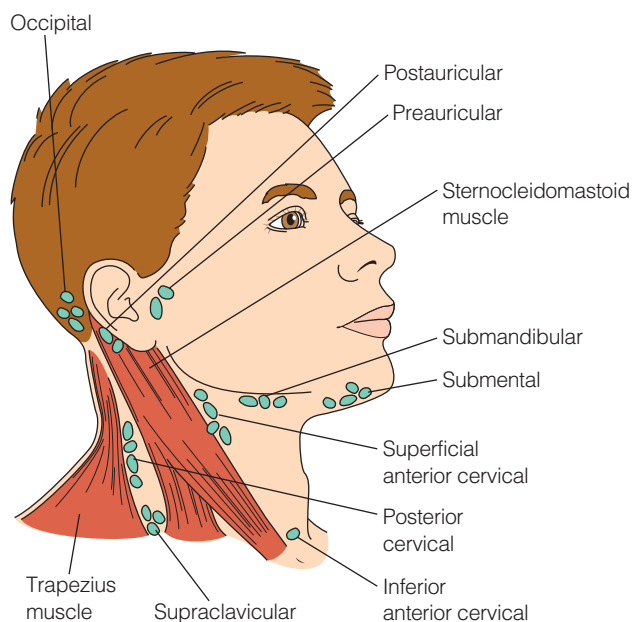


Figure 30–20 ■ Lymph nodes of the neck.

chain is not shown in Figure 30–20 because it lies beneath the sternocleidomastoid muscle. Skill 30–10 describes how to assess the neck.

## THORAX AND LUNGS

Assessing the thorax and lungs is frequently critical to assessing the client's oxygenation status (also see Chapter 50 ∞). Changes in the respiratory system can occur slowly or quickly. In clients with chronic obstructive pulmonary disease (COPD), such as chronic bronchitis, emphysema, and asthma, changes are frequently gradual. The onset of conditions such as pneumonia or pulmonary embolus is generally more acute or sudden.

### Chest Landmarks

Before beginning the assessment, the nurse must be familiar with a series of imaginary lines on the chest wall and be able to locate the position of each rib and some spinous processes. These landmarks help the nurse to identify the position of underlying organs (e.g., lobes of the lung) and to record abnormal assessment findings.

TABLE 30–6 Lymph Nodes of the Head and Neck

| Node Center                               | Location                                                                                   | Area Drained                                                                                |
|-------------------------------------------|--------------------------------------------------------------------------------------------|---------------------------------------------------------------------------------------------|
| <b>HEAD</b>                               |                                                                                            |                                                                                             |
| Occipital                                 | At the posterior base of the skull                                                         | The occipital region of the scalp and the deep structures of the back of the neck           |
| Postauricular (mastoid)                   | Behind the auricle of the ear or in front of the mastoid process                           | The parietal region of the head and part of the ear                                         |
| Preauricular                              | In front of the tragus of the ear                                                          | The forehead and upper face                                                                 |
| <b>FLOOR OF MOUTH</b>                     |                                                                                            |                                                                                             |
| Submandibular (submaxillary)              | Along the medial border of the mandible, halfway between the angle of the jaw and the chin | The chin, upper lip, cheek, nose, teeth, eyelids, part of the tongue and floor of the mouth |
| Submental                                 | Behind the tip of the mandible in the midline, under the chin                              | The anterior third of the tongue, gums, and floor of the mouth                              |
| <b>NECK</b>                               |                                                                                            |                                                                                             |
| Superficial anterior cervical (tonsillar) | Along the mandible, anterior to the sternocleidomastoid muscle                             | The skin and neck                                                                           |
| Posterior cervical                        | Along the anterior aspect of the trapezius muscle                                          | The posterior and lateral regions of the neck, occiput, and mastoid                         |
| Deep cervical                             | Under the sternocleidomastoid muscle                                                       | The larynx, thyroid gland, trachea, and upper part of the esophagus                         |
| Supraclavicular                           | Above the clavicle, in the angle between the clavicle and the sternocleidomastoid muscle   | The lateral regions of the neck and lungs                                                   |

## Assessing the Neck

### PLANNING DELEGATION

Due to the substantial knowledge and skill required, assessment of the neck is not delegated to UAP. However, many aspects are observed during usual care and may be recorded by individuals other than the nurse. Abnormal findings must be validated and interpreted by the nurse.

**Equipment**  
None

### INTERPROFESSIONAL PRACTICE

Assessing the neck is within the scope of practice for many health care providers other than nurses, such as physician assistants and physical therapists. Although these providers may verbally communicate their findings and plan to other health care team members, the nurse must also know where to locate their documentation in the client's medical record.

## Assessing the Neck—continued


## IMPLEMENTATION

## Performance

1. Prior to performing the procedure, introduce self and verify the client's identity using agency protocol. Explain to the client what you are going to do, why it is necessary, and how he or she can participate. Discuss how the results will be used in planning further care or treatments.
2. Perform hand hygiene and observe other appropriate infection prevention procedures.
3. Provide for client privacy.
4. Inquire if the client has any history of the following: problems with neck lumps; neck pain or stiffness; when and how any lumps occurred; previous diagnoses of thyroid problems; and other treatments provided (e.g., surgery, radiation).

| Assessment                                                                                                                                                                                                                                                                                                                                                                                                                                                                                                                                                                                                                                                                         | Normal Findings                                                                                                                                                     | Deviations from Normal                                                                                                                                                                                                                                                                                          |
|------------------------------------------------------------------------------------------------------------------------------------------------------------------------------------------------------------------------------------------------------------------------------------------------------------------------------------------------------------------------------------------------------------------------------------------------------------------------------------------------------------------------------------------------------------------------------------------------------------------------------------------------------------------------------------|---------------------------------------------------------------------------------------------------------------------------------------------------------------------|-----------------------------------------------------------------------------------------------------------------------------------------------------------------------------------------------------------------------------------------------------------------------------------------------------------------|
| <b>NECK MUSCLES</b>                                                                                                                                                                                                                                                                                                                                                                                                                                                                                                                                                                                                                                                                |                                                                                                                                                                     |                                                                                                                                                                                                                                                                                                                 |
| <b>5.</b> Inspect the neck muscles (sternocleidomastoid and trapezius) for abnormal swellings or masses. Ask the client to hold the head erect.                                                                                                                                                                                                                                                                                                                                                                                                                                                                                                                                    | Muscles equal in size; head centered                                                                                                                                | Unilateral neck swelling; head tilted to one side (indicates presence of masses, injury, muscle weakness, shortening of sternocleidomastoid muscle, scars)                                                                                                                                                      |
| <b>6.</b> Observe head movement. Ask client to: <ul style="list-style-type: none"> <li>• Move the chin to the chest. <b>Rationale:</b> <i>This determines function of the sternocleidomastoid muscle.</i></li> <li>• Move the head back so that the chin points upward. <b>Rationale:</b> <i>This determines function of the trapezius muscle.</i></li> <li>• Move the head so that the ear is moved toward the shoulder on each side. <b>Rationale:</b> <i>This determines function of the sternocleidomastoid muscle.</i></li> <li>• Turn the head to the right and to the left. <b>Rationale:</b> <i>This determines function of the sternocleidomastoid muscle.</i></li> </ul> | Coordinated, smooth movements with no discomfort<br>Head flexes 45°<br><br>Head hyperextends 60°<br><br>Head laterally flexes 40°<br><br>Head laterally rotates 70° | Muscle tremor, spasm, or stiffness<br><br>Limited range of motion; painful movements; involuntary movements (e.g., up-and-down nodding movements associated with Parkinson's disease)<br>Head hyperextends less than 60°<br><br>Head laterally flexes less than 40°<br><br>Head laterally rotates less than 70° |
| <b>7.</b> Assess muscle strength. <ul style="list-style-type: none"> <li>• Ask the client to turn the head to one side against the resistance of your hand. Repeat with the other side. <b>Rationale:</b> <i>This determines the strength of the sternocleidomastoid muscle.</i></li> <li>• Ask the client to shrug the shoulders against the resistance of your hands. <b>Rationale:</b> <i>This determines the strength of the trapezius muscles.</i></li> </ul>                                                                                                                                                                                                                 | Equal strength<br><br>Equal strength                                                                                                                                | Unequal strength<br><br>Unequal strength                                                                                                                                                                                                                                                                        |
| <b>LYMPH NODES</b>                                                                                                                                                                                                                                                                                                                                                                                                                                                                                                                                                                                                                                                                 |                                                                                                                                                                     |                                                                                                                                                                                                                                                                                                                 |
| <b>8.</b> Palpate the entire neck for enlarged lymph nodes. <ul style="list-style-type: none"> <li>• Face the client, and bend the client's head forward slightly or toward the side being examined. <b>Rationale:</b> <i>This relaxes the soft tissue and muscles.</i></li> <li>• Palpate the nodes using the pads of the fingers. Move the fingertips in a gentle rotating motion.</li> <li>• When examining the submental and submandibular nodes, place the fingertips under the mandible on the side nearest the palpating hand, and pull the skin and subcutaneous tissue laterally over the mandibular surface so that the tissue rolls over the nodes.</li> </ul>          | Not palpable                                                                                                                                                        | Enlarged, palpable, possibly tender (associated with infection and tumors)                                                                                                                                                                                                                                      |

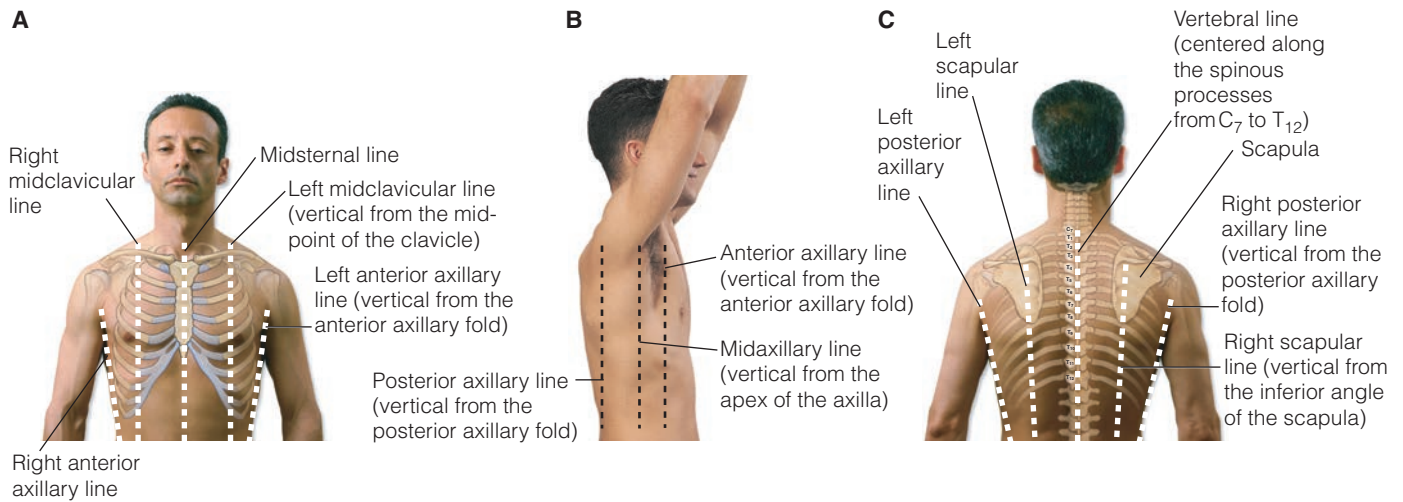
## Assessing the Neck—continued

| Assessment                                                                                                                                                                                                                                                                                                                                                                                                                                                                                                                                                                                                                                                                                                                                                                                                                                                     | Normal Findings                                                                                                                    | Deviations from Normal                                                                            |
|----------------------------------------------------------------------------------------------------------------------------------------------------------------------------------------------------------------------------------------------------------------------------------------------------------------------------------------------------------------------------------------------------------------------------------------------------------------------------------------------------------------------------------------------------------------------------------------------------------------------------------------------------------------------------------------------------------------------------------------------------------------------------------------------------------------------------------------------------------------|------------------------------------------------------------------------------------------------------------------------------------|---------------------------------------------------------------------------------------------------|
| <ul style="list-style-type: none"> <li>When palpating the supraclavicular nodes, have the client bend the head forward to relax the tissues of the anterior neck and to relax the shoulders so that the clavicles drop. Use your hand nearest the side to be examined when facing the client (i.e., your left hand for the client's right nodes). Use your free hand to flex the client's head forward if necessary. Hook your index and third fingers over the clavicle lateral to the sternocleidomastoid muscle. ①</li> <li>When palpating the anterior cervical nodes and posterior cervical nodes, move your fingertips slowly in a forward circular motion against the sternocleidomastoid and trapezius muscles, respectively.</li> <li>To palpate the deep cervical nodes, bend or hook your fingers around the sternocleidomastoid muscle.</li> </ul> |                                                  | <p>① Palpating the supraclavicular lymph nodes.</p>                                               |
| <b>TRACHEA</b>                                                                                                                                                                                                                                                                                                                                                                                                                                                                                                                                                                                                                                                                                                                                                                                                                                                 |                                                                                                                                    |                                                                                                   |
| <p>9. Palpate the trachea for lateral deviation. Place your fingertip or thumb on the trachea in the suprasternal notch (see Figure 30-19, earlier), and then move your finger laterally to the left and the right in spaces bordered by the clavicle, the anterior aspect of the sternocleidomastoid muscle, and the trachea.</p>                                                                                                                                                                                                                                                                                                                                                                                                                                                                                                                             | Central placement in midline of neck; spaces are equal on both sides                                                               | Deviation to one side, indicating possible neck tumor; thyroid enlargement; enlarged lymph nodes  |
| <b>THYROID GLAND</b>                                                                                                                                                                                                                                                                                                                                                                                                                                                                                                                                                                                                                                                                                                                                                                                                                                           |                                                                                                                                    |                                                                                                   |
| <p>10. Inspect the thyroid gland.</p> <ul style="list-style-type: none"> <li>Stand in front of the client.</li> <li>Observe the lower half of the neck overlying the thyroid gland for symmetry and visible masses.</li> <li>Ask the client to extend the head and swallow. If necessary, offer a glass of water to make it easier for the client to swallow.</li> </ul> <p><b>Rationale:</b> <i>This action determines how the thyroid and cricoid cartilages move and whether swallowing causes a bulging of the gland.</i></p> <p>11. Document findings in the client record using printed or electronic forms or checklists supplemented by narrative notes when appropriate.</p>                                                                                                                                                                          | <p>Not visible on inspection</p> <p>Gland ascends during swallowing but is not visible</p>                                         | <p>Visible diffuseness or local enlargement</p> <p>Gland is not fully movable with swallowing</p> |
| <b>EVALUATION</b>                                                                                                                                                                                                                                                                                                                                                                                                                                                                                                                                                                                                                                                                                                                                                                                                                                              |                                                                                                                                    |                                                                                                   |
| <ul style="list-style-type: none"> <li>Perform a detailed follow-up examination of other systems based on findings that deviated from expected or normal for the client. Relate findings to previous assessment data if available.</li> </ul>                                                                                                                                                                                                                                                                                                                                                                                                                                                                                                                                                                                                                  | <ul style="list-style-type: none"> <li>Report deviations from expected or normal findings to the primary care provider.</li> </ul> |                                                                                                   |

**LIFESPAN CONSIDERATIONS** Assessing the Neck**INFANTS AND CHILDREN**

- Examine the neck while the infant or child is lying supine. Lift the head and turn it from side to side to determine neck mobility.
- An infant's neck is normally short, lengthening by about age 3 years. This makes palpation of the trachea difficult.





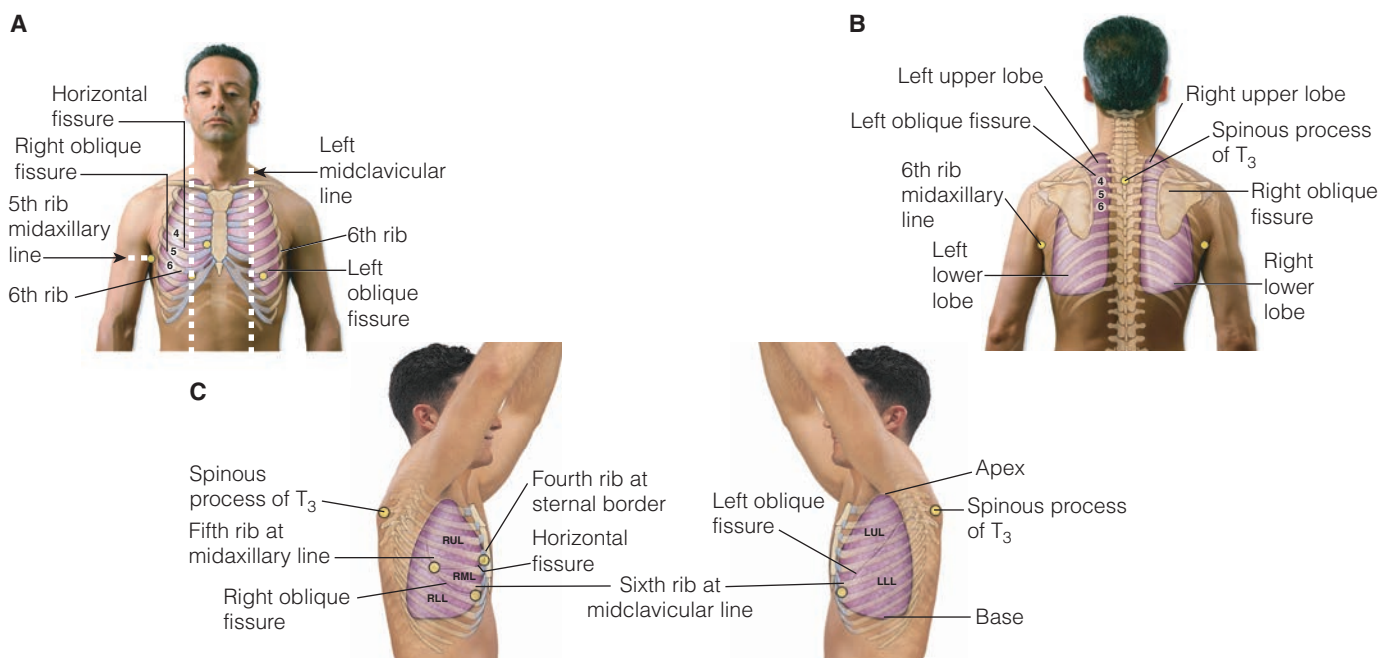
**Figure 30-21** ■ Chest wall landmarks: A, anterior chest; B, lateral chest; C, posterior chest.

Figure 30-21 ■ shows the anterior, lateral, and posterior series of lines. The midsternal line is a vertical line running through the center of the sternum. The midclavicular lines (right and left) are vertical lines from the midpoints of the clavicles. The anterior axillary lines (right and left) are vertical lines from the anterior axillary folds (Figure 30-21A). Figure 30-21B shows the three imaginary lines of the lateral chest. The posterior axillary line is a vertical line from the posterior axillary fold. The midaxillary line is a vertical line from the apex of the axilla. Figure 30-21C shows the posterior chest landmarks. The vertebral line is a vertical line along the spinous processes. The scapular lines (right and left) are vertical lines from the inferior angles of the scapulae.

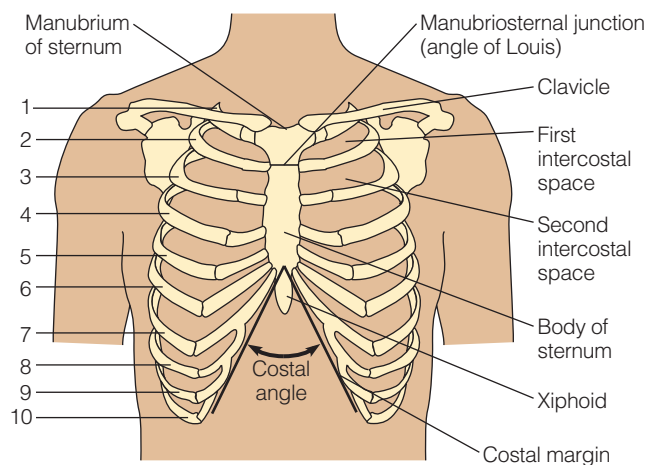
Locating the position of each rib and certain spinous processes is essential for identifying underlying lobes of the lung.

Figure 30-22A ■, shows an anterior view of the chest and underlying lungs; Figure 30-22B a posterior view; and Figure 30-22C right and left lateral views. Each lung is first divided into the upper and lower lobes by an oblique fissure that runs from the level of the spinous process of the third thoracic vertebra ( $T_3$ ) to the level of the sixth rib at the midclavicular line. The right upper lobe is abbreviated RUL; the right lower lobe, RLL. Similarly, the left upper lobe is abbreviated LUL; the left lower lobe, LLL. The right lung is further divided by a minor fissure into the right upper lobe and right middle lobe (RML). This fissure runs anteriorly from the right midaxillary line at the level of the fifth rib to the level of the fourth rib.

These specific landmarks (i.e.,  $T_3$  and the fourth, fifth, and sixth ribs) are located as follows. The starting point for locating the ribs anteriorly is the **angle of Louis**, the junction between the body of



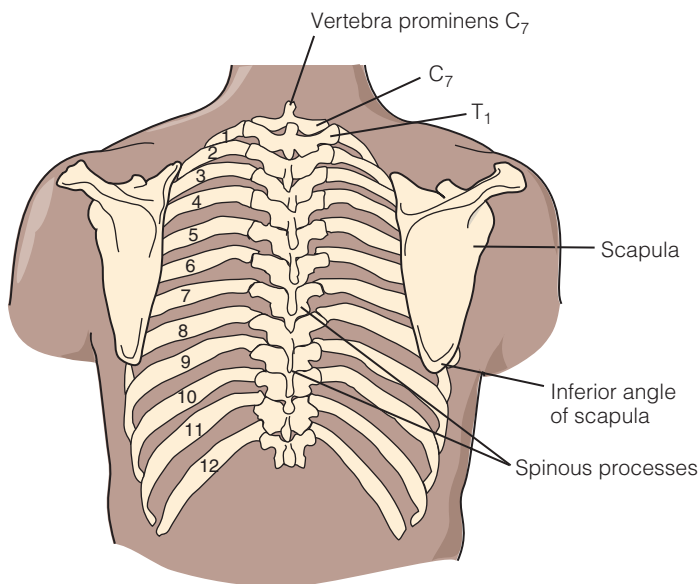
**Figure 30-22** ■ Chest landmarks: A, anterior chest landmarks and underlying lungs; B, posterior chest landmarks and underlying lungs; C, lateral chest landmarks and underlying lungs.



**Figure 30-23** ■ Location of the anterior ribs, the angle of Louis, and the sternum.

the **sternum** (breastbone) and the **manubrium** (the handle-like superior part of the sternum that joins with the clavicles). The superior border of the second rib attaches to the sternum at this manubriosternal junction (Figure 30-23 ■). The nurse can identify the manubrium by first palpating the clavicle and following its course to its attachment at the manubrium. The nurse then palpates and counts distal ribs and intercostal spaces (ICSs) from the second rib. It is important to note that an ICS is numbered according to the number of the rib immediately *above* the space. When palpating for rib identification, the nurse should palpate along the midclavicular line rather than the sternal border because the rib cartilages are very close at the sternum. Only the first seven ribs attach directly to the sternum.

The counting of ribs is more difficult on the posterior than on the anterior thorax. For identifying underlying lung lobes, the pertinent landmark is T<sub>3</sub>. The starting point for locating T<sub>3</sub> is the spinous process of the seventh cervical vertebra (C<sub>7</sub>) (Figure 30-24 ■).



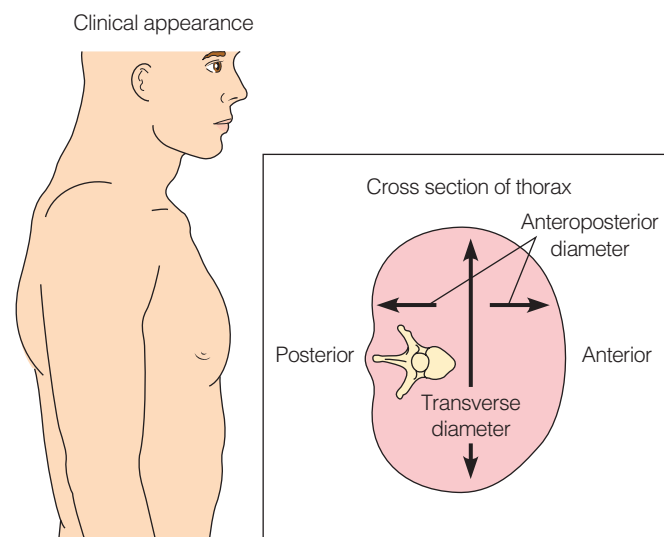
**Figure 30-24** ■ Location of the posterior ribs in relation to the spinous processes.

When the client flexes the neck anteriorly, a prominent process can be observed and palpated. This is the spinous process of the seventh cervical vertebra. If two spinous processes are observed, the superior one is C<sub>7</sub>, and the inferior one is the spinous process of the first thoracic vertebra (T<sub>1</sub>). The nurse then palpates and counts the spinous processes from C<sub>7</sub> to T<sub>3</sub>. Each spinous process up to T<sub>4</sub> is adjacent to the corresponding rib number; for example, T<sub>3</sub> is adjacent to the third rib. After T<sub>4</sub>, however, the spinous processes project obliquely, causing the spinous process of the vertebra to lie, not over its correspondingly numbered rib, but over the rib below. Thus, the spinous process of T<sub>5</sub> lies over the body of T<sub>6</sub> and is adjacent to the sixth rib.

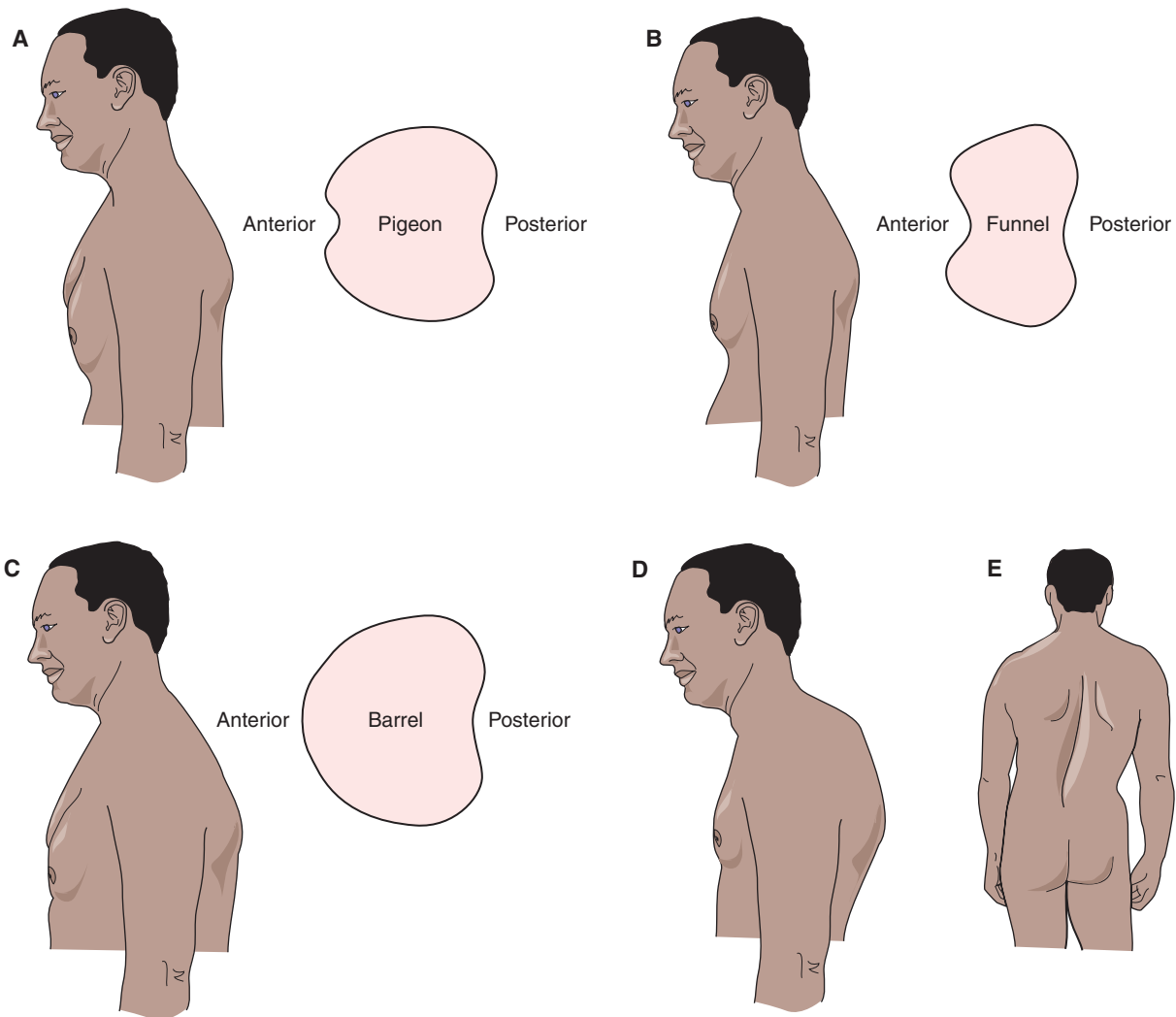
## Chest Shape and Size

In healthy adults, the thorax is oval. Its anteroposterior diameter is half its transverse diameter (Figure 30-25 ■). The overall shape of the thorax is elliptical; that is, its transverse diameter is smaller at the top than at the base. In older adults, kyphosis and osteoporosis alter the size of the chest cavity as the ribs move downward and forward.

There are several deformities of the chest (Figure 30-26 ■). Pigeon chest (*pectus carinatum*), a permanent deformity, may be caused by rickets (abnormal bone formation due to lack of dietary calcium). A narrow transverse diameter, an increased anteroposterior diameter, and a protruding sternum characterize pigeon chest. A funnel chest (*pectus excavatum*), a congenital defect, is the opposite of pigeon chest in that the sternum is depressed, narrowing the anteroposterior diameter. Because the sternum points posteriorly in clients with a funnel chest, abnormal pressure on the heart may result in altered function. A barrel chest, in which the ratio of the anteroposterior to transverse diameter is 1 to 1, is seen in clients with thoracic kyphosis (excessive convex curvature of the thoracic spine) and emphysema (chronic pulmonary condition in which the air sacs, or alveoli, are dilated and distended). Scoliosis is a lateral deviation of the spine.



**Figure 30-25** ■ Configuration of the thorax showing oval shape, anteroposterior diameter, and transverse diameter.



**Figure 30-26** ■ Chest deformities: A, pigeon chest; B, funnel chest; C, barrel chest; D, kyphosis; E, scoliosis.

**TABLE 30-7** Normal Breath Sounds

| Type                | Description                                                                                                                  | Location                                                                                   | Characteristics                                                                                    |
|---------------------|------------------------------------------------------------------------------------------------------------------------------|--------------------------------------------------------------------------------------------|----------------------------------------------------------------------------------------------------|
| Vesicular           | Soft-intensity, low-pitched, “gentle sighing” sounds created by air moving through smaller airways (bronchioles and alveoli) | Over peripheral lung; best heard at base of lungs                                          | Best heard on inspiration, which is about 2.5 times longer than the expiratory phase (5:2 ratio)   |
| Bronchovesicular    | Moderate-intensity and moderate-pitched “blowing” sounds created by air moving through larger airway (bronchi)               | Between the scapulae and lateral to the sternum at the first and second intercostal spaces | Equal inspiratory and expiratory phases (1:1 ratio)                                                |
| Bronchial (tubular) | High-pitched, loud, “harsh” sounds created by air moving through the trachea                                                 | Anteriorly over the trachea; not normally heard over lung tissue                           | Louder than vesicular sounds; have a short inspiratory phase and long expiratory phase (1:2 ratio) |

## Breath Sounds

Abnormal breath sounds, called **adventitious breath sounds**, occur when air passes through narrowed airways or airways filled with fluid or mucus, or when pleural linings are inflamed. Table 30-7 describes normal breath sounds. Adventitious sounds are often superimposed over normal sounds (Table 30-8). Absence of breath

sounds over some lung areas is also a significant finding that is associated with collapsed and surgically removed lobes or severe pneumonia.

Assessment of the lungs and thorax includes all methods of examination: inspection, palpation, percussion, and auscultation. Skill 30-11 describes how to assess the thorax and lungs.

**TABLE 30–8 Adventitious Breath Sounds**

| Name              | Description                                                                                                                                                                                                                                               | Cause                                                                                  | Location                                                                                          |
|-------------------|-----------------------------------------------------------------------------------------------------------------------------------------------------------------------------------------------------------------------------------------------------------|----------------------------------------------------------------------------------------|---------------------------------------------------------------------------------------------------|
| Crackles (rales)  | Fine, short, interrupted crackling sounds; alveolar rales are high pitched. Sound can be simulated by rolling a lock of hair near the ear. Best heard on inspiration but can be heard on both inspiration and expiration. May not be cleared by coughing. | Air passing through fluid or mucus in any air passage                                  | Most commonly heard in the bases of the lower lung lobes                                          |
| Gurgles (rhonchi) | Continuous, low-pitched, coarse, gurgling, harsh, louder sounds with a moaning or snoring quality. Best heard on expiration but can be heard on both inspiration and expiration.<br>May be altered by coughing.                                           | Air passing through narrowed air passages as a result of secretions, swelling, tumors  | Loud sounds can be heard over most lung areas but predominate over the trachea and bronchi        |
| Friction rub      | Superficial grating or creaking sounds heard during inspiration and expiration. Not relieved by coughing.                                                                                                                                                 | Rubbing together of inflamed pleural surfaces                                          | Heard most often in areas of greatest thoracic expansion (e.g., lower anterior and lateral chest) |
| Wheeze            | Continuous, high-pitched, squeaky musical sounds. Best heard on expiration. Not usually altered by coughing.                                                                                                                                              | Air passing through a constricted bronchus as a result of secretions, swelling, tumors | Heard over all lung fields                                                                        |

## Assessing the Thorax and Lungs

### PLANNING

For efficiency, the nurse usually examines the posterior thorax first, then the anterior thorax. For posterior and lateral thorax examinations, the client is uncovered to the waist and in a sitting position. A sitting or lying position may be used for anterior thorax examination. The sitting position is preferred because it maximizes thorax expansion. Good lighting is essential, especially for thorax inspection.

### Equipment

- Stethoscope

### DELEGATION

Due to the substantial knowledge and skill required, assessment of the thorax and lungs is not delegated to UAP. However, many aspects of breathing are observed during usual care and may be recorded by individuals other than the nurse. Abnormal findings must be validated and interpreted by the nurse.

### INTERPROFESSIONAL PRACTICE

Assessing the thorax and lungs is within the scope of practice for many health care providers other than nurses before, during, and after their treatments. For example, both physician assistants and respiratory therapists may check the client's lungs. Although these providers may verbally communicate their findings and plan to other health care team members, the nurse must also know where to locate their documentation in the client's medical record.

### IMPLEMENTATION

#### Performance

1. Prior to performing the procedure, introduce self and verify the client's identity using agency protocol. Explain to the client what you are going to do, why it is necessary, and how he or she can participate. Discuss how the results will be used in planning further care or treatments.
2. Perform hand hygiene and observe other appropriate infection prevention procedures.
3. Provide for client privacy. In women, drape the anterior thorax when it is not being examined.
4. Inquire if the client has any history of the following: family history of illness, including cancer, allergies, tuberculosis; lifestyle habits such as smoking and occupational hazards (e.g., inhaling fumes); medications being taken; current problems (e.g., swellings, coughs, wheezing, pain).

#### Assessment

#### Normal Findings

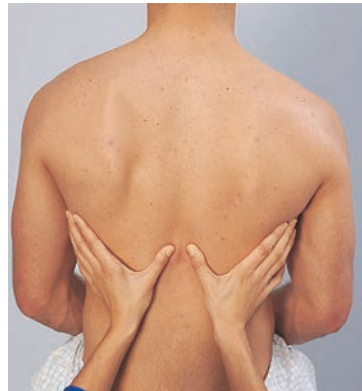
#### Deviations from Normal

#### POSTERIOR THORAX

- |                                                                                                                                                    |                                                                            |                                                                                     |
|----------------------------------------------------------------------------------------------------------------------------------------------------|----------------------------------------------------------------------------|-------------------------------------------------------------------------------------|
| 5. Inspect the shape and symmetry of the thorax from posterior and lateral views. Compare the anteroposterior diameter to the transverse diameter. | Anteroposterior to transverse diameter in ratio of 1:2<br>Thorax symmetric | Barrel chest; increased anteroposterior to transverse diameter<br>Thorax asymmetric |
|----------------------------------------------------------------------------------------------------------------------------------------------------|----------------------------------------------------------------------------|-------------------------------------------------------------------------------------|

## Assessing the Thorax and Lungs—continued

| Assessment                                                                                                                                                                                                                                                                                                                                                                                                                                                            | Normal Findings                                                                                                                                                                                                                             | Deviations from Normal                                                                                                                                                |
|-----------------------------------------------------------------------------------------------------------------------------------------------------------------------------------------------------------------------------------------------------------------------------------------------------------------------------------------------------------------------------------------------------------------------------------------------------------------------|---------------------------------------------------------------------------------------------------------------------------------------------------------------------------------------------------------------------------------------------|-----------------------------------------------------------------------------------------------------------------------------------------------------------------------|
| <p>6. Inspect the spinal alignment for deformities if the client can stand. From a lateral position, observe the three normal curvatures: cervical, thoracic, and lumbar.</p> <ul style="list-style-type: none"> <li>To assess for lateral deviation of spine (scoliosis), observe the standing client from the rear. Have the client bend forward at the waist and observe from behind.</li> </ul>                                                                   | <p>Spine vertically aligned</p> <p>Spinal column is straight, right and left shoulders and hips are at same height.</p>                                                                                                                     | <p>Exaggerated spinal curvatures (kyphosis, lordosis)</p> <p>Spinal column deviates to one side, often accentuated when bending over. Shoulders or hips not even.</p> |
| <p>7. Palpate the posterior thorax.</p> <ul style="list-style-type: none"> <li>Assess the temperature and integrity of all chest skin.</li> <li>For clients who have respiratory complaints, palpate all thorax areas for bulges, tenderness, or abnormal movements. Avoid deep palpation for painful areas, especially if a fractured rib is suspected. In such a case, deep palpation could lead to displacement of the bone fragment against the lungs.</li> </ul> | <p>Skin intact; uniform temperature</p> <p>Chest wall intact; no tenderness; no masses</p>                                                                                                                                                  | <p>Skin lesions; areas of hyperthermia</p> <p>Lumps, bulges; depressions; areas of tenderness; movable structures (e.g., rib)</p>                                     |
| <p>8. Palpate the posterior thorax for respiratory excursion (thoracic expansion). Place the palms of both your hands over the lower thorax with your thumbs adjacent to the spine and your fingers stretched laterally. ❶ Ask the client to take a deep breath while you observe the movement of your hands and any lag in movement.</p>                                                                                                                             | <p>Full and symmetric thorax expansion (i.e., when the client takes a deep breath, your thumbs should move apart an equal distance and at the same time; normally the thumbs separate 3 to 5 cm [1.2 to 2 in.] during deep inspiration)</p> | <p>Asymmetric and/or decreased thorax expansion</p>                                                                                                                   |

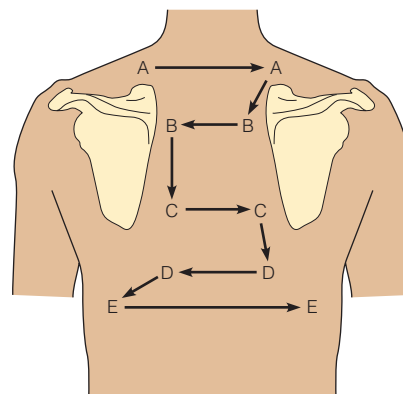


❶ Position of the nurse's hands when assessing respiratory excursion on the posterior thorax.

9. Palpate the thorax for vocal (tactile) **fremitus**, the faintly perceptible vibration felt through the chest wall when the client speaks.
- Place the palmar surfaces of your fingertips or the ulnar aspect of your hand or closed fist on the posterior thorax, starting near the apex of the lungs (see ❷, position A).
  - Ask the client to repeat such words as “blue moon” or “one, two, three.”
  - Repeat the two steps, moving your hands sequentially to the base of the lungs, through positions B–E in ❷.

Bilateral symmetry of vocal fremitus  
Fremitus is heard most clearly at the apex of the lungs

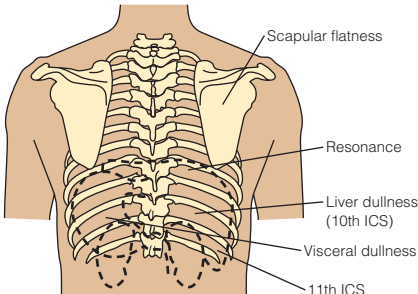
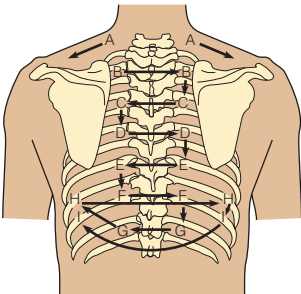
Low-pitched voices of males are more readily palpated than higher pitched voices of females



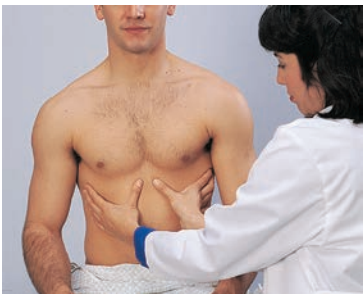
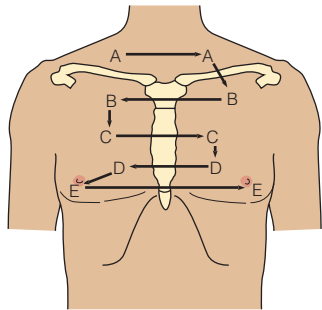
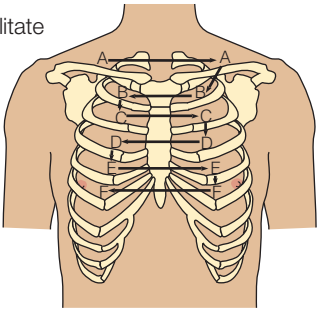
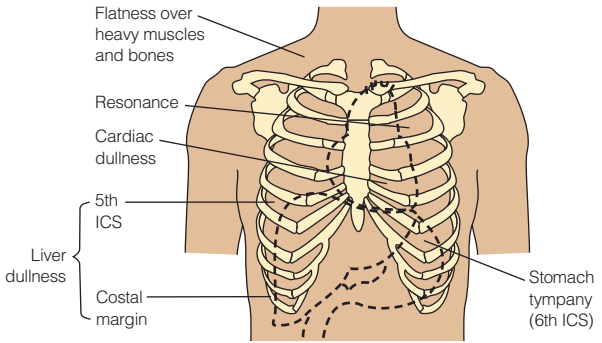
Decreased or absent fremitus (associated with pneumothorax)  
Increased fremitus (associated with consolidated lung tissue, as in pneumonia)

❷ Areas and sequence for palpating tactile fremitus on the posterior thorax.

## Assessing the Thorax and Lungs—continued

| Assessment                                                                                                                                                                                                                                                                                                                                                                                                                                                                                                                                                                                                                                                                                                                                                                                                                                                                                       | Normal Findings                                                                                                                                                                                                                       | Deviations from Normal                                                                                                                              |
|--------------------------------------------------------------------------------------------------------------------------------------------------------------------------------------------------------------------------------------------------------------------------------------------------------------------------------------------------------------------------------------------------------------------------------------------------------------------------------------------------------------------------------------------------------------------------------------------------------------------------------------------------------------------------------------------------------------------------------------------------------------------------------------------------------------------------------------------------------------------------------------------------|---------------------------------------------------------------------------------------------------------------------------------------------------------------------------------------------------------------------------------------|-----------------------------------------------------------------------------------------------------------------------------------------------------|
| <ul style="list-style-type: none"> <li>Compare the fremitus on both lungs and between the apex and the base of each lung, using either one hand and moving it from one side of the client to the corresponding area on the other side or using two hands that are placed simultaneously on the corresponding areas of each side of the thorax.</li> </ul>                                                                                                                                                                                                                                                                                                                                                                                                                                                                                                                                        |                                                                                                                                                                                                                                       |                                                                                                                                                     |
| <p>10. Percuss the thorax. Percussion of the thorax is performed to determine whether underlying lung tissue is filled with air, liquid, or solid material and to determine the positions and boundaries of certain organs. Because percussion penetrates to a depth of 5 to 7 cm (2 to 3 in.), it detects superficial rather than deep lesions (see 3 and Table 30-4, earlier).</p> <ul style="list-style-type: none"> <li>Ask the client to bend the head and fold the arms forward across the chest. <b>Rationale:</b> <i>This separates the scapula and exposes more lung tissue to percussion.</i></li> <li>Percuss in the intercostal spaces at about 5-cm (2-in.) intervals in a systematic sequence. 4</li> <li>Compare one side of the lung with the other.</li> <li>Percuss the lateral thorax every few inches, starting at the axilla and working down to the eighth rib.</li> </ul> | <p>Percussion notes resonate, except over scapula</p> <p>Lowest point of resonance is at the diaphragm (i.e., at the level of the 8th to 10th rib posteriorly)</p> <p><i>Note:</i> Percussion on a rib normally elicits dullness.</p> | <p>Asymmetry in percussion notes</p> <p>Areas of dullness or flatness over lung tissue (associated with consolidation of lung tissue or a mass)</p> |
|                                                                                                                                                                                                                                                                                                                                                                                                                                                                                                                                                                                                                                                                                                                                                                                                                                                                                                  |                                                                                                                                                     |                                                                 |
|                                                                                                                                                                                                                                                                                                                                                                                                                                                                                                                                                                                                                                                                                                                                                                                                                                                                                                  | <p>3 Normal percussion sounds on the posterior thorax.</p>                                                                                                                                                                            | <p>4 Sequence for posterior thorax percussion.</p>                                                                                                  |
| <p>11. Auscultate the thorax using the flat-disk diaphragm of the stethoscope.</p> <p><b>Rationale:</b> <i>The diaphragm of the stethoscope is best for transmitting the high-pitched breath sounds.</i></p> <ul style="list-style-type: none"> <li>Use the systematic zigzag procedure used in percussion.</li> <li>Ask the client to take slow, deep breaths through the mouth. Listen at each point to the breath sounds during a complete inspiration and expiration.</li> <li>Compare findings at each point with the corresponding point on the opposite side of the thorax.</li> </ul>                                                                                                                                                                                                                                                                                                    | <p>Vesicular and bronchovesicular breath sounds (see Table 30-7)</p>                                                                                                                                                                  | <p>Adventitious breath sounds (e.g., crackles, gurgles, wheeze, friction rub; see Table 30-8)</p> <p>Absence of breath sounds</p>                   |
| <p><b>ANTERIOR THORAX</b></p>                                                                                                                                                                                                                                                                                                                                                                                                                                                                                                                                                                                                                                                                                                                                                                                                                                                                    |                                                                                                                                                                                                                                       |                                                                                                                                                     |
| <p>12. Inspect breathing patterns (e.g., respiratory rate and rhythm).</p>                                                                                                                                                                                                                                                                                                                                                                                                                                                                                                                                                                                                                                                                                                                                                                                                                       | <p>Quiet, rhythmic, and effortless respirations (see Chapter 29 ∞, page 496)</p>                                                                                                                                                      | <p>See Chapter 29 ∞, Box 29-5 on page 498, for abnormal breathing patterns and sounds.</p>                                                          |
| <p>13. Inspect the costal angle (angle formed by the intersection of the costal margins) and the angle at which the ribs enter the spine.</p>                                                                                                                                                                                                                                                                                                                                                                                                                                                                                                                                                                                                                                                                                                                                                    | <p>Costal angle is less than 90°, and the ribs insert into the spine at approximately a 45° angle (see Figure 30-23, earlier)</p>                                                                                                     | <p>Costal angle is widened (associated with chronic obstructive pulmonary disease)</p>                                                              |
| <p>14. Palpate the anterior thorax (see posterior thorax palpation).</p>                                                                                                                                                                                                                                                                                                                                                                                                                                                                                                                                                                                                                                                                                                                                                                                                                         |                                                                                                                                                                                                                                       |                                                                                                                                                     |
| <p>15. Palpate the anterior thorax for respiratory excursion.</p>                                                                                                                                                                                                                                                                                                                                                                                                                                                                                                                                                                                                                                                                                                                                                                                                                                | <p>Full symmetric excursion; thumbs normally separate 3 to 5 cm (1.2 to 2 in.)</p>                                                                                                                                                    | <p>Asymmetric and/or decreased respiratory excursion</p>                                                                                            |

## Assessing the Thorax and Lungs—continued

| Assessment                                                                                                                                                                                                                                                                                                                                                           | Normal Findings                                                                                                                                                                                                                                                                                                           | Deviations from Normal                                                                                                                                                          |
|----------------------------------------------------------------------------------------------------------------------------------------------------------------------------------------------------------------------------------------------------------------------------------------------------------------------------------------------------------------------|---------------------------------------------------------------------------------------------------------------------------------------------------------------------------------------------------------------------------------------------------------------------------------------------------------------------------|---------------------------------------------------------------------------------------------------------------------------------------------------------------------------------|
| <ul style="list-style-type: none"> <li>Place the palms of both your hands on the lower thorax, with your fingers laterally along the lower rib cage and your thumbs along the costal margins. <b>5</b></li> <li>Ask the client to take a deep breath while you observe the movement of your hands.</li> </ul>                                                        |                                                                                                                                                                                                                                          | <p><b>5</b> Position of the nurse's hands when assessing respiratory excursion on the anterior thorax.</p>                                                                      |
| <p><b>16.</b> Palpate tactile fremitus in the same manner as for the posterior thorax and using the sequence shown in <b>6</b>. If the breasts are large and cannot be retracted adequately for palpation, this part of the examination is usually omitted.</p>                                                                                                      | <p>Same as posterior vocal fremitus; fremitus is normally decreased over heart and breast tissue</p>                                                                                                                                     | <p>Same as posterior fremitus</p> <p><b>6</b> Areas and sequence for palpating tactile fremitus on the anterior thorax.</p>                                                     |
| <p><b>17.</b> Percuss the anterior thorax systematically.</p> <ul style="list-style-type: none"> <li>Begin above the clavicles in the supraclavicular space, and proceed downward to the diaphragm. <b>7</b></li> <li>Compare the lung on one side to the lung on the other side.</li> <li>Displace female breasts to facilitate percussion of the lungs.</li> </ul> | <p>Percussion notes resonate down to the sixth rib at the level of the diaphragm but are flat over areas of heavy muscle and bone, dull on areas over the heart and the liver, and tympanic over the underlying stomach. <b>8</b></p>  | <p>Asymmetry in percussion notes</p> <p>Areas of dullness or flatness over lung tissue</p>  |
| <p><b>18.</b> Auscultate the trachea.</p>                                                                                                                                                                                                                                                                                                                            | <p>Bronchial and tubular breath sounds (see Table 30-7 on page 555)</p>                                                                                                                                                                                                                                                   | <p>Adventitious breath sounds (see Table 30-8 on page 556)</p>                                                                                                                  |
| <p><b>19.</b> Auscultate the anterior thorax. Use the sequence used in percussion 7, beginning over the bronchi between the sternum and the clavicles.</p>                                                                                                                                                                                                           | <p>Bronchovesicular and vesicular breath sounds (see Table 30-7)</p>                                                                                                                                                                                                                                                      | <p>Adventitious breath sounds (see Table 30-8)</p>                                                                                                                              |
| <p><b>20.</b> Document findings in the client record using printed or electronic forms or checklists supplemented by narrative notes when appropriate.</p>                                                                                                                                                                                                           |                                                                                                                                                                                                                                                                                                                           |                                                                                                                                                                                 |

### SAMPLE DOCUMENTATION

5/28/15 0830 Lungs clear to auscultation except for fine crackles over both posterior lower lobes, partially cleared after coughing. Rarely moves in bed. Assisted to a chair and reviewed deep-breathing exercises. Effective return demonstration. \_\_\_\_\_ N. Schmidt, RN

### EVALUATION

- Perform a detailed follow-up examination based on findings that deviated from expected or normal for the client. Relate findings to previous assessment data if available.
- Report deviations from expected or normal findings to the primary care provider.

**LIFESPAN CONSIDERATIONS** Assessing the Thorax and Lungs

**INFANTS**

The thorax is rounded; that is, the diameter from the front to the back (anteroposterior) is equal to the transverse diameter (Figure 30–27 ■). It is also cylindrical, having a nearly equal diameter at the top and the base. This makes it harder for infants to expand their thoracic space.

- To assess tactile fremitus, place the hand over the crying infant's thorax.
- Infants tend to breathe using their diaphragm; assess rate and rhythm by watching the abdomen, rather than the thorax, rise and fall.
- The right bronchial branch is short and angles down as it leaves the trachea, making it easy for small objects to be inhaled. Sudden onset of cough or other signs of respiratory distress may indicate the infant has inhaled a foreign object.

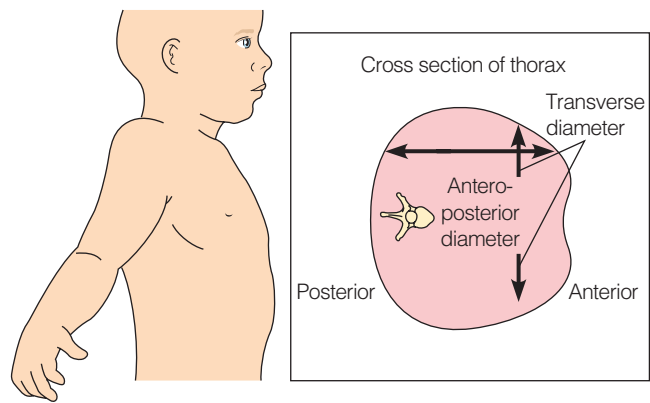
**CHILDREN**

- By about 6 years of age, the anteroposterior diameter has decreased in proportion to the transverse diameter, with a 1:2 ratio present.
- Children tend to breathe more abdominally than thoracically up to age 6.
- During the rapid growth spurts of adolescence, spinal curvature and rotation (scoliosis) may appear. Children should be assessed for scoliosis by age 12 and annually until their growth slows. Curvature greater than 10% should be referred for further medical evaluation.

**OLDER ADULTS**

- The thoracic curvature may be accentuated (kyphosis) because of osteoporosis and changes in cartilage, resulting in collapse of the vertebrae. This can also compromise and decrease normal respiratory effort.
- Kyphosis and osteoporosis alter the size of the thorax cavity as the ribs move downward and forward.
- The anteroposterior diameter of the thorax widens, giving the person a barrel-chested appearance. This is due to loss of skeletal muscle strength in the thorax and diaphragm and constant lung inflation from excessive expiratory pressure on the alveoli.

Clinical appearance



**Figure 30–27** ■ Configuration of the infant's thorax showing round shape, anteroposterior diameter, and transverse diameter.

- Breathing rate and rhythm are unchanged at rest; the rate normally increases with exercise but may take longer to return to the pre-exercise rate.
- Inspiratory muscles become less powerful, and the inspiration reserve volume decreases. A decrease in depth of respiration is therefore apparent.
- Expiration may require the use of accessory muscles. The expiratory reserve volume significantly increases because of the increased amount of air remaining in the lungs at the end of a normal breath.
- Deflation of the lung is incomplete.
- Small airways lose their cartilaginous support and elastic recoil; as a result, they tend to close, particularly in basal or dependent portions of the lung.
- Elastic tissue of the alveoli loses its stretchability and changes to fibrous tissue. Exertional capacity decreases.
- Cilia in the airways decrease in number and are less effective in removing mucus; older clients are therefore at greater risk for pulmonary infections.

## CARDIOVASCULAR AND PERIPHERAL VASCULAR SYSTEMS

The cardiovascular system consists of the heart and the central blood vessels (primarily the pulmonary, coronary, and neck arteries and veins). The peripheral vascular system includes those arteries and veins distal to the central vessels, extending all the way to the brain and to the extremities.

### Heart

Nurses assess the heart through inspection, palpation, and auscultation, in that sequence. Auscultation is more meaningful when other data are obtained first. The heart is usually assessed during an initial physical assessment; periodic reassessments may be necessary for long-term or at-risk clients or those with cardiac problems. Also see Chapter 51 ∞.

In the average adult, most of the heart lies behind and to the left of the sternum. A small portion (the right atrium) extends to the right of the sternum. The upper portion of the heart (both atria), referred to as its *base*, lies toward the back. The lower portion (the ventricles), referred to as its *apex*, points anteriorly. The apex of the left ventricle

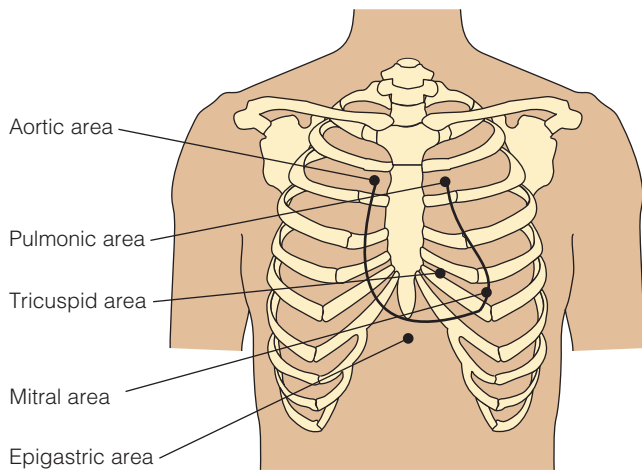
actually touches the chest wall at or medial to the left midclavicular line (MCL) and at or near the fifth left intercostal space (LICS), which is slightly below the left nipple (see Figure 3 on page 494). The point where the apex touches the anterior chest wall and heart movements are most easily observed and palpated is known as the point of maximal impulse (PMI).

### CLINICAL ALERT!

Remember that the base of the lungs is the lower (inferior) portion, and the base of the heart is the upper (superior) portion.

The **precordium**, the area of the chest overlying the heart, is inspected and palpated for the presence of abnormal pulsations or lifts or heaves. The terms **lift** and **heave**, often used interchangeably, refer to a rising along the sternal border with each heartbeat. A lift occurs when cardiac action is very forceful. It should be confirmed by palpation with the palm of the hand. Enlargement or overactivity of the left ventricle produces a heave lateral to the apex, whereas enlargement of the right ventricle produces a heave at or near the sternum.

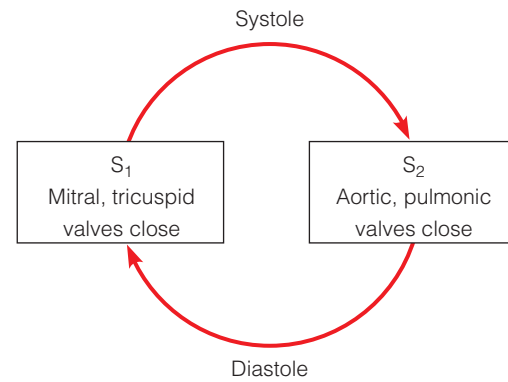




**Figure 30–28** ■ Anatomic sites of the precordium.

Heart sounds can be heard by auscultation. The normal first two heart sounds are produced by closure of the valves of the heart. The first heart sound, **S<sub>1</sub>**, occurs when the atrioventricular (AV) valves close. These valves close when the ventricles have been sufficiently filled. Although the AV valves do not close simultaneously, the closure occurs closely enough to be heard as one sound. **S<sub>1</sub>** is a dull, low-pitched sound described as “lub.” After the ventricles empty the blood into the aorta and pulmonary arteries, the semilunar valves close, producing the second heart sound, **S<sub>2</sub>**, described as “dub.” **S<sub>2</sub>** has a higher pitch than **S<sub>1</sub>** and is shorter in duration. These two sounds, **S<sub>1</sub>** and **S<sub>2</sub>** (“lub-dub”), occur within 1 second or less, depending on the heart rate.

The two heart sounds are audible anywhere on the precordial area, but they are best heard over the aortic, pulmonic, tricuspid, and mitral areas (Figure 30–28 ■). Each area is associated with the closure of heart valves: the aortic area with the aortic valve (inside the aorta as it arises from the left ventricle); the pulmonic area with the pulmonic valve (inside the pulmonary artery as it arises from the right ventricle); the tricuspid area with the tricuspid valve (between the right atrium and ventricle); and the mitral area (sometimes referred



**Figure 30–29** ■ Relationship of heart sounds to systole and diastole.

to as the apical area) with the mitral valve (between the left atrium and ventricle).

Associated with these sounds are systole and diastole. **Systole** is the period in which the ventricles contract. It begins with **S<sub>1</sub>** and ends at **S<sub>2</sub>**. Systole is normally shorter than diastole. **Diastole** is the period in which the ventricles relax. It starts with **S<sub>2</sub>** and ends at the subsequent **S<sub>1</sub>**. Normally no sounds are audible during these periods (Figure 30–29 ■). The experienced nurse, however, may perceive extra heart sounds (**S<sub>3</sub>** and **S<sub>4</sub>**) during diastole. Both sounds are low in pitch and heard best at the apex, with the bell of the stethoscope, and with the client lying on the left side. **S<sub>3</sub>** occurs early in diastole right after **S<sub>2</sub>** and sounds like “lub-dub-ee” (**S<sub>1</sub>**, **S<sub>2</sub>**, **S<sub>3</sub>**) or “Kentuc-ky.” It often disappears when the client sits up. **S<sub>3</sub>** is normal in children and young adults. In older adults, it may indicate heart failure. The **S<sub>4</sub>** sound (ventricular gallop) occurs near the very end of diastole just before **S<sub>1</sub>** and creates the sound of “dee-lub-dub” (**S<sub>4</sub>**, **S<sub>1</sub>**, **S<sub>2</sub>**) or “Ten-nessee.” **S<sub>4</sub>** may be heard in older clients and can be a sign of hypertension.

Normal heart sounds are summarized in Table 30–9. The nurse may also hear abnormal heart sounds, such as clicks, rubs, and murmurs. These are caused by valve disorders or impaired blood flow within the heart and require advanced training to diagnose.

**TABLE 30–9** Normal Heart Sounds

| Sound or Phase       | Description                                                                         | Area                                     |                                                                                                                           |                                                      |                                                      |
|----------------------|-------------------------------------------------------------------------------------|------------------------------------------|---------------------------------------------------------------------------------------------------------------------------|------------------------------------------------------|------------------------------------------------------|
|                      |                                                                                     | Aortic                                   | Pulmonic                                                                                                                  | Tricuspid                                            | Mitral                                               |
| <b>S<sub>1</sub></b> | Dull, low pitched, and longer than <b>S<sub>2</sub></b> ; sounds like “lub”         | Less intensity than <b>S<sub>2</sub></b> | Less intensity than <b>S<sub>2</sub></b>                                                                                  | Louder than or equal to <b>S<sub>2</sub></b>         | Louder than or equal to <b>S<sub>2</sub></b>         |
| Systole              | Normally silent interval between <b>S<sub>1</sub></b> and <b>S<sub>2</sub></b>      |                                          |                                                                                                                           |                                                      |                                                      |
| <b>S<sub>2</sub></b> | Higher pitch than <b>S<sub>1</sub></b> ; sounds like “dub”                          | Louder than <b>S<sub>1</sub></b>         | Louder than <b>S<sub>1</sub></b> ; abnormal if louder than the aortic <b>S<sub>2</sub></b> in adults over 40 years of age | Less intensity than or equal to <b>S<sub>1</sub></b> | Less intensity than or equal to <b>S<sub>1</sub></b> |
| Diastole             | Normally silent interval between <b>S<sub>2</sub></b> and next <b>S<sub>1</sub></b> |                                          |                                                                                                                           |                                                      |                                                      |

## Central Vessels

The carotid arteries supply oxygenated blood to the head and neck (Figure 30–30 ■). Because they are the only source of blood to the brain, prolonged occlusion of these arteries can result in serious brain damage. The carotid pulses correlate with central aortic pressure, thus reflecting cardiac function better than the peripheral pulses. When cardiac output is diminished, the peripheral pulses may be difficult or impossible to feel, but the carotid pulse should be felt easily.

The carotid is also auscultated for a bruit. A **bruit** (a blowing or swishing sound) is created by turbulence of blood flow due either to a narrowed arterial lumen (a common development in older people) or to a condition, such as anemia or hyperthyroidism, that elevates cardiac output. If a bruit is found, the carotid artery is then palpated for a thrill. A **thrill**, which frequently accompanies a bruit, is a vibrating sensation like the purring of a cat or water running through a hose. It, too, indicates turbulent blood flow due to arterial obstruction.

The jugular veins drain blood from the head and neck directly into the superior vena cava and right side of the heart. The external jugular veins are superficial and may be visible above the clavicle. The internal jugular veins lie deeper along the carotid artery and may transmit pulsations onto the skin of the neck. Normally, external neck veins are distended and visible when a person lies down; they are flat and not as visible when a person stands up, because gravity encourages venous drainage. By inspecting the jugular veins for pulsations

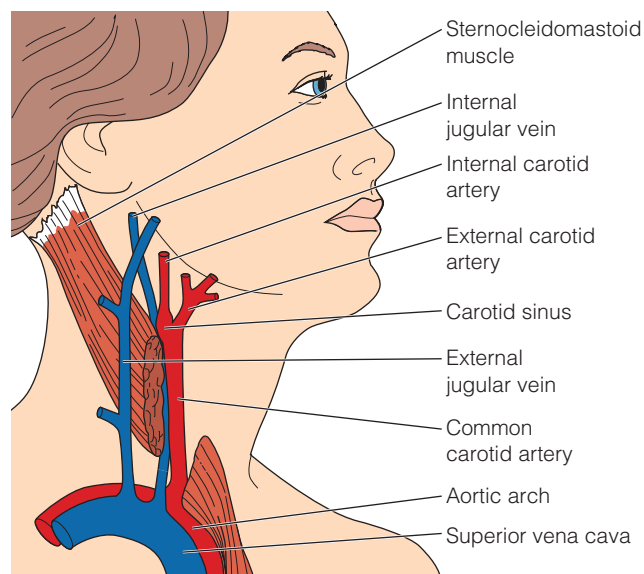


Figure 30–30 ■ Arteries and veins of the right side of the neck.

and distention, the nurse can assess the adequacy of function of the right side of the heart and venous pressure. Bilateral jugular venous distention (JVD) may indicate right-sided heart failure. Skill 30–12 describes how to assess the heart and central vessels.

## Assessing the Heart and Central Vessels

### PLANNING

Heart examination is usually performed while the client is in a semi-reclined position. The practitioner usually stands at the client's right side and auscultates and palpates with the right hand but this may be reversed if the nurse is left-handed.

### DELEGATION

Due to the substantial knowledge and skill required, assessment of the heart and central vessels is not delegated to UAP. However, many aspects of cardiac function are observed during usual care and may be recorded by individuals other than the nurse. Abnormal findings must be validated and interpreted by the nurse.

### IMPLEMENTATION

#### Performance

1. Prior to performing the procedure, introduce self and verify the client's identity using agency protocol. Explain to the client what you are going to do, why it is necessary, and how he or she can participate. Discuss how the results will be used in planning further care or treatments.
2. Perform hand hygiene and observe other appropriate infection prevention procedures.
3. Provide for client privacy.
4. Inquire if the client has any of the following: family history of incidence and age of heart disease, high cholesterol levels, high blood pressure, stroke, obesity, congenital heart disease,

### Equipment



- Stethoscope
- Centimeter ruler

### INTERPROFESSIONAL PRACTICE

Assessing the heart and central vessels is within the scope of practice for many health care providers other than nurses. For example, physician assistants may assess the heart and central vessels before, during, and after treatment. Although these providers may verbally communicate their findings and plan to other health care team members, the nurse must also know where to locate their documentation in the client's medical record.

arterial disease, hypertension, and rheumatic fever; client's past history of rheumatic fever, heart murmur, heart attack, varicosities, or heart failure; present symptoms indicative of heart disease (e.g., fatigue, dyspnea, orthopnea, edema, cough, chest pain, palpitations, syncope, hypertension, wheezing, hemoptysis); presence of diseases that affect heart (e.g., obesity, diabetes, lung disease, endocrine disorders); lifestyle habits that are risk factors for cardiac disease (e.g., smoking, alcohol intake, eating and exercise patterns, areas and degree of stress perceived).

## Assessing the Heart and Central Vessels—continued

| Assessment                                                                                                                                                                                                                                                                                                                                                                                                                                                                                                                                                                                                                                                                                                                                                                                                                                                                                                                                                                                                                                                                       | Normal Findings                                                                                                                                                                                                                                                                          | Deviations from Normal                                                                                                                                                                                                          |
|----------------------------------------------------------------------------------------------------------------------------------------------------------------------------------------------------------------------------------------------------------------------------------------------------------------------------------------------------------------------------------------------------------------------------------------------------------------------------------------------------------------------------------------------------------------------------------------------------------------------------------------------------------------------------------------------------------------------------------------------------------------------------------------------------------------------------------------------------------------------------------------------------------------------------------------------------------------------------------------------------------------------------------------------------------------------------------|------------------------------------------------------------------------------------------------------------------------------------------------------------------------------------------------------------------------------------------------------------------------------------------|---------------------------------------------------------------------------------------------------------------------------------------------------------------------------------------------------------------------------------|
| <p>5. Simultaneously inspect and palpate the precordium for the presence of abnormal pulsations, lifts, or heaves. Locate the valve areas of the heart:</p> <ul style="list-style-type: none"> <li>• Locate the angle of Louis. It is felt as a prominence on the sternum.</li> <li>• Move your fingertips down each side of the angle until you can feel the second intercostal spaces. The client's right second intercostal space is the aortic area, and the left second intercostal space is the pulmonic area. ❶ From the pulmonic area, move your fingertips down three left intercostal spaces along the side of the sternum. The left fifth intercostal space close to the sternum is the tricuspid or right ventricular area.</li> <li>• From the tricuspid area, move your fingertips laterally 5 to 7 cm (2 to 3 in.) to the left midclavicular line. ❷ This is the apical or mitral area, or point of maximal impulse (PMI). If you have difficulty locating the PMI, have the client roll onto the left side to move the apex closer to the chest wall.</li> </ul> |  <p>❶ Second intercostal space.<br/>Shirlee Snyder.</p>  <p>❷ Fifth intercostal space, MCL.<br/>Shirlee Snyder.</p> |                                                                                                                                                                                                                                 |
| <ul style="list-style-type: none"> <li>• Inspect and palpate the aortic and pulmonic areas, observing them at an angle and to the side, to note the presence or absence of pulsations. Observing these areas at an angle increases the likelihood of seeing pulsations.</li> </ul>                                                                                                                                                                                                                                                                                                                                                                                                                                                                                                                                                                                                                                                                                                                                                                                               | No pulsations                                                                                                                                                                                                                                                                            | Pulsations                                                                                                                                                                                                                      |
| <ul style="list-style-type: none"> <li>• Inspect and palpate the tricuspid area for pulsations and heaves or lifts.</li> </ul>                                                                                                                                                                                                                                                                                                                                                                                                                                                                                                                                                                                                                                                                                                                                                                                                                                                                                                                                                   | No pulsations<br>No lift or heave                                                                                                                                                                                                                                                        | Pulsations<br>Diffuse lift or heave, indicating enlarged or overactive right ventricle                                                                                                                                          |
| <ul style="list-style-type: none"> <li>• Inspect and palpate the apical area for pulsation, noting its specific location (it may be displaced laterally or lower) and diameter. If displaced laterally, record the distance between the apex and the MCL in centimeters.</li> </ul>                                                                                                                                                                                                                                                                                                                                                                                                                                                                                                                                                                                                                                                                                                                                                                                              | Pulsations visible in 50% of adults and palpable in most<br>PMI in fifth LICS at or medial to MCL<br><br>Diameter of 1 to 2 cm (0.4 to 0.8 in.)<br><br>No lift or heave                                                                                                                  | PMI displaced laterally or lower indicates enlarged heart<br>Diameter over 2 cm (0.8 in.) indicates enlarged heart or aneurysm<br>Diffuse lift or heave lateral to apex indicates enlargement or overactivity of left ventricle |
| <ul style="list-style-type: none"> <li>• Inspect and palpate the epigastric area at the base of the sternum for abdominal aortic pulsations.</li> </ul>                                                                                                                                                                                                                                                                                                                                                                                                                                                                                                                                                                                                                                                                                                                                                                                                                                                                                                                          | Aortic pulsations                                                                                                                                                                                                                                                                        | Bounding abdominal pulsations (e.g., aortic aneurysm)                                                                                                                                                                           |

Continued on page 564

## Assessing the Heart and Central Vessels—continued

| Assessment                                                                                                                                                                                                                                                                                                                                                                                                                                                                                                                                                                                                                                                                                                                                                                                                                                                                                                                                                                                                                                                                                                                                                                                                                                                                                                                                                                                                                                                                                                                                                                                                                                                                                                                                                                                                                                                                                                                                                                                                                                                                                                                                                                                                                                                                                                                                                                                                            | Normal Findings                                                                                                                                                                                                                                                                                                                                                                                                                                                                                                                                                                                                                                                                                                                   | Deviations from Normal                                                                                                                                                                                                                                                                                                                                                                                                                                                                                                                                                                                                        |
|-----------------------------------------------------------------------------------------------------------------------------------------------------------------------------------------------------------------------------------------------------------------------------------------------------------------------------------------------------------------------------------------------------------------------------------------------------------------------------------------------------------------------------------------------------------------------------------------------------------------------------------------------------------------------------------------------------------------------------------------------------------------------------------------------------------------------------------------------------------------------------------------------------------------------------------------------------------------------------------------------------------------------------------------------------------------------------------------------------------------------------------------------------------------------------------------------------------------------------------------------------------------------------------------------------------------------------------------------------------------------------------------------------------------------------------------------------------------------------------------------------------------------------------------------------------------------------------------------------------------------------------------------------------------------------------------------------------------------------------------------------------------------------------------------------------------------------------------------------------------------------------------------------------------------------------------------------------------------------------------------------------------------------------------------------------------------------------------------------------------------------------------------------------------------------------------------------------------------------------------------------------------------------------------------------------------------------------------------------------------------------------------------------------------------|-----------------------------------------------------------------------------------------------------------------------------------------------------------------------------------------------------------------------------------------------------------------------------------------------------------------------------------------------------------------------------------------------------------------------------------------------------------------------------------------------------------------------------------------------------------------------------------------------------------------------------------------------------------------------------------------------------------------------------------|-------------------------------------------------------------------------------------------------------------------------------------------------------------------------------------------------------------------------------------------------------------------------------------------------------------------------------------------------------------------------------------------------------------------------------------------------------------------------------------------------------------------------------------------------------------------------------------------------------------------------------|
| <p>6. Auscultate the heart in all four anatomic sites: aortic, pulmonic, tricuspid, and apical (mitral). Auscultation need not be limited to these areas; however, the nurse may need to move the stethoscope to find the most audible sounds for each client.</p> <ul style="list-style-type: none"> <li>Eliminate all sources of room noise.</li> <li><b>Rationale:</b> <i>Heart sounds are of low intensity, and other noise hinders the nurse's ability to hear them.</i></li> <li>Keep the client in a supine position with head elevated 15° to 45°.</li> <li>Use both the diaphragm and the bell to listen to all areas.</li> <li>In every area of auscultation, distinguish both S<sub>1</sub> and S<sub>2</sub> sounds.</li> <li>When auscultating, concentrate on one particular sound at a time in each area: the first heart sound, followed by systole, then the second heart sound, then diastole. Systole and diastole are normally silent intervals.</li> <li>Later, reexamine the heart while the client is in the upright sitting position.</li> <li><b>Rationale:</b> <i>Certain sounds are more audible in certain positions.</i></li> </ul> <p><b>CAROTID ARTERIES</b></p> <p>7. Palpate the carotid artery, using extreme caution.</p> <ul style="list-style-type: none"> <li>Palpate only one carotid artery at a time. <b>Rationale:</b> <i>This ensures adequate blood flow through the other artery to the brain.</i></li> <li>Avoid exerting too much pressure or massaging the area. <b>Rationale:</b> <i>Pressure can occlude the artery, and carotid sinus massage can precipitate bradycardia.</i> The carotid sinus is a small dilation at the beginning of the internal carotid artery just above the bifurcation of the common carotid artery, in the upper third of the neck.</li> <li>Ask the client to turn the head slightly toward the side being examined. This makes the carotid artery more accessible.</li> </ul> <p>8. Auscultate the carotid artery.</p> <ul style="list-style-type: none"> <li>Turn the client's head slightly away from the side being examined.</li> <li><b>Rationale:</b> <i>This facilitates placement of the stethoscope.</i></li> <li>Auscultate the carotid artery on one side and then the other.</li> <li>Listen for the presence of a bruit. If you hear a bruit, gently palpate the artery to determine the presence of a thrill.</li> </ul> | <p>S<sub>1</sub>: usually heard at all sites<br/>Usually louder at apical area</p> <p>S<sub>2</sub>: usually heard at all sites<br/>Usually louder at base of heart</p> <p>Systole: silent interval; slightly shorter duration than diastole at normal heart rate (60 to 90 beats/min)</p> <p>Diastole: silent interval; slightly longer duration than systole at normal heart rates</p> <p>S<sub>3</sub> in children and young adults<br/>S<sub>4</sub> in many older adults</p> <p>Symmetric pulse volumes</p> <p>Full pulsations, thrusting quality<br/>Quality remains same when client breathes, turns head, and changes from sitting to supine position<br/>Elastic arterial wall</p> <p>No sound heard on auscultation</p> | <p>Increased or decreased intensity<br/>Varying intensity with different beats<br/>Increased intensity at aortic area<br/>Increased intensity at pulmonic area<br/>Sharp-sounding ejection clicks</p> <p>S<sub>3</sub> in older adults<br/>S<sub>4</sub> may be a sign of hypertension</p> <p>Asymmetric volumes (possible stenosis or thrombosis)<br/>Decreased pulsations (may indicate impaired left cardiac output)<br/>Increased pulsations</p> <p>Thickening, hard, rigid, beaded, inelastic walls (indicate arteriosclerosis)</p> <p>Presence of bruit in one or both arteries (suggests occlusive artery disease)</p> |

## Assessing the Heart and Central Vessels—continued

| Assessment                                                                                                                                                                                                                                                                                                                                                                                                                                                                                                                                                                                                                                                                                                                                                                                                                                                                                                                                                                                                                                                         | Normal Findings                                                                   | Deviations from Normal                                                                                                                                                                                                                                                         |
|--------------------------------------------------------------------------------------------------------------------------------------------------------------------------------------------------------------------------------------------------------------------------------------------------------------------------------------------------------------------------------------------------------------------------------------------------------------------------------------------------------------------------------------------------------------------------------------------------------------------------------------------------------------------------------------------------------------------------------------------------------------------------------------------------------------------------------------------------------------------------------------------------------------------------------------------------------------------------------------------------------------------------------------------------------------------|-----------------------------------------------------------------------------------|--------------------------------------------------------------------------------------------------------------------------------------------------------------------------------------------------------------------------------------------------------------------------------|
| <p><b>JUGULAR VEINS</b></p> <p>9. Inspect the jugular veins for distention while the client is placed in the semi-Fowler's position (15° to 45° angle), with the head supported on a small pillow.</p> <p>10. If jugular distention is present, assess the jugular venous pressure (JVP).</p> <ul style="list-style-type: none"> <li>Locate the highest visible point of distention of the internal jugular vein. Although either the internal or the external jugular vein can be used, the internal jugular vein is more reliable.</li> </ul> <p><b>Rationale:</b> <i>The external jugular vein is more easily affected by obstruction or kinking at the base of the neck.</i></p> <ul style="list-style-type: none"> <li>Measure the vertical height of this point in centimeters from the sternal angle, the point at which the clavicles meet. 3 Repeat the preceding steps on the other side.</li> </ul> <p>11. Document findings in the client record using printed or electronic forms or checklists supplemented by narrative notes when appropriate.</p> | <p>Veins not visible (indicating right side of heart is functioning normally)</p> | <p>Veins visibly distended (indicating advanced cardiopulmonary disease)</p> <p>Bilateral measurements above 3 to 4 cm (1.2 to 1.6 in.) are considered elevated (may indicate right-sided heart failure)</p> <p>Unilateral distention (may be caused by local obstruction)</p> |
| <p>3 Assessing the highest point of distention of the jugular vein.</p>                                                                                                                                                                                                                                                                                                                                                                                                                                                                                                                                                                                                                                                                                                                                                                                                                                                                                                                                                                                            |                                                                                   |                                                                                                                                                                                                                                                                                |

**EVALUATION**

- Perform a detailed follow-up examination of other systems based on findings that deviated from expected or normal for the client. Relate findings to previous assessment data if available.
- Report deviations from expected or normal findings to the primary care provider.

**LIFESPAN CONSIDERATIONS** Assessing the Heart and Central Vessels**INFANTS**

- Physiological splitting of the second heart sound ( $S_2$ ) may be heard when the child takes a deep breath and the aortic valve closes a split second before the pulmonic valve. If splitting of  $S_2$  is heard during normal respirations, it is abnormal and may indicate an atrial-septal defect, pulmonary stenosis, or another heart problem.
- Infants may normally have sinus arrhythmia that is related to respiration. The heart rate slows during expiration and increases when the child breathes in.
- Murmurs may be heard in newborns as the structures of fetal circulation, especially the ductus arteriosus, close.

**CHILDREN**

- Heart sounds may be louder because of the thinner chest wall.
- A third heart sound ( $S_3$ ), caused as the ventricles fill, is best heard at the apex, and is present in about one third of all children.

- The PMI is higher and more medial in children under 8 years old.

**OLDER ADULTS**

- If no disease is present, heart size remains the same size throughout life.
- Cardiac output and strength of contraction decrease, thus lessening the older person's activity tolerance.
- The heart rate returns to its resting rate more slowly after exertion than it did when the individual was younger.
- $S_4$  heart sound is considered normal in older adults.
- Extra systoles commonly occur. Ten or more systoles per minute are considered abnormal.
- Sudden emotional and physical stresses may result in cardiac arrhythmias and heart failure.

## Peripheral Vascular System

Assessing the peripheral vascular system includes measuring the blood pressure, palpating peripheral pulses, and inspecting the skin and tissues to determine **perfusion** (blood supply to an area) to the extremities. Certain aspects of peripheral vascular assessment are often incorporated

into other parts of the assessment procedure. For example, blood pressure is usually measured at the beginning of the physical examination (see the section on assessing blood pressure in Chapter 29 ∞). Pulse sites and pulse assessments are described in Chapter 29 ∞. Skill 30–13 describes how to assess the peripheral vascular system.

### Assessing the Peripheral Vascular System

#### PLANNING DELEGATION

Due to the substantial knowledge and skill required, assessment of the peripheral vascular system is not delegated to UAP. However, many aspects of the vascular system are observed during usual care and may be recorded by individuals other than the nurse. Abnormal findings must be validated and interpreted by the nurse.

#### Equipment

None

#### IMPLEMENTATION Performance

1. Prior to performing the procedure, introduce self and verify the client's identity using agency protocol. Explain to the client what you are going to do, why it is necessary, and how he or she can participate. Discuss how the results will be used in planning further care or treatments.
2. Perform hand hygiene and observe other appropriate infection prevention procedures.

#### INTERPROFESSIONAL PRACTICE

Assessing the peripheral vascular system is within the scope of practice for many health care providers other than nurses. For example, occupational and physical therapists may check the client's pulses before treatment. Although these providers may verbally communicate their findings and plan to other health care team members, the nurse must also know where to locate their documentation in the client's medical record.

3. Provide for client privacy.
4. Inquire if the client has any of the following: past history of heart disorders, varicosities, arterial disease, and hypertension; lifestyle habits such as exercise patterns, activity patterns and tolerance, smoking, and use of alcohol.

| Assessment                                                                                                                                                                                                                                                                                                                                                                                                                                                                                                                                                                                                                                                                                                | Normal Findings                                                                                                                                                                    | Deviations from Normal                                                                                                                                                                                                                                                                                                                                                                                |
|-----------------------------------------------------------------------------------------------------------------------------------------------------------------------------------------------------------------------------------------------------------------------------------------------------------------------------------------------------------------------------------------------------------------------------------------------------------------------------------------------------------------------------------------------------------------------------------------------------------------------------------------------------------------------------------------------------------|------------------------------------------------------------------------------------------------------------------------------------------------------------------------------------|-------------------------------------------------------------------------------------------------------------------------------------------------------------------------------------------------------------------------------------------------------------------------------------------------------------------------------------------------------------------------------------------------------|
| <b>PERIPHERAL PULSES</b>                                                                                                                                                                                                                                                                                                                                                                                                                                                                                                                                                                                                                                                                                  |                                                                                                                                                                                    |                                                                                                                                                                                                                                                                                                                                                                                                       |
| <p>5. Palpate the peripheral pulses on both sides of the client's body individually, simultaneously (except the carotid pulse), and systematically to determine the symmetry of pulse volume. If you have difficulty palpating some of the peripheral pulses, use a Doppler ultrasound probe.</p>                                                                                                                                                                                                                                                                                                                                                                                                         | <p>Symmetric pulse volumes<br/>Full pulsations</p>                                                                                                                                 | <p>Asymmetric volumes (indicate impaired circulation)<br/>Absence of pulsation (indicates arterial spasm or occlusion)<br/>Decreased, weak, thready pulsations (indicate impaired cardiac output)<br/>Increased pulse volume (may indicate hypertension, high cardiac output, or circulatory overload)</p>                                                                                            |
| <b>PERIPHERAL VEINS</b>                                                                                                                                                                                                                                                                                                                                                                                                                                                                                                                                                                                                                                                                                   |                                                                                                                                                                                    |                                                                                                                                                                                                                                                                                                                                                                                                       |
| <p>6. Inspect the peripheral veins in the arms and legs for the presence and/or appearance of superficial veins when limbs are dependent and when limbs are elevated.</p>                                                                                                                                                                                                                                                                                                                                                                                                                                                                                                                                 | <p>In dependent position, presence of distention and nodular bulges at calves<br/>When limbs elevated, veins collapse (veins may appear tortuous or distended in older people)</p> | <p>Distended veins in the thigh and/or lower leg or on posterolateral part of calf from knee to ankle</p>                                                                                                                                                                                                                                                                                             |
| <p>7. Assess the peripheral leg veins for signs of phlebitis.</p> <ul style="list-style-type: none"> <li>• Inspect the calves for redness and swelling over vein sites.</li> <li>• Palpate the calves for firmness or tension of the muscles, the presence of edema over the dorsum of the foot, and areas of localized warmth. <b>Rationale:</b> <i>Palpation augments inspection findings, particularly in darker pigmented people in whom redness may not be visible.</i></li> <li>• Push the calves from side to side to test for tenderness.</li> <li>• Firmly dorsiflex the client's foot while supporting the entire leg in extension (Homans' test), or have the person stand or walk.</li> </ul> | <p>Symmetric in size<br/>Limbs not tender</p>                                                                                                                                      | <p>Swelling of one calf or leg<br/>Tenderness on palpation<br/>Pain in calf muscles with forceful dorsiflexion of the foot (positive Homans' test)<br/>Warmth and redness over vein<br/>No one sign or symptom consistently confirms or excludes the presence of phlebitis or a deep venous thrombosis. Homans' sign has been found to give inconsistent results (D'Amico &amp; Barbarito, 2012).</p> |

## Assessing the Peripheral Vascular System—continued

| Assessment                                                                                                                                                                                                                                                                                | Normal Findings                                                                                                                                                                                                                                                                                                                         | Deviations from Normal                                                                                                                                                                                                                                                                                                                                                                                                                                                                                                                |
|-------------------------------------------------------------------------------------------------------------------------------------------------------------------------------------------------------------------------------------------------------------------------------------------|-----------------------------------------------------------------------------------------------------------------------------------------------------------------------------------------------------------------------------------------------------------------------------------------------------------------------------------------|---------------------------------------------------------------------------------------------------------------------------------------------------------------------------------------------------------------------------------------------------------------------------------------------------------------------------------------------------------------------------------------------------------------------------------------------------------------------------------------------------------------------------------------|
| <b>PERIPHERAL PERFUSION</b>                                                                                                                                                                                                                                                               |                                                                                                                                                                                                                                                                                                                                         |                                                                                                                                                                                                                                                                                                                                                                                                                                                                                                                                       |
| 8. Inspect the skin of the hands and feet for color, temperature, edema, and skin changes.                                                                                                                                                                                                | <p>Skin color pink</p> <p>Skin temperature not excessively warm or cold</p> <p>No edema</p> <p>Skin texture resilient and moist</p>                                                                                                                                                                                                     | <p>Cyanotic (venous insufficiency)</p> <p>Pallor that increases with limb elevation</p> <p>Dependent rubor, a dusky red color when limb is lowered (arterial insufficiency)</p> <p>Brown pigmentation around ankles (arterial or chronic venous insufficiency)</p> <p>Skin cool (arterial insufficiency)</p> <p>Marked edema (venous insufficiency)</p> <p>Mild edema (arterial insufficiency)</p> <p>Skin thin and shiny or thick, waxy, shiny, and fragile, with reduced hair and ulceration (venous or arterial insufficiency)</p> |
| 9. Assess the adequacy of arterial flow if arterial insufficiency is suspected.                                                                                                                                                                                                           |                                                                                                                                                                                                                                                                                                                                         |                                                                                                                                                                                                                                                                                                                                                                                                                                                                                                                                       |
| <b>CAPILLARY REFILL TEST</b>                                                                                                                                                                                                                                                              |                                                                                                                                                                                                                                                                                                                                         |                                                                                                                                                                                                                                                                                                                                                                                                                                                                                                                                       |
| <ul style="list-style-type: none"> <li>Press at least one nail on each hand and foot between your thumb and index finger sufficiently to cause blanching (about 5 seconds).</li> <li>Release the pressure, and observe how quickly normal color returns (less than 2 seconds).</li> </ul> | Immediate return of color                                                                                                                                                                                                                                                                                                               | Delayed return of color (arterial insufficiency)                                                                                                                                                                                                                                                                                                                                                                                                                                                                                      |
| <b>OTHER ASSESSMENTS</b>                                                                                                                                                                                                                                                                  |                                                                                                                                                                                                                                                                                                                                         |                                                                                                                                                                                                                                                                                                                                                                                                                                                                                                                                       |
| <ul style="list-style-type: none"> <li>Inspect the fingernails for changes indicative of circulatory impairment. See the section on assessment of nails earlier in this chapter.</li> <li>See also peripheral pulse assessment earlier.</li> </ul>                                        |                                                                                                                                                                                                                                                                                                                                         |                                                                                                                                                                                                                                                                                                                                                                                                                                                                                                                                       |
| 10. Document findings in the client record using printed or electronic forms or checklists supplemented by narrative notes when appropriate.                                                                                                                                              | <p><b>SAMPLE DOCUMENTATION</b></p> <hr/> <p>5/28/15 0830 Legs mottled red bilaterally toes to mid-calf. States “actually looks a bit better.” Capillary refill 4–5 seconds in toes on both feet. Pedal pulses present but weak. Homans’ test negative. c/o pain in calves after walking 100 feet.</p> <p>_____ N. Schmidt, RN</p> <hr/> |                                                                                                                                                                                                                                                                                                                                                                                                                                                                                                                                       |

### EVALUATION

- Perform a detailed follow-up examination of other systems based on findings that deviated from expected or normal for the client. Relate findings to previous assessment data if available.
- Report deviations from expected or normal findings to the primary care provider.

## LIFESPAN CONSIDERATIONS Assessing the Peripheral Vascular System

### INFANTS

- Screen for coarctation of the aorta by palpating the peripheral pulses and comparing the strength of the femoral pulses with the radial pulses and apical pulse. If coarctation is present, femoral pulses will be diminished and radial pulses will be stronger.

### CHILDREN

- Changes in the peripheral vasculature, such as bruising, petechiae, and purpura, can indicate serious systemic diseases in children (e.g., leukemia, meningococemia).

### OLDER ADULTS

- The overall efficiency of blood vessels decreases as smooth muscle cells are replaced by connective tissue. The lower extremities are more likely to show signs of arterial and venous impairment because of the more distal and dependent position.
- Peripheral vascular assessment should always include upper and lower extremities’ temperature, color, pulses, edema, skin integrity, and sensation. Any differences in symmetry of these findings should be noted.

**LIFESPAN CONSIDERATIONS** Assessing the Peripheral Vascular System—*continued*

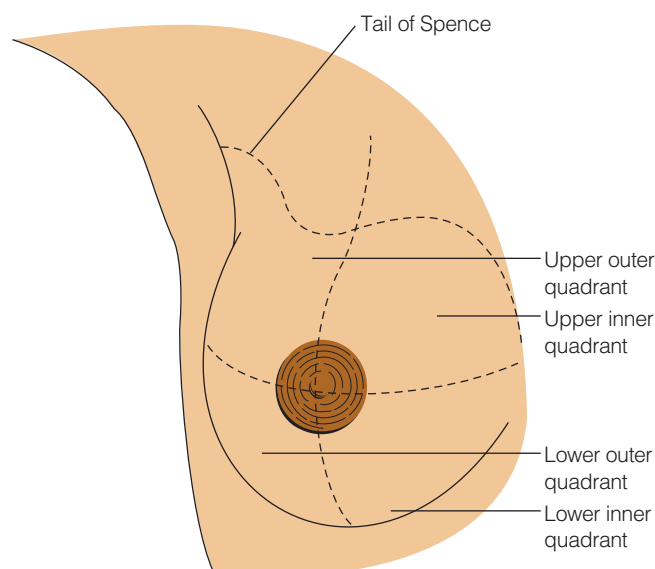
- Proximal arteries become thinner and dilate.
- Peripheral arteries become thicker and dilate less effectively because of arteriosclerotic changes in the vessel walls.
- Blood vessels lengthen and become more tortuous and prominent. Varicosities occur more frequently.
- In some instances, arteries may be palpated more easily because of the loss of supportive surrounding tissues. Often, however, the most distal pulses of the lower extremities are more difficult to palpate because of decreased arterial perfusion.
- Systolic and diastolic blood pressures increase, but the increase in the systolic pressure is greater. As a result, the pulse pressure widens. Any client with a blood pressure reading above 140/90 mmHg should be referred for follow-up assessments.
- Peripheral edema is frequently observed and is most commonly the result of chronic venous insufficiency or low protein levels in the blood (hypoproteinemia).

**Home Care Considerations** Assessing the Peripheral Vascular System**PATIENT-CENTERED CARE**

- Use the assessment as an opportunity to provide teaching regarding appropriate care of the extremities in those at high risk for or with actual vascular impairment. Educate clients and families regarding skin and nail care, exercise, and positioning to promote circulation.

**BREASTS AND AXILLAE**

The breasts of men and women need to be inspected and palpated. Men have some glandular tissue beneath each nipple, a potential site for malignancy, whereas mature women have glandular tissue throughout the breast. In females, the largest portion of glandular breast tissue is located in the upper outer quadrant of each breast. A projection of breast tissue from this quadrant extends into the *axilla*, called the *axillary tail of Spence* (Figure 30–31 ■). The majority of breast tumors are located in this upper outer breast quadrant including the tail of Spence. During assessment, the nurse can localize specific findings by dividing the breast into quadrants and the axillary tail. Skill 30–14 describes how to assess the breasts and axillae.



**Figure 30–31** ■ The four breast quadrants and the axillary tail of Spence.

**Assessing the Breasts and Axillae****PLANNING**  
**DELEGATION**

Due to the substantial knowledge and skill required, assessment of the breasts and axillae is not delegated to UAP. However, individuals other than the nurse may record aspects observed during usual care. Abnormal findings must be validated and interpreted by the nurse.

**Equipment**

- Centimeter ruler

**IMPLEMENTATION****Performance**

1. Prior to performing the procedure, introduce self and verify the client's identity using agency protocol. Explain to the client what you are going to do, why it is necessary, and how he or she can participate. Inquire whether the client has ever had a clinical

**INTERPROFESSIONAL PRACTICE**

Assessing the breasts and axillae is within the scope of practice for a few health care providers other than nurses. For example, physician assistants may check the client's breasts during their health assessment. Although these providers may verbally communicate their findings and plan to other health care team members, the nurse must also know where to locate their documentation in the client's medical record.

2. Perform hand hygiene and observe other appropriate infection prevention procedures.



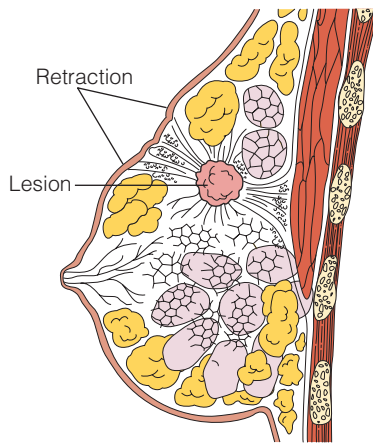
## Assessing the Breasts and Axillae—continued

3. Provide for client privacy.
4. Inquire if the client has any history of the following: breast masses and what was done about them; pain or tenderness in the breasts and relation to the woman's menstrual cycle; discharge from the nipple; medication history (some medications, e.g., oral contraceptives, steroids, digitalis, and diuretics, may cause nipple discharge; estrogen replacement therapy may be associated with

the development of cysts or cancer); risk factors that may be associated with development of breast cancer (e.g., mother, sister, aunt with breast cancer; alcohol consumption, high-fat diet, obesity, use of oral contraceptives, menarche before age 12, menopause after age 55, age 30 or more at first pregnancy). Inquire if the client performs breast self-examination; technique used and when performed in relation to the menstrual cycle.

### Assessment

5. Inspect the breasts for size, symmetry, and contour while the client is in a sitting position.
6. Inspect the skin of the breast for localized discolorations or hyperpigmentation, retraction or dimpling, localized hypervascular areas, swelling or edema. ①



① A lesion causing retraction of the skin.

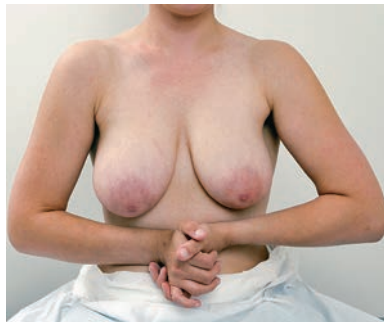7. Emphasize any retraction by having the client:
  - Raise the arms above the head.
  - Push the hands together, with elbows flexed. ②
  - Press the hands down on the hips. ③
8. Inspect the areola area for size, shape, symmetry, color, surface characteristics, and any masses or lesions.
9. Inspect the nipples for size, shape, position, color, discharge, and lesions.

### Normal Findings

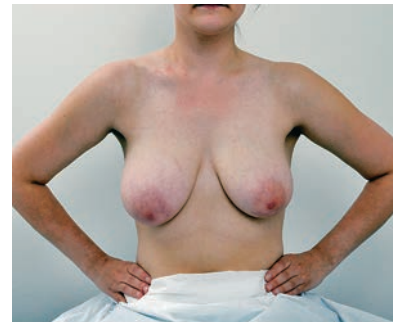*Females:* rounded shape; slightly unequal in size; generally symmetric  
*Males:* breasts even with the chest wall; if obese, may be similar in shape to female breasts  
 Skin uniform in color (similar to skin of abdomen if not tanned)  
 Skin smooth and intact  
 Diffuse symmetric horizontal or vertical vascular pattern in light-skinned people  
 Striae (stretch marks); moles and nevi

### Deviations from Normal

Recent change in breast size; swellings; marked asymmetry  
 Localized discolorations or hyperpigmentation  
 Retraction or dimpling (result of scar tissue or an invasive tumor)  
 Unilateral, localized hypervascular areas (associated with increased blood flow)  
 Swelling or edema appearing as pig skin or orange peel due to exaggeration of the pores



② Pushing the hands together to accentuate retraction of breast tissue.

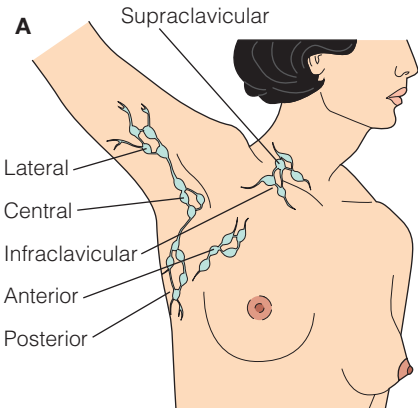

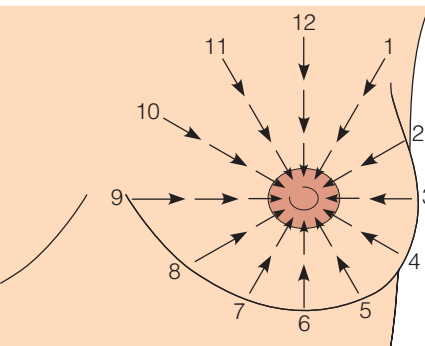
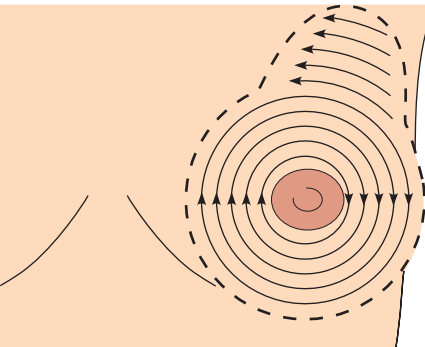
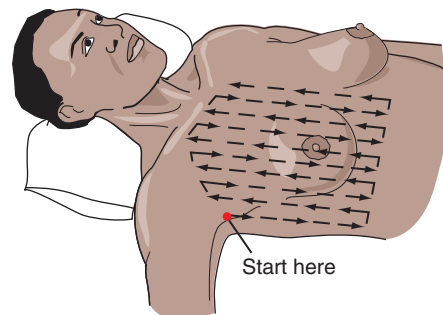


③ Pressing the hands down on the hips to accentuate retraction of breast tissue.


Round or oval and bilaterally the same  
 Color varies widely, from light pink to dark brown  
 Irregular placement of sebaceous glands on the surface of the areola (Montgomery's tubercles)  
 Round, everted, and equal in size; similar in color; soft and smooth; both nipples point in same direction (out in young women and men, downward in older women)  
 No discharge, except from pregnant or breast-feeding females  
 Inversion of one or both nipples that is present from puberty

Any asymmetry, mass, or lesion  
 Asymmetrical size and color  
 Presence of discharge, crusts, or cracks  
 Recent inversion of one or both nipples

## Assessing the Breasts and Axillae—continued

| Assessment                                                                                                                                                                                                                                                                                                                                                                                                                                                                                                                                                                                                                                                                                                                                                                                                                                                                                                                                                                                                                                                                                                                                                                                                                                                                                                                                                                                                                                                                                                                                                   | Normal Findings                                                                                                                                                                                                                                                                                                                                                                         | Deviations from Normal                                                                                                                                                                                                                                                                                                                                                                                                                                                                                                                                                                                                                                                                                                                                                                                                                                                                                                                                                                                                                                                                                                  |
|--------------------------------------------------------------------------------------------------------------------------------------------------------------------------------------------------------------------------------------------------------------------------------------------------------------------------------------------------------------------------------------------------------------------------------------------------------------------------------------------------------------------------------------------------------------------------------------------------------------------------------------------------------------------------------------------------------------------------------------------------------------------------------------------------------------------------------------------------------------------------------------------------------------------------------------------------------------------------------------------------------------------------------------------------------------------------------------------------------------------------------------------------------------------------------------------------------------------------------------------------------------------------------------------------------------------------------------------------------------------------------------------------------------------------------------------------------------------------------------------------------------------------------------------------------------|-----------------------------------------------------------------------------------------------------------------------------------------------------------------------------------------------------------------------------------------------------------------------------------------------------------------------------------------------------------------------------------------|-------------------------------------------------------------------------------------------------------------------------------------------------------------------------------------------------------------------------------------------------------------------------------------------------------------------------------------------------------------------------------------------------------------------------------------------------------------------------------------------------------------------------------------------------------------------------------------------------------------------------------------------------------------------------------------------------------------------------------------------------------------------------------------------------------------------------------------------------------------------------------------------------------------------------------------------------------------------------------------------------------------------------------------------------------------------------------------------------------------------------|
| <p>10. Palpate the axillary, subclavicular, and supraclavicular lymph nodes <b>4</b> while the client sits with the arms abducted and supported on the nurse's forearm. See discussion on palpation of clavicular lymph nodes in Skill 30-10. Use the flat surfaces of all fingertips to palpate the four areas of the axilla:</p> <ul style="list-style-type: none"> <li>• The edge of the greater pectoral muscle (musculus pectoralis major) along the anterior axillary line</li> <li>• The thoracic wall in the midaxillary area</li> <li>• The upper part of the humerus</li> <li>• The anterior edge of the latissimus dorsi muscle along the posterior axillary line.</li> </ul>                                                                                                                                                                                                                                                                                                                                                                                                                                                                                                                                                                                                                                                                                                                                                                                                                                                                     | <p>No tenderness, masses, or nodules</p>  <p><b>4</b> Location and palpation of the lymph nodes that drain the lateral breast: A, lymph nodes; B, palpating the axilla.</p>                                                                                                                            | <p>Tenderness, masses, or nodules</p>                                                                                                                                                                                                                                                                                                                                                                                                                                                                                                                                                                                                                                                                                                                                                                                                                                                                                                                                                                                                |
| <p>11. Palpate the breast for masses, tenderness, and any discharge from the nipples. Palpation of the breast is generally performed while the client is supine. <b>Rationale:</b> <i>In the supine position, the breasts flatten evenly against the chest wall, facilitating palpation.</i> For clients who have a past history of breast masses, who are at high risk for breast cancer, or who have pendulous breasts, examination in both a supine and a sitting position is recommended.</p> <ul style="list-style-type: none"> <li>• If the client reports a breast lump, start with the “normal” breast to obtain baseline data that will serve as a comparison to the reportedly involved breast.</li> <li>• To enhance flattening of the breast, instruct the client to abduct the arm and place her hand behind her head. Then place a small pillow or rolled towel under the client's shoulder.</li> <li>• For palpation, use the palmar surface of the middle three fingertips (held together) and make a gentle rotary motion on the breast.</li> <li>• Choose one of three patterns for palpation: <ul style="list-style-type: none"> <li>a. Hands-of-the-clock or spokes-on-a-wheel <b>5</b></li> <li>b. Concentric circles <b>6</b></li> <li>c. Vertical strips pattern. <b>7</b></li> </ul> </li> <li>• Start at one point for palpation, and move systematically to the end point to ensure that all breast surfaces are assessed.</li> <li>• Pay particular attention to the upper outer quadrant area and the tail of Spence.</li> </ul> | <p>No tenderness, masses, nodules, or nipple discharge</p>  <p><b>5</b> Hands-of-the-clock or spokes-on-a-wheel pattern of breast palpation.</p>  <p><b>6</b> Concentric circles pattern of breast palpation.</p> | <p>Tenderness, masses, nodules, or nipple discharge</p> <ul style="list-style-type: none"> <li>• If you detect a mass, record the following data: <ol style="list-style-type: none"> <li><b>Location:</b> the exact location relative to the quadrants and axillary tail, or the clock <b>5</b> and the distance from the nipple in centimeters.</li> <li><b>Size:</b> the length, width, and thickness of the mass in centimeters. If you are able to determine the discrete edges, record this fact.</li> <li><b>Shape:</b> whether the mass is round, oval, lobulated, indistinct, or irregular.</li> <li><b>Consistency:</b> whether the mass is hard or soft.</li> <li><b>Mobility:</b> whether the mass is movable or fixed.</li> <li><b>Skin over the lump:</b> whether it is reddened, dimpled, or retracted.</li> <li><b>Nipple:</b> whether it is displaced or retracted.</li> <li><b>Tenderness:</b> whether palpation is painful.</li> </ol> </li> </ul>  <p><b>7</b> Vertical strips pattern of breast palpation.</p> |

## Assessing the Breasts and Axillae—continued

| Assessment                                                                                                                                                                                                                                                                                                                                                                                                                                                                                                                                                                                                                                                                                        | Normal Findings                                     | Deviations from Normal                           |
|---------------------------------------------------------------------------------------------------------------------------------------------------------------------------------------------------------------------------------------------------------------------------------------------------------------------------------------------------------------------------------------------------------------------------------------------------------------------------------------------------------------------------------------------------------------------------------------------------------------------------------------------------------------------------------------------------|-----------------------------------------------------|--------------------------------------------------|
| <p><b>12.</b> Palpate the areolae and the nipples for masses. Compress each nipple to determine the presence of any discharge. If discharge is present, milk the breast along its radius to identify the discharge-producing lobe. Assess any discharge for amount, color, consistency, and odor. Note also any tenderness on palpation.</p> <p><b>13.</b> If the client wishes, teach the technique of breast self-examination (see Chapter 40 .</p> <p><b>14.</b> Document findings in the client record using printed or electronic forms or checklists supplemented by narrative notes when appropriate.</p> | No tenderness, masses, nodules, or nipple discharge | Tenderness, masses, nodules, or nipple discharge |

### EVALUATION

- Perform a detailed follow-up examination of other systems based on findings that deviated from expected or normal for the client. Relate findings to previous assessment data if available.
- Report deviations from expected or normal findings to the primary care provider.

## LIFESPAN CONSIDERATIONS Assessing the Breasts and Axillae

### INFANTS

- Newborns up to 2 weeks of age, both boys and girls, may have breast enlargement and white discharge from the nipples (witch's milk).
- Supernumerary ("extra") nipples infrequently are present as small dimples along the mammary chain; these may be associated with renal anomalies.

### CHILDREN

- Female breast development begins between 9 and 13 years of age and occurs in five stages (Tanner stages). One breast may develop more rapidly than the other, but at the end of development, they are more or less the same size.
  - Stage 1:* prepubertal with no noticeable change
  - Stage 2:* breast bud with elevation of nipple and enlargement of the areola
  - Stage 3:* enlargement of the breast and areola with no separation of contour
  - Stage 4:* projection of the areola and nipple
  - Stage 5:* recession of the areola by about age 14 or 15, leaving only the nipple projecting.
- Boys may develop breast buds and have slight enlargement of the areola in early adolescence. Further enlargement of breast tissue (gynecomastia) can occur. This growth is transient,

usually lasting about 2 years, resolving completely by late puberty.

- Axillary hair usually appears in Tanner stages 3 or 4 and is related to adrenal rather than gonadal changes.

### PREGNANT FEMALES


- Breast, areola, and nipple size increase.
- The areolae and nipples darken; nipples may become more erect; areolae contain small, scattered, elevated Montgomery's glands.
- Superficial veins become more prominent, and jagged linear stretch marks may develop.
- A thick yellow fluid (colostrum) may be expressed from the nipples after the first trimester.

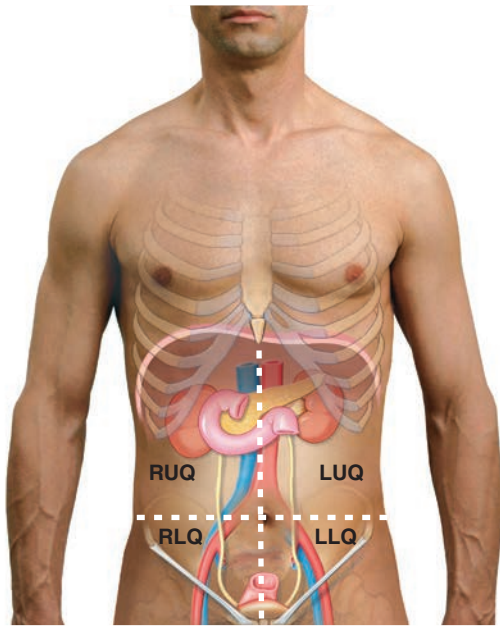
### OLDER ADULTS

- In the postmenopausal female, breasts change in shape and often appear pendulous or flaccid; they lack the firmness they had in younger years.
- The presence of breast lesions may be detected more readily because of the decrease in connective tissue.
- General breast size remains the same. Although glandular tissue atrophies, the amount of fat in breasts (predominantly in the lower quadrants) increases in most women.

## ABDOMEN

The nurse locates and describes abdominal findings using two common methods of subdividing the abdomen: quadrants and regions. To divide the abdomen into quadrants, the nurse imagines two lines: a vertical line from the xiphoid process to the pubic symphysis, and a horizontal line across the umbilicus

(Figure 30-32 ). These quadrants are labeled right upper quadrant, left upper quadrant, right lower quadrant, and left lower quadrant. Using the second method, division into nine regions, the nurse imagines two vertical lines that extend superiorly from the midpoints of the inguinal ligaments, and two horizontal lines, one at the level of the edge of the lower ribs



**Figure 30-32** ■ The four abdominal quadrants and the underlying organs: *RUQ*, right upper quadrant; *LUQ*, left upper quadrant; *RLQ*, right lower quadrant; *LLQ*, left lower quadrant.

### BOX 30-7 Organs in the Four Abdominal Quadrants

#### RIGHT UPPER QUADRANT

Liver  
Gallbladder  
Duodenum  
Head of pancreas  
Right adrenal gland  
Upper lobe of right kidney  
Hepatic flexure of colon  
Section of ascending colon  
Section of transverse colon

#### LEFT UPPER QUADRANT

Left lobe of liver  
Stomach  
Spleen  
Upper lobe of left kidney  
Pancreas  
Left adrenal gland  
Splenic flexure of colon  
Section of transverse colon  
Section of descending colon

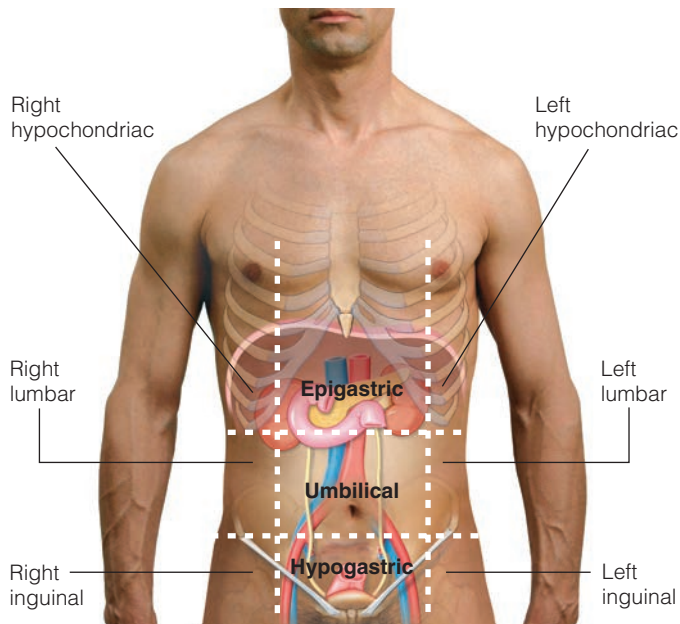
#### RIGHT LOWER QUADRANT

Lower lobe of right kidney  
Cecum  
Appendix  
Section of ascending colon  
Right ovary  
Right fallopian tube  
Right ureter  
Right spermatic cord  
Part of uterus

#### LEFT LOWER QUADRANT

Lower lobe of left kidney  
Sigmoid colon  
Section of descending colon  
Left ovary  
Left fallopian tube  
Left ureter  
Left spermatic cord  
Part of uterus

### BOX 30-8 Organs in the Nine Abdominal Regions



**Figure 30-33** ■ The nine abdominal regions: epigastric; left and right hypochondriac; umbilical; left and right lumbar; hypogastric; left and right inguinal or iliac.

#### RIGHT HYPOCHONDIAC

Right lobe of liver  
Gallbladder  
Part of duodenum  
Hepatic flexure of colon  
Upper half of right kidney  
Suprarenal gland

#### UMBILICAL

Omentum  
Mesentery  
Lower part of duodenum  
Part of jejunum and ileum

#### RIGHT LUMBAR

Ascending colon  
Lower half of right kidney  
Part of duodenum and jejunum

#### HYPOGASTRIC (PUBIC)

Ileum  
Bladder  
Uterus

#### RIGHT INGUINAL

Cecum  
Appendix  
Lower end of ileum  
Right ureter  
Right spermatic cord  
Right ovary

#### LEFT HYPOCHONDIAC

Stomach  
Spleen  
Tail of pancreas  
Splenic flexure of colon  
Upper half of left kidney  
Suprarenal gland

#### EPIGASTRIC

Aorta  
Pyloric end of stomach  
Part of duodenum  
Pancreas  
Part of liver

#### LEFT LUMBAR

Descending colon  
Lower half of left kidney  
Part of jejunum and ileum

#### LEFT INGUINAL

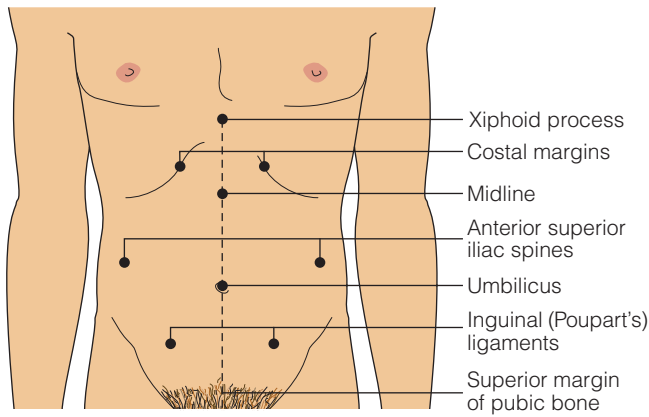
Sigmoid colon  
Left ureter  
Left spermatic cord  
Left ovary

and the other at the level of the iliac crests (Figure 30-33 ■). Specific organs or parts of organs lie in each abdominal region (Boxes 30-7 and 30-8).

In addition, practitioners often use certain landmarks to locate abdominal signs and symptoms. These are the xiphoid process of the

sternum, the costal margins, the anterosuperior iliac spine, the umbilicus, the inguinal ligaments, and the superior margin of the pubic symphysis (Figure 30-34 ■).

Assessment of the abdomen involves all four methods of examination (inspection, auscultation, palpation, and percussion).



**Figure 30–34** ■ Landmarks commonly used to identify abdominal areas.

When assessing the abdomen, the nurse performs inspection first, followed by auscultation, percussion, and/or palpation. Auscultation is done before palpation and percussion because palpation and percussion cause movement or stimulation of the bowel, which can increase bowel motility and thus heighten bowel sounds, creating false results. Skill 30–15 describes how to assess the abdomen.

## Assessing the Abdomen

### PLANNING

- Ask the client to urinate since an empty bladder makes the assessment more comfortable.
- Ensure that the room is warm since the client will be exposed.

### DELEGATION

Due to the substantial knowledge and skill required, assessment of the abdomen is not delegated to UAP. However, signs and symptoms of problems may be observed during usual care and should be recorded by those individuals. Abnormal findings must be validated and interpreted by the nurse.

### Equipment

- Examining light
- Tape measure (metal or unstretchable cloth)
- Skin-marking pen
- Stethoscope

### INTERPROFESSIONAL PRACTICE

Assessing the abdomen is within the scope of practice for many health care providers other than nurses. For example, both physician assistants and nutritionists may check the client's abdomen. Although these providers may verbally communicate their findings and plan to other health care team members, the nurse must also know where to locate their documentation in the client's medical record.

### IMPLEMENTATION

#### Performance

1. Prior to performing the procedure, introduce self and verify the client's identity using agency protocol. Explain to the client what you are going to do, why it is necessary, and how he or she can participate. Discuss how the results will be used in planning further care or treatments.
2. Perform hand hygiene and observe other appropriate infection prevention procedures.
3. Provide for client privacy.
4. Inquire if the client has any history of the following: incidence of abdominal pain; its location, onset, sequence, and chronology; its quality (description); its frequency; associated symptoms (e.g., nausea, vomiting, diarrhea); incidence of constipation or diarrhea (have client describe what client means by these

terms); change in appetite, food intolerances, and foods ingested in past 24 hours; specific signs and symptoms (e.g., heartburn, flatulence and/or belching, difficulty swallowing, hematemesis [vomiting blood], blood or mucus in stools, and aggravating and alleviating factors); previous problems and treatment (e.g., stomach ulcer, gallbladder surgery, history of jaundice).

5. Assist the client to a supine position, with the arms placed comfortably at the sides. Place small pillows beneath the knees and the head to reduce tension in the abdominal muscles. Expose the client's abdomen only from the chest line to the pubic area to avoid chilling and shivering, which can tense the abdominal muscles.

#### Assessment

#### Normal Findings

#### Deviations from Normal

#### INSPECTION OF THE ABDOMEN

6. Inspect the abdomen for skin integrity (refer to the discussion of skin assessment earlier in this chapter).



Unblemished skin  
Uniform color

Silver-white striae (stretch marks) or surgical scars

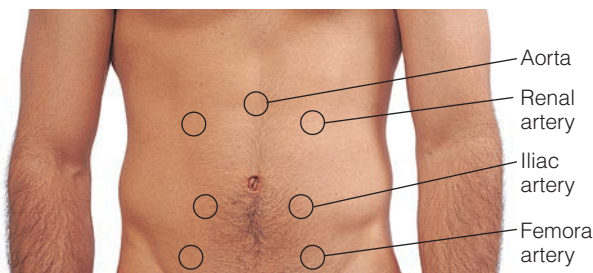
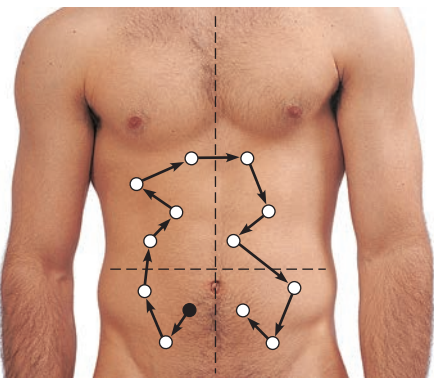
Presence of rash or other lesions  
Tense, glistening skin (may indicate ascites, edema)

Purple striae (associated with Cushing's disease or rapid weight gain and loss)



## Assessing the Abdomen—continued

| Assessment                                                                                                                                                                                                                                                                                                                                                                                                                                                                                                                                                                                                                                                                                                                                                                                    | Normal Findings                                                                                                                                                                               | Deviations from Normal                                                                                                                                                                                                                                                                                                                                                                                                                                                                                                                                                                                                                                                                    |
|-----------------------------------------------------------------------------------------------------------------------------------------------------------------------------------------------------------------------------------------------------------------------------------------------------------------------------------------------------------------------------------------------------------------------------------------------------------------------------------------------------------------------------------------------------------------------------------------------------------------------------------------------------------------------------------------------------------------------------------------------------------------------------------------------|-----------------------------------------------------------------------------------------------------------------------------------------------------------------------------------------------|-------------------------------------------------------------------------------------------------------------------------------------------------------------------------------------------------------------------------------------------------------------------------------------------------------------------------------------------------------------------------------------------------------------------------------------------------------------------------------------------------------------------------------------------------------------------------------------------------------------------------------------------------------------------------------------------|
| <p>7. Inspect the abdomen for contour and symmetry:</p> <ul style="list-style-type: none"> <li>Observe the abdominal contour (profile line from the rib margin to the pubic bone) while standing at the client's side when the client is supine.</li> <li>Ask the client to take a deep breath and to hold it. <b>Rationale:</b> <i>This makes an enlarged liver or spleen more obvious.</i></li> <li>Assess the symmetry of contour while standing at the foot of the bed.</li> <li>If distention is present, measure the abdominal girth by placing a tape around the abdomen at the level of the umbilicus. ① If girth will be measured repeatedly, use a skin-marking pen to outline the upper and lower margins of the tape placement for consistency of future measurements.</li> </ul> | <p>Flat, rounded (convex), or scaphoid (concave)</p> <p>No evidence of enlargement of liver or spleen</p> <p>Symmetric contour</p>                                                            | <p>Distended</p> <p>Evidence of enlargement of liver or spleen</p> <p>Asymmetric contour, e.g., localized protrusions around umbilicus, inguinal ligaments, or scars (possible hernia or tumor)</p>                                                                                                                                                                                                                                                                                                                                                                                                                                                                                       |
|                                                                                                                                                                                                                                                                                                                                                                                                                                                                                                                                                                                                                                                                                                                                                                                               |                                                                                                            | <p>① Measuring abdominal girth.</p>                                                                                                                                                                                                                                                                                                                                                                                                                                                                                                                                                                                                                                                       |
| <p>8. Observe abdominal movements associated with respiration, peristalsis, or aortic pulsations.</p> <p>9. Observe the vascular pattern.</p>                                                                                                                                                                                                                                                                                                                                                                                                                                                                                                                                                                                                                                                 | <p>Symmetric movements caused by respiration</p> <p>Visible peristalsis in very lean people</p> <p>Aortic pulsations in thin people at epigastric area</p> <p>No visible vascular pattern</p> | <p>Limited movement due to pain or disease process</p> <p>Visible peristalsis in nonlean clients (possible bowel obstruction)</p> <p>Marked aortic pulsations</p> <p>Visible venous pattern (dilated veins) is associated with liver disease, ascites, and venocaval obstruction</p>                                                                                                                                                                                                                                                                                                                                                                                                      |
| <p><b>AUSCULTATION OF THE ABDOMEN</b></p> <p>10. Auscultate the abdomen for bowel sounds, vascular sounds, and peritoneal friction rubs. Warm the hands and the stethoscope diaphragms. <b>Rationale:</b> <i>Cold hands and a cold stethoscope may cause the client to contract the abdominal muscles, and these contractions may be heard during auscultation.</i></p> <p><b>For Bowel Sounds</b></p> <ul style="list-style-type: none"> <li>Use the flat-disk diaphragm. ②</li> </ul> <p><b>Rationale:</b> <i>Intestinal sounds are relatively high pitched and best accentuated by the diaphragm.</i> Light pressure with the stethoscope is adequate.</p>                                                                                                                                 | <p>Audible bowel sounds</p>                                                                                                                                                                   | <p>Hypoactive, i.e., extremely soft and infrequent (e.g., one per minute). Hypoactive sounds indicate decreased motility and are usually associated with manipulation of the bowel during surgery, inflammation, paralytic ileus, or late bowel obstruction.</p> <p>Hyperactive/increased, i.e., high-pitched, loud, rushing sounds that occur frequently (e.g., every 3 seconds) also known as borborygmi.</p> <p>Hyperactive sounds indicate increased intestinal motility and are usually associated with diarrhea, an early bowel obstruction, or the use of laxatives.</p> <p>True absence of sounds (none heard in 3 to 5 minutes) indicates a cessation of intestinal motility</p> |
|                                                                                                                                                                                                                                                                                                                                                                                                                                                                                                                                                                                                                                                                                                                                                                                               |                                                                                                            | <p>② Auscultating the abdomen for bowel sounds.</p>                                                                                                                                                                                                                                                                                                                                                                                                                                                                                                                                                                                                                                       |

## Assessing the Abdomen—continued

| Assessment                                                                                                                                                                                                                                                                                                                                                                                                                                                                                                                                                                                                                                                                                                                                                  | Normal Findings                                                                                                                                          | Deviations from Normal                                                                        |
|-------------------------------------------------------------------------------------------------------------------------------------------------------------------------------------------------------------------------------------------------------------------------------------------------------------------------------------------------------------------------------------------------------------------------------------------------------------------------------------------------------------------------------------------------------------------------------------------------------------------------------------------------------------------------------------------------------------------------------------------------------------|----------------------------------------------------------------------------------------------------------------------------------------------------------|-----------------------------------------------------------------------------------------------|
| <ul style="list-style-type: none"> <li>Ask when the client last ate. <b>Rationale:</b> Shortly after or long after eating, bowel sounds may normally increase. They are loudest when a meal is long overdue. Four to 7 hours after a meal, bowel sounds may be heard continuously over the ileocecal valve area (right lower quadrant) while the digestive contents from the small intestine empty through the valve into the large intestine.</li> <li>Place diaphragm of the stethoscope in each of the four quadrants of the abdomen.</li> <li>Listen for active bowel sounds—irregular gurgling noises occurring about every 5 to 20 seconds. The duration of a single sound may range from less than a second to more than several seconds.</li> </ul> |                                                                                                                                                          |                                                                                               |
| <p><b>For Vascular Sounds</b></p> <ul style="list-style-type: none"> <li>Use the bell of the stethoscope over the aorta, renal arteries, iliac arteries, and femoral arteries. <b>3</b></li> <li>Listen for bruits.</li> </ul>                                                                                                                                                                                                                                                                                                                                                                                                                                                                                                                              | <p>Absence of arterial bruits</p>                                                                                                                        | <p>Loud bruit over aortic area (possible aneurysm)<br/>Bruit over renal or iliac arteries</p> |
|                                                                                                                                                                                                                                                                                                                                                                                                                                                                                                                                                                                                                                                                                                                                                             |  <p><b>3</b> Sites for auscultating the vascular sounds.</p>          |                                                                                               |
| <p><b>Peritoneal Friction Rubs</b></p> <ul style="list-style-type: none"> <li>Peritoneal friction rubs are rough, grating sounds like two pieces of leather rubbing together. Friction rubs may be caused by inflammation, infection, or abnormal growths.</li> </ul>                                                                                                                                                                                                                                                                                                                                                                                                                                                                                       | <p>Absence of friction rub</p>                                                                                                                           | <p>Friction rub</p>                                                                           |
| <p><b>PERCUSSION OF THE ABDOMEN</b></p> <p><b>11.</b> Percuss several areas in each of the four quadrants to determine presence of tympany (sound indicating gas in stomach and intestines) and dullness (decrease, absence, or flatness of resonance over solid masses or fluid). Use a systematic pattern: Begin in the lower right quadrant, proceed to the upper right quadrant, the upper left quadrant, and the lower left quadrant. <b>4</b></p>                                                                                                                                                                                                                                                                                                     | <p>Tympany over the stomach and gas-filled bowels; dullness, especially over the liver and spleen, or a full bladder</p>                                 | <p>Large dull areas (associated with presence of fluid or a tumor)</p>                        |
|                                                                                                                                                                                                                                                                                                                                                                                                                                                                                                                                                                                                                                                                                                                                                             |  <p><b>4</b> Systematic percussion sites for all four quadrants.</p> |                                                                                               |

## Assessing the Abdomen—continued

| Assessment                                                                                                                                                                                                                                                                                                                                                                                                                                                                                                                                                                                                                                                                                                                                                                                                                                                                                                                                                                                                                                                                                                                                                                                                                                                          | Normal Findings                                                                                                                                                                                                                                                                              | Deviations from Normal                                                                                                               |
|---------------------------------------------------------------------------------------------------------------------------------------------------------------------------------------------------------------------------------------------------------------------------------------------------------------------------------------------------------------------------------------------------------------------------------------------------------------------------------------------------------------------------------------------------------------------------------------------------------------------------------------------------------------------------------------------------------------------------------------------------------------------------------------------------------------------------------------------------------------------------------------------------------------------------------------------------------------------------------------------------------------------------------------------------------------------------------------------------------------------------------------------------------------------------------------------------------------------------------------------------------------------|----------------------------------------------------------------------------------------------------------------------------------------------------------------------------------------------------------------------------------------------------------------------------------------------|--------------------------------------------------------------------------------------------------------------------------------------|
| <p><b>PALPATION OF THE ABDOMEN</b></p> <p><b>12.</b> Perform light palpation first to detect areas of tenderness and/or muscle guarding. Systematically explore all four quadrants. Ensure that the client's position is appropriate for relaxation of the abdominal muscles, and warm the hands. <b>Rationale:</b> <i>Cold hands can elicit muscle tension and thus impede palpatory evaluation.</i></p> <p><b>Light Palpation</b></p> <ul style="list-style-type: none"> <li>• Hold the palm of your hand slightly above the client's abdomen, with your fingers parallel to the abdomen.</li> <li>• Depress the abdominal wall lightly, about 1 cm or to the depth of the subcutaneous tissue, with the pads of your fingers. <b>5</b></li> <li>• Move the finger pads in a slight circular motion.</li> <li>• Note areas of tenderness or superficial pain, masses, and muscle guarding. To determine areas of tenderness, ask the client to tell you about them and watch for changes in the client's facial expressions.</li> <li>• If the client is excessively ticklish, begin by pressing your hand on top of the client's hand while pressing lightly. Then slide your hand off the client's and onto the abdomen to continue the examination.</li> </ul> | <p>No tenderness; relaxed abdomen with smooth, consistent tension</p>  <p><b>5</b> Light palpation of the abdomen.</p>                                                                                     | <p>Tenderness and hypersensitivity<br/>Superficial masses<br/>Localized areas of increased tension</p>                               |
| <p><b>PALPATION OF THE BLADDER</b></p> <p><b>13.</b> Palpate the area above the pubic symphysis if the client's history indicates possible urinary retention. <b>6</b></p> <p><b>14.</b> Document findings in the client record using printed or electronic forms or checklists supplemented by narrative notes when appropriate.</p>                                                                                                                                                                                                                                                                                                                                                                                                                                                                                                                                                                                                                                                                                                                                                                                                                                                                                                                               | <p>Not palpable</p>  <p><b>6</b> Palpating the bladder.</p>                                                                                                                                               | <p>Distended and palpable as smooth, round, tense mass (indicates urinary retention)</p>                                             |
| <p><b>EVALUATION</b></p> <ul style="list-style-type: none"> <li>• Perform a detailed follow-up examination of other systems based on findings that deviated from expected or normal for the client. Relate findings to previous assessment data if available.</li> </ul>                                                                                                                                                                                                                                                                                                                                                                                                                                                                                                                                                                                                                                                                                                                                                                                                                                                                                                                                                                                            | <p><b>SAMPLE DOCUMENTATION</b></p> <p>5/28/15 0945 c/o "gassy" pain LRQ. No BM x 48 hrs. Ate 75% regular diet yesterday. Abdomen flat. Active bowels sounds all 4 quadrants. Tympany above umbilicus, dull below. No masses palpated. 30 mL milk of magnesia given. _____ N. Schmidt, RN</p> | <ul style="list-style-type: none"> <li>• Report deviations from expected or normal findings to the primary care provider.</li> </ul> |



**LIFESPAN CONSIDERATIONS** Assessing the Abdomen**INFANTS**

- Internal organs of newborns and infants are proportionately larger than those of older children and adults, so their abdomens are rounded and tend to protrude.
- The infant's liver may be palpable 1 to 2 cm (0.4 to 0.8 in.) below the right costal margin.
- Umbilical hernias may be present at birth.

**CHILDREN**

- Toddlers have a characteristic “potbelly” appearance, which can persist until age 3 to 4 years.
- Late preschool and school-age children are leaner and have a flat abdomen.
- Peristaltic waves may be more visible than in adults.
- Children may not be able to pinpoint areas of tenderness; by observing facial expressions the examiner can determine areas of maximum tenderness.
- The liver is relatively larger than in adults. It can be palpated 1 to 2 cm (0.4 to 0.8 in.) below the right costal margin.
- If the child is ticklish, guarding, or fearful, use a task that requires concentration (such as squeezing the hands together) to distract the child, or have the child place his or her hands on yours as you palpate the abdomen, “helping” you to do the exam.

**OLDER ADULTS**

- The rounded abdomens of older adults are due to an increase in adipose tissue and a decrease in muscle tone.
- The abdominal wall is slacker and thinner, making palpation easier and more accurate than in younger clients. Muscle wasting and loss of fibroconnective tissue occur.

- The pain threshold in older adults is often higher; major abdominal problems such as appendicitis or other acute emergencies may therefore go undetected.
- Gastrointestinal pain needs to be differentiated from cardiac pain. Gastrointestinal pain may be located in the chest or abdomen, whereas cardiac pain is usually located in the chest. Factors aggravating gastrointestinal pain are usually related to either ingestion or lack of food intake; gastrointestinal pain is usually relieved by antacids, food, or assuming an upright position. Common factors that can aggravate cardiac pain are activity or anxiety; rest or nitroglycerin relieves cardiac pain.
- Stool passes through the intestines at a slower rate in older adults, and the perception of stimuli that produce the urge to defecate often diminishes.
- Fecal incontinence may occur in adults who are confused or have a neurologic impairment.
- Many older adults believe that the absence of a daily bowel movement signifies constipation. When assessing for constipation, the nurse must consider the client's diet, activity, medications, and characteristics and ease of passage of feces as well as the frequency of bowel movements.
- The incidence of colon cancer is higher among older adults than younger adults. Symptoms include a change in bowel function, rectal bleeding, and weight loss. Changes in bowel function, however, are associated with many factors, such as diet, exercise, and medications.
- Decreased absorption of oral medications often occurs with aging.
- In the liver, impaired metabolism of some drugs may occur with aging.

**Home Care Considerations** Assessing the Abdomen**PATIENT-CENTERED CARE**

- Be sure you have the required equipment on a home visit, including a tape measure and skin-marking pen.
- Use pillows to position the client.
- Undressing the client to perform a complete abdominal examination may not be necessary. Focus the assessment on areas indicated by the history and present complaint.

**MUSCULOSKELETAL SYSTEM**

The musculoskeletal system encompasses the muscles, bones, and joints. The completeness of an assessment of this system depends largely on the needs and problems of the individual client. The nurse usually assesses the musculoskeletal system for muscle strength, tone, size, and symmetry of muscle development, and for tremors. A **tremor** is an involuntary trembling of a limb or body part. Tremors may involve large groups of muscle fibers or small bundles of muscle fibers. An **intention tremor** becomes more apparent when an individual attempts a voluntary movement, such as

holding a cup of coffee. A **resting tremor** is more apparent when the client is relaxed and diminishes with activity. A **fasciculation** is an abnormal contraction of a bundle of muscle fibers that appears as a twitch.

Bones are assessed for normal form. Joints are assessed for tenderness, swelling, thickening, crepitation (a crackling, grating sound), and range of motion. Body posture is assessed for normal standing and sitting positions. For information about body posture, see Chapter 44 ∞. Skill 30–16 describes how to assess the musculoskeletal system.

## Assessing the Musculoskeletal System

### PLANNING

#### DELEGATION

Due to the substantial knowledge and skill required, assessment of the musculoskeletal system is not delegated to UAP. However, many aspects of its functioning are observed during usual care and may be recorded by individuals other than the nurse. Abnormal findings must be validated and interpreted by the nurse.

#### Equipment

- Goniometer
- Tape measure

### IMPLEMENTATION

#### Performance


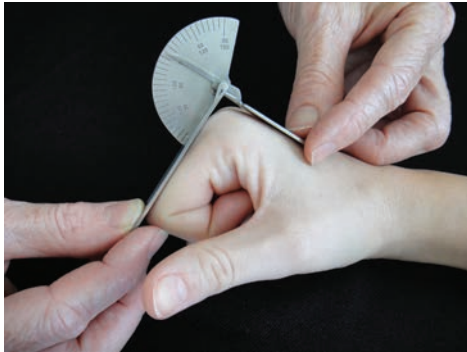
1. Prior to performing the procedure, introduce self and verify the client's identity using agency protocol. Explain to the client what you are going to do, why it is necessary, and how he or she can participate. Discuss how the results will be used in planning further care or treatments.
2. Perform hand hygiene and observe other appropriate infection prevention procedures.
3. Provide for client privacy.
4. Inquire if the client has any history of the following: muscle pain: onset, location, character, associated phenomena (e.g., redness and swelling of joints), and aggravating and alleviating factors; limitations to movement or inability to perform activities of daily living; previous sports injuries; loss of function without pain.

### INTERPROFESSIONAL PRACTICE

Assessing the musculoskeletal system is within the scope of practice for many health care providers other than nurses. For example, both physical therapists and occupational therapists assess the musculoskeletal system as an integral part of their work. Although these providers may verbally communicate their findings and plan to other health care team members, the nurse must also know where to locate their documentation in the client's medical record.

| Assessment                                                                                                                                                                                                                                                                                                                                                                                                                                                                                                                                                                                                                                                                                                                                                                                                                                                                                                                                                                                    | Normal Findings                  | Deviations from Normal                                                                                                                                                                                                                                                                                                                                                                                                                                                                                                  |
|-----------------------------------------------------------------------------------------------------------------------------------------------------------------------------------------------------------------------------------------------------------------------------------------------------------------------------------------------------------------------------------------------------------------------------------------------------------------------------------------------------------------------------------------------------------------------------------------------------------------------------------------------------------------------------------------------------------------------------------------------------------------------------------------------------------------------------------------------------------------------------------------------------------------------------------------------------------------------------------------------|----------------------------------|-------------------------------------------------------------------------------------------------------------------------------------------------------------------------------------------------------------------------------------------------------------------------------------------------------------------------------------------------------------------------------------------------------------------------------------------------------------------------------------------------------------------------|
| <b>MUSCLES</b>                                                                                                                                                                                                                                                                                                                                                                                                                                                                                                                                                                                                                                                                                                                                                                                                                                                                                                                                                                                |                                  |                                                                                                                                                                                                                                                                                                                                                                                                                                                                                                                         |
| <b>5.</b> Inspect the muscles for size. Compare the muscles on one side of the body (e.g., of the arm, thigh, and calf) to the same muscle on the other side. For any discrepancies, measure the muscles with a tape.                                                                                                                                                                                                                                                                                                                                                                                                                                                                                                                                                                                                                                                                                                                                                                         | Equal size on both sides of body | Atrophy (a decrease in size) or hypertrophy (an increase in size), asymmetry                                                                                                                                                                                                                                                                                                                                                                                                                                            |
| <b>6.</b> Inspect the muscles and tendons for contractures (shortening).                                                                                                                                                                                                                                                                                                                                                                                                                                                                                                                                                                                                                                                                                                                                                                                                                                                                                                                      | No contractures                  | Malposition of body part, e.g., foot drop (foot flexed downward)                                                                                                                                                                                                                                                                                                                                                                                                                                                        |
| <b>7.</b> Inspect the muscles for tremors, for example by having the client hold the arms out in front of the body.                                                                                                                                                                                                                                                                                                                                                                                                                                                                                                                                                                                                                                                                                                                                                                                                                                                                           | No tremors                       | Presence of tremor                                                                                                                                                                                                                                                                                                                                                                                                                                                                                                      |
| <b>8.</b> Test muscle strength. Compare the right side with the left side.<br><i>Sternocleidomastoid:</i> Client turns the head to one side against the resistance of your hand. Repeat with the other side.<br><i>Trapezius:</i> Client shrugs the shoulders against the resistance of your hands.<br><i>Deltoid:</i> Client holds arm up and resists while you try to push it down.<br><i>Biceps:</i> Client fully extends each arm and tries to flex it while you attempt to hold arm in extension.<br><i>Triceps:</i> Client flexes each arm and then tries to extend it against your attempt to keep arm in flexion.<br><i>Wrist and finger muscles:</i> Client spreads the fingers and resists as you attempt to push the fingers together.<br><i>Grip strength:</i> Client grasps your index and middle fingers while you try to pull the fingers out.<br><i>Hip muscles:</i> Client is supine, both legs extended; client raises one leg at a time while you attempt to hold it down. | Equal strength on each body side | <b>Grading Muscle Strength</b><br>0: 0% of normal strength; complete paralysis<br>1: 10% of normal strength; no movement, contraction of muscle is palpable or visible<br>2: 25% of normal strength; full muscle movement against gravity, with support<br>3: 50% of normal strength; normal movement against gravity<br>4: 75% of normal strength; normal full movement against gravity and against minimal resistance<br>5: 100% of normal strength; normal full movement against gravity and against full resistance |

## Assessing the Musculoskeletal System—continued

| Assessment                                                                                                                                                                                                                                                                                                                                                                                                                                                                                                                                                                                                                                                                                                                                                          | Normal Findings                                                                                                                                                                                                | Deviations from Normal                                                                                                                                  |
|---------------------------------------------------------------------------------------------------------------------------------------------------------------------------------------------------------------------------------------------------------------------------------------------------------------------------------------------------------------------------------------------------------------------------------------------------------------------------------------------------------------------------------------------------------------------------------------------------------------------------------------------------------------------------------------------------------------------------------------------------------------------|----------------------------------------------------------------------------------------------------------------------------------------------------------------------------------------------------------------|---------------------------------------------------------------------------------------------------------------------------------------------------------|
| <p><i>Hip abduction:</i> Client is supine, both legs extended. Place your hands on the lateral surface of each knee; client spreads the legs apart against your resistance.</p> <p><i>Hip adduction:</i> Client is in same position as for hip abduction. Place your hands between the knees; client brings the legs together against your resistance.</p> <p><i>Hamstrings:</i> Client is supine, both knees bent. Client resists while you attempt to straighten the legs.</p> <p><i>Quadriceps:</i> Client is supine, knee partially extended; client resists while you attempt to flex the knee.</p> <p><i>Muscles of the ankles and feet:</i> Client resists while you attempt to dorsiflex the foot and again resists while you attempt to flex the foot.</p> |                                                                                                                                                                                                                |                                                                                                                                                         |
| <b>BONES</b>                                                                                                                                                                                                                                                                                                                                                                                                                                                                                                                                                                                                                                                                                                                                                        |                                                                                                                                                                                                                |                                                                                                                                                         |
| <p>9. Inspect the skeleton for structure.</p> <p>10. Palpate the bones to locate any areas of edema or tenderness.</p>                                                                                                                                                                                                                                                                                                                                                                                                                                                                                                                                                                                                                                              | <p>No deformities</p> <p>No tenderness or swelling</p>                                                                                                                                                         | <p>Bones misaligned</p> <p>Presence of tenderness or swelling (may indicate fracture, neoplasms, or osteoporosis)</p>                                   |
| <b>JOINTS</b>                                                                                                                                                                                                                                                                                                                                                                                                                                                                                                                                                                                                                                                                                                                                                       |                                                                                                                                                                                                                |                                                                                                                                                         |
| <p>11. Inspect the joint for swelling. Palpate each joint for tenderness, smoothness of movement, swelling, crepitation, and presence of nodules.</p> <p>12. Assess joint range of motion. See Chapter 44  for the types of joint movements.</p> <ul style="list-style-type: none"> <li>Ask the client to move selected body parts. The amount of joint movement can be measured by a <b>goniometer</b>, a device that measures the angle of a joint in degrees. ①</li> </ul>                                                                                                                                                                                                    | <p>No swelling</p> <p>No tenderness, swelling, crepitation, or nodules</p> <p>Joints move smoothly</p> <p>Varies to some degree in accordance with person's genetic makeup and degree of physical activity</p> | <p>One or more swollen joints</p> <p>Presence of tenderness, swelling, crepitation, or nodules</p> <p>Limited range of motion in one or more joints</p> |
|                                                                                                                                                                                                                                                                                                                                                                                                                                                                                                                                                                                                                                                                                 |                                                                                                                                                                                                                |                                                                                                                                                         |
| <p>① A goniometer is used to measure joint angle.</p>                                                                                                                                                                                                                                                                                                                                                                                                                                                                                                                                                                                                                                                                                                               |                                                                                                                                                                                                                |                                                                                                                                                         |
| 13. Document findings in the client record using printed or electronic forms or checklists supplemented by narrative notes when appropriate.                                                                                                                                                                                                                                                                                                                                                                                                                                                                                                                                                                                                                        |                                                                                                                                                                                                                |                                                                                                                                                         |
| <b>EVALUATION</b>                                                                                                                                                                                                                                                                                                                                                                                                                                                                                                                                                                                                                                                                                                                                                   |                                                                                                                                                                                                                |                                                                                                                                                         |
| <ul style="list-style-type: none"> <li>Perform a detailed follow-up examination of other systems based on findings that deviated from expected or normal for the client. Relate findings to previous assessment data if available.</li> </ul>                                                                                                                                                                                                                                                                                                                                                                                                                                                                                                                       | <ul style="list-style-type: none"> <li>Report deviations from expected or normal findings to the primary care provider.</li> </ul>                                                                             |                                                                                                                                                         |

**LIFESPAN CONSIDERATIONS** Assessing the Musculoskeletal System**INFANTS**

- Palpate the clavicles of newborns. A mass and crepitus may indicate a fracture experienced during vaginal delivery. The newborn may also have limited movement of the arm and shoulder on the affected side.
- When the arms and legs of newborns are pulled to extension and released, newborns naturally return to the flexed fetal position.
- Check muscle strength by holding the infant lightly under the arms with feet placed lightly on a table. Infants should not fall through the hands and should be able to bear body weight on their legs if normal muscle strength is present.
- Check infants for developmental dysplasia of the hip (congenital dislocation) by examining for asymmetric gluteal folds, asymmetric abduction of the legs (Ortolani and Barlow tests), or apparent shortening of the femur.
- Infants should be able to sit without support by 8 months of age, crawl by 7 to 10 months, and walk by 12 to 15 months.
- Observe for symmetry of muscle mass, strength, and function.

**CHILDREN**

- Pronation and “toeing in” of the feet are common in children between 12 and 30 months of age.
- Genu varum (bowleg) is normal in children for about 1 year after beginning to walk.
- Genu valgus (knock-knee) is normal in preschool and early school-age children.
- Lordosis (swayback) is common in children before age 5.
- Observe the child in normal activities to determine motor function.

- During the rapid growth spurts of adolescence, spinal curvature and rotation (scoliosis) may appear. Children should be assessed for scoliosis by age 12 and annually until their growth slows. Curvature greater than 10% should be referred for further medical evaluation.
- Muscle mass increases in adolescence, especially as children engage in strenuous physical activity, and requires increased nutritional intake.
- Children are at risk for injury related to physical activity and should be assessed for nutritional status, physical conditioning, and safety precautions in order to prevent injury.
- Adolescent girls who participate extensively in strenuous athletic activities are at risk for delayed menses, osteoporosis, and eating disorders; assessment should include a history of these factors.

**OLDER ADULTS**

- Muscle mass decreases progressively with age, but wide variations are seen among different individuals.
- The decrease in speed, strength, resistance to fatigue, reaction time, and coordination in the older person is due to a decrease in nerve conduction and muscle tone.
- The bones become more fragile and osteoporosis leads to a loss of total bone mass. As a result, older adults are predisposed to fractures and compressed vertebrae.
- In most older adults, osteoarthritic changes in the joints can be observed.
- Note any surgical scars from joint replacement surgeries.

**Home Care Considerations** Assessing the Musculoskeletal System**PATIENT-CENTERED CARE**

- When making a home visit, observe the client in natural movement around the living area. To assess children, have them remove their clothes down to the underwear.
- A complete examination of joints, bone, and muscles may not be necessary. Focus the assessment on areas indicated by the history and present complaint.

**NEUROLOGIC SYSTEM**

A thorough neurologic examination may take 1 to 3 hours; however, routine screening tests are usually done first. If the results of these tests raise questions, more extensive evaluations are made. Three major considerations determine the extent of a neurologic exam: (1) the client's chief complaints, (2) the client's physical condition (i.e., level of consciousness and ability to ambulate) because many parts of the examination require movement and coordination of the extremities, and (3) the client's willingness to participate and cooperate.

Examination of the neurologic system includes assessment of (a) mental status including level of consciousness, (b) the cranial nerves, (c) reflexes, (d) motor function, and (e) sensory function. Parts of the neurologic assessment are performed throughout the health examination. For example, the nurse performs a large part of the mental status assessment during the taking of the history and when observing the client's general appearance. Also, the nurse assesses the function of cranial nerves. Cranial nerves II, III, IV, V, and VI (ophthalmic branch) are assessed with the eyes and vision, and cranial nerve VIII (cochlear branch) is assessed with the ears and hearing.

**Mental Status**

Assessment of mental status reveals the client's general cerebral function. These functions include intellectual (cognitive) as well as emotional (affective) functions.

If problems with use of language, memory, concentration, or thought processes are noted during the nursing history, a more extensive examination is required during neurologic assessment. Major areas of mental status assessment include language, orientation, memory, and attention span and calculation.

**LANGUAGE**

Any defects in or loss of the power to express oneself by speech, writing, or signs, or to comprehend spoken or written language due to disease or injury of the cerebral cortex, is called **aphasia**. Aphasias can be categorized as sensory or receptive aphasia, and motor or expressive aphasia.

Sensory or receptive aphasia is the loss of the ability to comprehend written or spoken words. Two types of sensory aphasia are auditory (or acoustic) aphasia and visual aphasia. Clients with auditory

aphasia have lost the ability to understand the symbolic content associated with sounds. Clients with visual aphasia have lost the ability to understand printed or written figures.

Motor or expressive aphasia involves loss of the power to express oneself by writing, making signs, or speaking. Clients may find that even though they can recall words, they have lost the ability to combine speech sounds into words.

## ORIENTATION

This aspect of the assessment determines the client's ability to recognize other people (*person*), awareness of when and where they presently are (*time* and *place*), and who they, themselves, are (*self*). The terms *disorientation* and *confusion* are often used synonymously although there are differences. It is always preferable to describe the client's actions or statements rather than to label them.

## CLINICAL ALERT!

Nurses often chart that the client is "awake, alert, & oriented x3" (or "times three"). This refers to accurate awareness of persons, time, and place. Remember, "person" indicates that the client recognizes others, not that the client can state what his or her own name is.

## MEMORY

The nurse assesses the client's recall of information presented seconds previously (immediate recall), events or information from earlier in the day or examination (recent memory), and knowledge recalled from months or years ago (remote or long-term memory).

## ATTENTION SPAN AND CALCULATION

This component determines the client's ability to focus on a mental task that is expected to be able to be performed by individuals of normal intelligence.

## Level of Consciousness

Level of consciousness (LOC) can lie anywhere along a continuum from a state of alertness to coma. A fully alert client responds to questions spontaneously; a comatose client may not respond to verbal stimuli. The Glasgow Coma Scale was originally developed to predict recovery from a head injury; however, it is used by many professionals to assess LOC. It tests in three major areas: eye response, motor response, and verbal response. An assessment totaling 15 points indicates the client is alert and completely oriented. A comatose client scores 7 or less (see Table 30–10).

## Cranial Nerves

The nurse needs to be aware of specific nerve functions and assessment methods for each cranial nerve to detect abnormalities. In some cases, each nerve is assessed; in other cases only selected nerve functions are evaluated.

## Reflexes

A **reflex** is an automatic response of the body to a stimulus. It is not voluntarily learned or conscious. The deep tendon reflex (DTR) is

**TABLE 30–10** Levels of Consciousness:  
Glasgow Coma Scale

| Faculty Measured              | Response             | Score               |
|-------------------------------|----------------------|---------------------|
| Eye opening                   | Spontaneous          | 4                   |
|                               | To verbal command    | 3                   |
|                               | To pain              | 2                   |
|                               | No response          | 1                   |
| Motor response                | To verbal command    | 6                   |
|                               | To localized pain    | 5                   |
|                               | Flexes and withdraws | 4                   |
|                               | Flexes abnormally    | 3                   |
|                               | Extends abnormally   | 2                   |
|                               | No response          | 1                   |
|                               | Verbal response      | Oriented, converses |
| Disoriented, converses        |                      | 4                   |
| Uses inappropriate words      |                      | 3                   |
| Makes incomprehensible sounds |                      | 2                   |
| No response                   |                      | 1                   |

activated when a tendon is stimulated (tapped) and its associated muscle contracts. The quality of a reflex response varies among individuals and by age. As a person ages, reflex responses may become less intense.

Reflexes are tested using a percussion hammer. The response is described on a scale of 0 to 4. Experience is necessary to determine appropriate scoring for an individual. Generalist nurses do not commonly assess each of the deep tendon reflexes except for possibly the plantar (Babinski) reflex, indicative of possible spinal cord injury.

## Motor Function

Neurologic assessment of the motor system evaluates proprioception and cerebellar function. Structures involved in proprioception are the proprioceptors, the posterior columns of the spinal cord, the cerebellum, and the vestibular apparatus (which is innervated by cranial nerve VIII) in the labyrinth of the internal ear.

**Proprioceptors** are sensory nerve terminals that occur chiefly in the muscles, tendons, joints, and internal ear. They give information about movements and the position of the body. Stimuli from the proprioceptors travel through the posterior columns of the spinal cord. Deficits of function of the posterior columns of the spinal cord result in impairment of muscle and position sense. Clients with such impairment often must watch their own arm and leg movements to ascertain the position of the limbs.

The cerebellum (a) helps to control posture, (b) acts with the cerebral cortex to make body movements smooth and coordinated, and (c) controls skeletal muscles to maintain equilibrium.

## Sensory Function

Sensory functions include touch, pain, temperature, position, and tactile discrimination. The first three are routinely tested.

Generally, the face, arms, legs, hands, and feet are tested for touch and pain, although all parts of the body can be tested. If the client complains of numbness, peculiar sensations, or paralysis, the practitioner should check sensation more carefully over flexor and extensor surfaces of limbs, mapping out clearly any abnormality of touch or pain by examining responses in the area about every 2 cm (1 in.). This is a lengthy procedure and may be performed by a specialist. Abnormal responses to touch stimuli include loss of sensation (anesthesia); more than normal sensation (hyperesthesia); less than normal sensation (hypoesthesia); or an abnormal sensation such as burning, pain, or an electric shock (paresthesia).

A variety of common health conditions, including diabetes and arteriosclerotic heart disease, result in loss of the protective sensation in the lower extremities. This loss can lead to severe tissue damage. In efforts to identify clients at increased risk for damage to the feet, the Bureau of Primary Health Care of the U.S.

government has established the Lower Extremity Amputation Prevention (LEAP) program. The most important aspect of LEAP is assessment of sensation using a special monofilament that delivers 10 grams of force. Health care providers should perform an initial foot screen on all clients with diabetes and at least annually thereafter. Clients who are at risk should have their feet and shoes evaluated at least four times a year to help prevent foot problems from occurring.

A detailed neurologic examination includes position sense, temperature sense, and tactile discrimination. Three types of tactile discrimination are generally tested: **one- and two-point discrimination**, the ability to sense whether one or two areas of the skin are being stimulated by pressure; **stereognosis**, the act of recognizing objects by touching and manipulating them; and **extinction**, the failure to perceive touch on one side of the body when two symmetric areas of the body are touched simultaneously. Skill 30–17 describes how to assess the neurologic system.

## Assessing the Neurologic System

### PLANNING

If possible, determine whether a screening or full neurologic examination is indicated. This impacts preparation of the client, equipment, and timing.

### DELEGATION

Due to the substantial knowledge and skill required, assessment of the neurologic system is not delegated to UAP. However, many aspects of neurologic behavior are observed during usual care and may be recorded by individuals other than the nurse. Abnormal findings must be validated and interpreted by the nurse.

### IMPLEMENTATION

#### Performance

1. Prior to performing the procedure, introduce self and verify the client's identity using agency protocol. Explain to the client what you are going to do, why it is necessary, and how he or she can participate. Discuss how the results will be used in planning further care or treatments.
2. Perform hand hygiene and observe other appropriate infection prevention procedures.
3. Provide for client privacy.
4. Inquire if the client has any history of the following: presence of pain in the head, back, or extremities, as well as onset and aggravating and alleviating factors; disorientation to time, place, or person; speech disorder; loss of consciousness, fainting, convulsions, trauma, tingling or numbness, tremors or tics, limping, paralysis, uncontrolled muscle movements, loss of memory, mood swings; or problems with smell, vision, taste, touch, or hearing.

### Equipment (Depending on Components of Examination)

- Percussion hammer
- Wisps of cotton to assess light-touch sensation
- Sterile safety pin for tactile discrimination

### INTERPROFESSIONAL PRACTICE

Assessing the neurologic system is within the scope of practice for many health care providers other than nurses. For example, physical therapists, occupational therapists, and physician assistants will assess those aspects of the client's neurologic functioning relevant to their plan of care. Although these providers may verbally communicate their findings and plan to other health care team members, the nurse must also know where to locate their documentation in the client's medical record.

### CLINICAL ALERT!

All questions and tests used in a neurologic examination must be age, language, education level, and culturally appropriate. Individualize questions and tests before using them.

#### Language

5. If the client displays difficulty speaking:
  - Point to common objects, and ask the client to name them.
  - Ask the client to read some words and to match the printed and written words with pictures.
  - Ask the client to respond to simple verbal and written commands (e.g., "point to your toes" or "raise your left arm").

## Assessing the Neurologic System—continued

### Orientation

6. Determine the client's orientation to *time*, *place*, and *person* by tactful questioning. Ask the client the time of day, date, day of the week, duration of illness, city and state of residence, and names of family members.

Ask the client why he or she is seeing a health care provider. Orientation is lost gradually, and early disorientation may be very subtle. "Why" questions may elicit a more accurate clinical picture of the client's orientation status than questions directed to time, place, and person. To evaluate the response, you must know the correct answer.

More direct questioning may be necessary for some people (e.g., "Where are you now?" "What day is it today?") Most people readily accept these questions if initially the nurse asks, "Do you get confused at times?" If the client cannot answer these questions accurately, also include assessment of the *self* by asking the client to state his or her full name.

### Memory

7. Listen for lapses in memory. Ask the client about difficulty with memory. If problems are apparent, three categories of memory are tested: immediate recall, recent memory, and remote memory.

To Assess Immediate Recall

- Ask the client to repeat a series of three digits (e.g., 7-4-3), spoken slowly.
- Gradually increase the number of digits (e.g., 7-4-3-5, 7-4-3-5-6, and 7-4-3-5-6-7-2) until the client fails to repeat the series correctly.
- Start again with a series of three digits, but this time ask the client to repeat them backward. The average person can repeat a series of five to eight digits in sequence and four to six digits in reverse order.

To Assess Recent Memory

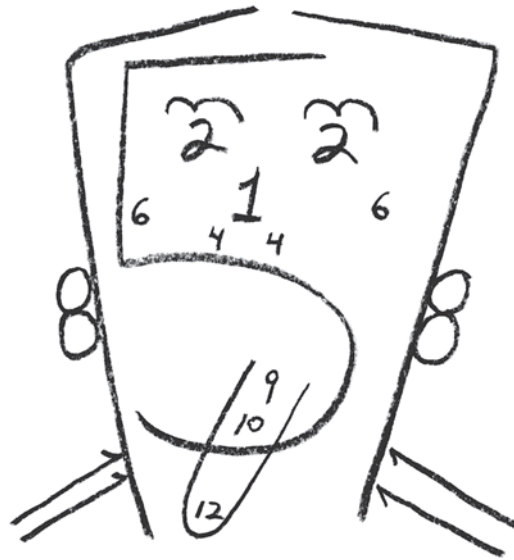
- Ask the client to recall the recent events of the day, such as how the client got to the clinic. This information must be validated, however.
- Ask the client to recall information given early in the interview (e.g., the name of a doctor).
- Provide the client with three facts to recall (e.g., a color, an object, and an address) or a three-digit number, and ask the client to repeat all three. Later in the interview, ask the client to recall all three items.

To Assess Remote Memory

- Ask the client to describe a previous illness or surgery (e.g., 5 years ago) or a birthday or anniversary. Generally remote memory will be intact until late in neurologic pathology. It is least useful in assessing acute neurologic problems.

### Attention Span and Calculation

8. Test the ability to concentrate or maintain *attention span* by asking the client to recite the alphabet or to count backward from 100. Test the ability to calculate by asking the client to subtract 7 or 3 progressively from 100 (i.e., 100, 93, 86, 79, or 100, 97, 94, 91), a task that is referred to as *serial sevens* or *serial threes*. Normally, an adult can complete the serial sevens test in about 90 seconds with three or fewer errors. Because educational level, language, or cultural differences



- 1 Cranial nerves by the numbers. The next time you're trying to remember the locations and functions of the cranial nerves, picture this drawing. All the cranial nerves are represented, though some may be a little harder to spot than others. For example, the shoulders are formed by the number "11" because cranial nerve XI controls neck and shoulder movement. If you immediately recognize that the sides of the face and the top of the head are formed by the number "7" you're well on your way to using this memory device.

Copyright ©2014, HealthCom Media. All rights reserved. *American Nurse Today*, 2006. [www.AmericanNurseToday.com](http://www.AmericanNurseToday.com).

affect calculating ability, this test may be inappropriate for some people.

### Level of Consciousness

9. Apply the Glasgow Coma Scale (see Table 30-10 on page 581): eye response, motor response, and verbal response. An assessment totaling 15 points indicates the client is alert and completely oriented. A comatose client scores 7 or less.

### Cranial Nerves

10. For the specific functions and assessment methods of each cranial nerve, see Table 30-11 on page 590. Test each nerve not already evaluated in another component of the health assessment. A quick way to remember which cranial nerves are assessed in the face is shown in 1.

### CLINICAL ALERT!

The names and order of the cranial nerves can be recalled by a mnemonic device such as "On old Olympus's treeless top, a Finn and German viewed a hop." The first letter of each word in the sentence is the same as the first letter of the name of the cranial nerve, in order.

## Assessing the Neurologic System—continued

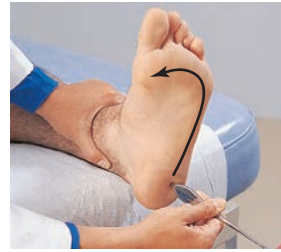**Reflexes**

**11.** Test reflexes using a percussion hammer, comparing one side of the body with the other to evaluate the symmetry of response.

- |    |                                |
|----|--------------------------------|
| 0  | No reflex response             |
| +1 | Minimal activity (hypoactive)  |
| +2 | Normal response                |
| +3 | More active than normal        |
| +4 | Maximal activity (hyperactive) |

*Plantar (Babinski) Reflex* The plantar, or Babinski, reflex is superficial. It may be absent in adults without pathology or overridden by voluntary control.

- Use a moderately sharp object, such as the handle of the percussion hammer, a key, or an applicator stick.
- Stroke the lateral border of the sole of the client's foot, starting at the heel, continuing to the ball of the foot, and then proceeding across the ball of the foot toward the big toe. ②
- Observe the response. Normally, all five toes bend downward; this reaction is negative Babinski. In an abnormal (positive) Babinski response, the toes spread outward and the big toe moves upward.





② Testing the plantar (Babinski) reflex.

**MOTOR FUNCTION**

| Assessment                                                                                                                                                                                                                                    | Normal Findings                                                                                 | Deviations from Normal                                                                                                                                                                                                                                                                                                                 |
|-----------------------------------------------------------------------------------------------------------------------------------------------------------------------------------------------------------------------------------------------|-------------------------------------------------------------------------------------------------|----------------------------------------------------------------------------------------------------------------------------------------------------------------------------------------------------------------------------------------------------------------------------------------------------------------------------------------|
| <p><b>12. Gross Motor and Balance Tests</b><br/>Generally, the Romberg test and one other gross motor function and balance tests are used.</p>                                                                                                |                                                                                                 |                                                                                                                                                                                                                                                                                                                                        |
| <p><b>WALKING GAIT</b><br/>Ask the client to walk across the room and back, and assess the client's gait.</p>                                                                                                                                 | Has upright posture and steady gait with opposing arm swing; walks unaided, maintaining balance | Has poor posture and unsteady, irregular, staggering gait with wide stance; bends legs only from hips; has rigid or no arm movements                                                                                                                                                                                                   |
| <p><b>ROMBERG TEST</b><br/>Ask the client to stand with feet together and arms resting at the sides, first with eyes open, then closed. Stand close during this test.<br/><b>Rationale:</b> <i>This prevents the client from falling.</i></p> | Negative Romberg: may sway slightly but is able to maintain upright posture and foot stance     | Positive Romberg: cannot maintain foot stance; moves the feet apart to maintain stance<br>If client cannot maintain balance with the eyes shut, client may have sensory ataxia (lack of coordination of the voluntary muscles)<br>If balance cannot be maintained whether the eyes are open or shut, client may have cerebellar ataxia |
| <p><b>STANDING ON ONE FOOT WITH EYES CLOSED</b><br/>Ask the client to close the eyes and stand on one foot. Repeat on the other foot. Stand close to the client during this test.</p>                                                         | Maintains stance for at least 5 seconds                                                         | Cannot maintain stance for 5 seconds                                                                                                                                                                                                                                                                                                   |



## Assessing the Neurologic System—continued

| Assessment                                                                                                                                                                                                                                                                         | Normal Findings                                                                                                                                                           | Deviations from Normal                           |
|------------------------------------------------------------------------------------------------------------------------------------------------------------------------------------------------------------------------------------------------------------------------------------|---------------------------------------------------------------------------------------------------------------------------------------------------------------------------|--------------------------------------------------|
| <p><b>HEEL-TOE WALKING</b></p> <p>Ask the client to walk a straight line, placing the heel of one foot directly in front of the toes of the other foot. ③</p>                                                                                                                      | <p>Maintains heel-toe walking along a straight line</p>  <p>③ Heel-toe walking test.</p> | <p>Assumes a wider foot gait to stay upright</p> |
| <p><b>TOE OR HEEL WALKING</b></p> <p>Ask the client to walk several steps on the toes and then on the heels.</p> <p><b>13. Fine Motor Tests for the Upper Extremities</b></p>                                                                                                      | <p>Able to walk several steps on toes or heels</p>                                                                                                                        | <p>Cannot maintain balance on toes and heels</p> |
| <p><b>FINGER-TO-NOSE TEST</b></p> <p>Ask the client to abduct and extend the arms at shoulder height and then rapidly touch the nose alternately with one index finger and then the other. The client repeats the test with the eyes closed if the test is performed easily. ④</p> | <p>Repeatedly and rhythmically touches the nose</p>  <p>④ Finger-to-nose test.</p>    | <p>Misses the nose or gives slow response</p>    |

Continued on page 586

**Assessing the Neurologic System—continued**

SKILL 30-17

**Assessment**

**ALTERNATING SUPINATION AND PRONATION OF HANDS ON KNEES**

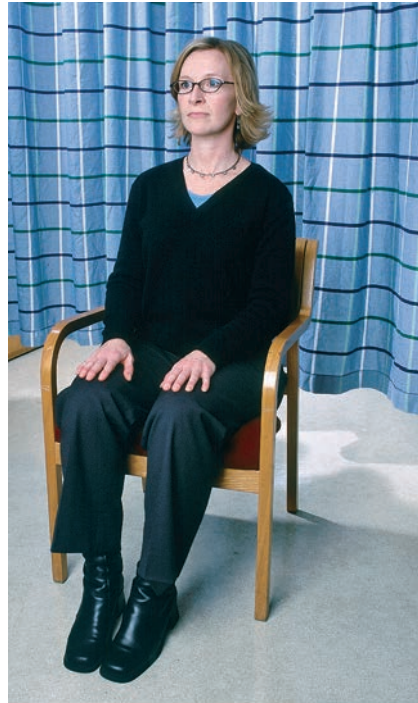Ask the client to pat both knees with the palms of both hands and then with the backs of the hands alternately at an ever-increasing rate. **5**

**Normal Findings**

Can alternately supinate and pronate hands at rapid pace

**Deviations from Normal**

Performs with slow, clumsy movements and irregular timing; has difficulty alternating from supination to pronation



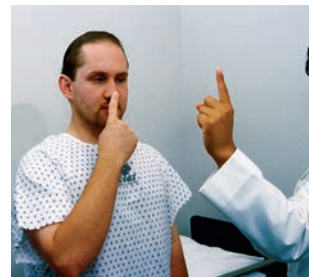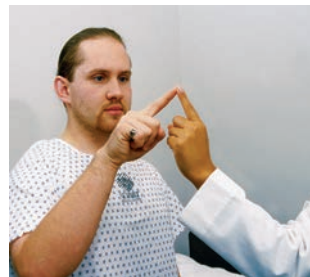**5** Alternating supination and pronation of hands on knees test.

**FINGER-TO-NOSE AND TO THE NURSE'S FINGER**

Ask the client to touch the nose and then your index finger, held at a distance of about 45 cm (18 in.), at a rapid and increasing rate. **6**

Performs with coordination and rapidity

Misses the finger and moves slowly



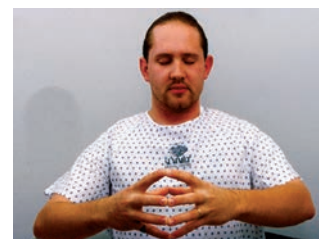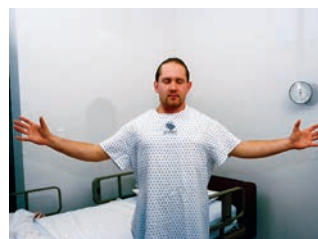**6** Finger-to-nose and to the nurse's finger test.

**FINGERS-TO-FINGERS**

Ask the client to spread the arms broadly at shoulder height and then bring the fingers together at the midline, first with the eyes open and then closed, first slowly and then rapidly. **7**

Performs with accuracy and rapidity

Moves slowly and is unable to touch fingers consistently



**7** Fingers-to-fingers test.

## Assessing the Neurologic System—continued



| Assessment                                                                                                                                                                                                                                                                                                                                                                             | Normal Findings                                                                                                                               | Deviations from Normal                                                             |
|----------------------------------------------------------------------------------------------------------------------------------------------------------------------------------------------------------------------------------------------------------------------------------------------------------------------------------------------------------------------------------------|-----------------------------------------------------------------------------------------------------------------------------------------------|------------------------------------------------------------------------------------|
| <p><b>FINGERS-TO-THUMB (SAME HAND)</b><br/>Ask the client to touch each finger of one hand to the thumb of the same hand as rapidly as possible. <b>8</b></p>                                                                                                                                                                                                                          | <p>Rapidly touches each finger to thumb with each hand</p>  | <p>Cannot coordinate this fine discrete movement with either one or both hands</p> |
| <p><b>14. Fine Motor Tests for the Lower Extremities</b><br/>Ask the client to lie supine and to perform these tests.</p>                                                                                                                                                                                                                                                              |                                                                                                                                               |                                                                                    |
| <p><b>HEEL DOWN OPPOSITE SHIN</b><br/>Ask the client to place the heel of one foot just below the opposite knee and run the heel down the shin to the foot. Repeat with the other foot. The client may also use a sitting position for this test. <b>9</b></p>                                                                                                                         | <p>Demonstrates bilateral equal coordination</p>           | <p>Has tremors or is awkward; heel moves off shin</p>                              |
| <p><b>TOE OR BALL OF FOOT TO THE NURSE'S FINGER</b><br/>Ask the client to touch your finger with the large toe of each foot. <b>10</b></p>                                                                                                                                                                                                                                             | <p>Moves smoothly, with coordination</p>                  | <p>Misses your finger; cannot coordinate movement</p>                              |
| <p><b>15. Light-Touch Sensation</b><br/>Compare the light-touch sensation of symmetric areas of the body. <b>Rationale:</b> <i>Sensitivity to touch varies among different skin areas.</i></p> <ul style="list-style-type: none"> <li>Ask the client to close the eyes and to respond by saying “yes” or “now” whenever the client feels the cotton wisp touching the skin.</li> </ul> | <p>Light tickling or touch sensation</p>                                                                                                      | <p>Anesthesia, hyperesthesia, hypoesthesia, or paresthesia</p>                     |

**8** Fingers-to-thumb (same hand) test.

**9** Heel down opposite shin test.

**10** Toe or ball of foot to nurse's finger test.

## Assessing the Neurologic System—continued

| Assessment                                                                                                                                                                                                                                                                                                                                                                                                                                                                                                                                                                                                                                                                                                                                                                                                                                                       | Normal Findings                                                                                                                                                                                       | Deviations from Normal                                                                         |
|------------------------------------------------------------------------------------------------------------------------------------------------------------------------------------------------------------------------------------------------------------------------------------------------------------------------------------------------------------------------------------------------------------------------------------------------------------------------------------------------------------------------------------------------------------------------------------------------------------------------------------------------------------------------------------------------------------------------------------------------------------------------------------------------------------------------------------------------------------------|-------------------------------------------------------------------------------------------------------------------------------------------------------------------------------------------------------|------------------------------------------------------------------------------------------------|
| <ul style="list-style-type: none"> <li>With a wisp of cotton, lightly touch one specific spot and then the same spot on the other side of the body. <b>11</b></li> <li>Test areas on the forehead, cheek, hand, lower arm, abdomen, foot, and lower leg. Check a distal area of the limb first (i.e., the hand before the arm and the foot before the leg).<br/><b>Rationale:</b> <i>The sensory nerve may be assumed to be intact if sensation is felt at its most distal part.</i></li> <li>If areas of sensory dysfunction are found, determine the boundaries of sensation by testing responses about every 2.5 cm (1 in.) in the area. Make a sketch of the sensory loss area for recording purposes.</li> </ul>                                                                                                                                            |  <p><b>11</b> Assessing light-touch sensation.</p>                                                                  |                                                                                                |
| <p><b>16. Pain Sensation</b><br/>Assess pain sensation as follows:</p> <ul style="list-style-type: none"> <li>Ask the client to close the eyes and to say “sharp,” “dull,” or “don’t know” when the sharp or dull end of a safety pin is felt.</li> <li>Alternately, use the sharp and dull end to lightly prick designated anatomic areas at random (e.g., hand, forearm, foot, lower leg, abdomen). <i>Note:</i> The face is not tested in this manner.</li> <li>Allow at least 2 seconds between each test to prevent summation effects of stimuli (i.e., several successive stimuli perceived as one stimulus).</li> </ul>                                                                                                                                                                                                                                   | <p>Able to discriminate “sharp” and “dull” sensations</p>                                                                                                                                             | <p>Areas of reduced, heightened, or absent sensation (map them out for recording purposes)</p> |
| <p><b>17. Position or Kinesthetic Sensation</b><br/>Commonly, the middle fingers and the large toes are tested for the kinesthetic sensation (sense of position).</p> <ul style="list-style-type: none"> <li>To test the fingers, support the client’s arm and hand with one hand. To test the toes, place the client’s heels on the examining table.</li> <li>Ask the client to close the eyes.</li> <li>Grasp a middle finger or a big toe firmly between your thumb and index finger, and exert the same pressure on both sides of the finger or toe while moving it. <b>12</b></li> <li>Move the finger or toe until it is up, down, or straight out, and ask the client to identify the position.</li> <li>Use a series of brisk, gentle up-and-down movements before bringing the finger or toe suddenly to rest in one of the three positions.</li> </ul> | <p>Can readily determine the position of fingers and toes</p>  <p><b>12</b> Position or kinesthetic sensation.</p> | <p>Unable to determine the position of one or more fingers or toes</p>                         |
| <p><b>18.</b> Document findings in the client record using printed or electronic forms or checklists supplemented by narrative notes when appropriate. Describe any abnormal findings in objective terms, for example, “When asked to count backwards by threes, client made seven errors and completed the task in 4 minutes.”</p>                                                                                                                                                                                                                                                                                                                                                                                                                                                                                                                              |                                                                                                                                                                                                       |                                                                                                |

## LIFESPAN CONSIDERATIONS Assessing the Neurologic System

### INFANTS

- Reflexes commonly tested in newborns include:
  - *Rooting*: Stroke the side of the face near mouth; infant opens mouth and turns to the side that is stroked.
  - *Sucking*: Place nipple or finger 3 to 4 cm (1.2 to 1.6 in.) into mouth; infant sucks vigorously.
  - *Tonic neck*: Place infant supine, turn head to one side; arm on side to which head is turned extends; on opposite side, arm curls up (fencer's pose).
  - *Palmar grasp*: Place finger in infant's palm and press; infant curls fingers around.
  - *Stepping*: Hold infant as if weight bearing on surface; infant steps along, one foot at a time.
  - *Moro*: Present loud noise or unexpected movement; infant spreads arms and legs, extends fingers, then flexes and brings hands together; may cry.
- Most of these reflexes disappear between 4 and 6 months of age.

### CHILDREN

- Present the procedures as games whenever possible.
- Positive Babinski reflex is abnormal after the child ambulates or at age 2.
- For children under age 5, the Denver Developmental Screening Test II provides a comprehensive neurologic evaluation, particularly for motor function.
- Note the child's ability to understand and follow directions.
- Assess immediate recall or recent memory by using names of cartoon characters. Normal recall in children is one less than age in years.
- Assess for signs of hyperactivity or abnormally short attention span.
- Children should be able to walk backward by age 2, balance on one foot for 5 seconds by age 4, heel-toe walk by age 5, and heel-toe walk backward by age 6.
- Use of the Romberg test is appropriate for children ages 3 and older.

### OLDER ADULTS

- Because older adults tire more easily than younger clients, a total neurologic assessment is often done at a different time than the other parts of the physical assessment.

- A full neurologic assessment can be lengthy. Conduct in several sessions if indicated, and cease the tests if the client is noticeably fatigued.
- A decline in mental status is not a normal result of aging. Changes are more the result of physical or psychological disorders (e.g., fever, fluid and electrolyte imbalances, medications). Acute, abrupt-onset mental status changes are usually caused by delirium. These changes are often reversible with treatment. Chronic subtle insidious mental health changes are usually caused by dementia and are usually irreversible.
- Intelligence and learning ability are unaltered with age. Many factors, however, inhibit learning (e.g., anxiety, illness, pain, cultural barrier).
- Short-term memory is often less efficient. Long-term memory is usually unaltered.
- Because old age is often associated with loss of support persons, depression can occur. Mood changes, weight loss, anorexia, constipation, and early morning awakening may be symptoms of depression.
- The stress of being in unfamiliar situations can cause confusion in older adults.
- As a person ages, reflex responses may become less intense.
- Although there is a progressive decrease in the number of functioning neurons in the central nervous system and in the sense organs, older adults usually function well because of the abundant reserves in the number of brain cells.
- Impulse transmission and reaction to stimuli are slower.
- Many older adults have some impairment of hearing, vision, smell, temperature and pain sensation, memory, or mental endurance.
- Coordination changes and includes slower fine finger movements. Standing balance remains intact, and Romberg's test remains negative.
- Reflex responses may slightly increase or decrease. Many show loss of Achilles reflex, and the plantar reflex may be difficult to elicit.
- When testing sensory function, the nurse needs to give older adults time to respond. Normally, older adults have unaltered perception of light touch and superficial pain, decreased perception of deep pain, and decreased perception of temperature stimuli. Many also reveal a decrease or absence of position sense in the large toes.

## FEMALE GENITALS AND INGUINAL AREA

The examination of the genitals and reproductive tract of women includes assessment of the inguinal lymph nodes and inspection and palpation of the external genitals. Completeness of the assessment of the genitals and reproductive tract depends on the needs and problems of the individual client. In most practice settings, generalist nurses perform only inspection of the external genitals and palpation of the inguinal lymph nodes.

For sexually active adolescent and adult women, a Papanicolaou test (Pap test) is used to detect cancer of the cervix. If there is an increased or abnormal vaginal discharge, specimens should be taken to check for a sexually transmitted infection.

Examination of the genitals usually creates uncertainty and apprehension in women, and the lithotomy position required for

an internal examination can cause embarrassment. The nurse must explain each part of the examination in advance and perform the examination in an objective, supportive, and efficient manner. Not all agencies permit male practitioners to examine the female genitals. Some agencies may require the presence of another woman during the examination so that there is no question of unprofessional behavior. Most female clients accept examination by a male, especially if he is emotionally comfortable about performing it and does so in a matter-of-fact and competent manner. If the male nurse does not feel comfortable about this part of the examination or if the client is reluctant to be examined by a man, the nurse should refer this part of the examination to a female practitioner. Skill 30-18 describes how to assess the female genitals and inguinal area.

**TABLE 30–11** Cranial Nerve Functions and Assessment Methods

| Cranial Nerve | Name                         | Type              | Function                                                                                            | Assessment Method                                                                                                                                                                                                                                                                                                                    |
|---------------|------------------------------|-------------------|-----------------------------------------------------------------------------------------------------|--------------------------------------------------------------------------------------------------------------------------------------------------------------------------------------------------------------------------------------------------------------------------------------------------------------------------------------|
| I             | Olfactory                    | Sensory           | Smell                                                                                               | Ask client to close eyes and identify different mild aromas, such as coffee, vanilla, peanut butter, orange/lemon, chocolate.                                                                                                                                                                                                        |
| II            | Optic                        | Sensory           | Vision and visual fields                                                                            | Ask client to read Snellen-type chart; check visual fields by confrontation; and conduct an ophthalmoscopic examination (see Skill 30–6).                                                                                                                                                                                            |
| III           | Oculomotor                   | Motor             | Extraocular eye movement (EOM); movement of sphincter of pupil; movement of ciliary muscles of lens | Assess six ocular movements and pupil reaction (see Skill 30–6).                                                                                                                                                                                                                                                                     |
| IV            | Trochlear                    | Motor             | EOM; specifically, moves eyeball downward and laterally                                             | Assess six ocular movements (see Skill 30–6).                                                                                                                                                                                                                                                                                        |
| V             | Trigeminal Ophthalmic branch | Sensory           | Sensation of cornea, skin of face, and nasal mucosa                                                 | While client looks upward, lightly touch the lateral sclera of the eye with sterile gauze to elicit blink reflex. To test light sensation, have client close eyes, wipe a wisp of cotton over client's forehead and paranasal sinuses. To test deep sensation, use alternating blunt and sharp ends of a safety pin over same areas. |
|               | Maxillary branch             | Sensory           | Sensation of skin of face and anterior oral cavity (tongue and teeth)                               | Assess skin sensation as for ophthalmic branch above.                                                                                                                                                                                                                                                                                |
|               | Mandibular branch            | Motor and sensory | Muscles of mastication; sensation of skin of face                                                   | Ask client to clench teeth.                                                                                                                                                                                                                                                                                                          |
| VI            | Abducens                     | Motor             | EOM; moves eyeball laterally                                                                        | Assess directions of gaze.                                                                                                                                                                                                                                                                                                           |
| VII           | Facial                       | Motor and sensory | Facial expression; taste (anterior two thirds of tongue)                                            | Ask client to smile, raise the eyebrows, frown, puff out cheeks, close eyes tightly. Ask client to identify various tastes placed on tip and sides of tongue: sugar (sweet), salt, lemon juice (sour), and quinine (bitter); identify areas of taste.                                                                                |
| VIII          | Auditory                     |                   |                                                                                                     |                                                                                                                                                                                                                                                                                                                                      |
|               | Vestibular branch            | Sensory           | Equilibrium                                                                                         | Romberg test (see page 584).                                                                                                                                                                                                                                                                                                         |
|               | Cochlear branch              | Sensory           | Hearing                                                                                             | Assess client's ability to hear spoken word and vibrations of tuning fork.                                                                                                                                                                                                                                                           |
| IX            | Glossopharyngeal             | Motor and sensory | Swallowing ability, tongue movement, taste (posterior tongue)                                       | Apply tastes on posterior tongue for identification. Ask client to move tongue from side to side and up and down.                                                                                                                                                                                                                    |
| X             | Vagus                        | Motor and sensory | Sensation of pharynx and larynx; swallowing; vocal cord movement                                    | Assessed with cranial nerve IX; assess client's speech for hoarseness.                                                                                                                                                                                                                                                               |
| XI            | Accessory                    | Motor             | Head movement; shrugging of shoulders                                                               | Ask client to shrug shoulders against resistance from your hands and turn head to side against resistance from your hand (repeat for other side).                                                                                                                                                                                    |
| XII           | Hypoglossal                  | Motor             | Protrusion of tongue; moves tongue up and down and side to side                                     | Ask client to protrude tongue at midline, then move it side to side.                                                                                                                                                                                                                                                                 |

## Assessing the Female Genitals and Inguinal Area

### PLANNING DELEGATION

Due to the substantial knowledge and skill required, assessment of the female genitals and inguinal lymph nodes is not delegated to UAP. However, individuals other than the nurse may record any aspect that is observed during usual care. Abnormal findings must be validated and interpreted by the nurse.

#### Equipment

- Clean gloves
- Drape
- Supplemental lighting, if needed

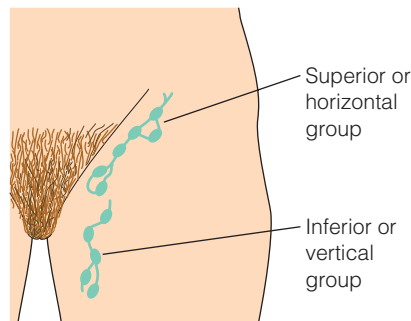
### IMPLEMENTATION

#### Performance

1. Prior to performing the procedure, introduce self and verify the client's identity using agency protocol. Explain to the client what you are going to do, why it is necessary, and how she can participate. Discuss how the results will be used in planning further care or treatments.
2. Perform hand hygiene, apply gloves, and observe other appropriate infection prevention procedures.
3. Provide for client privacy. Request the presence of another health care provider if desired, required by agency policy, or requested by the client.
4. Inquire about the following: age of onset of menstruation, last menstrual period (LMP), regularity of cycle, duration, amount of daily flow, and whether menstruation is painful; incidence of pain during intercourse; vaginal discharge; number of pregnancies, number of live births, labor or delivery complications; urgency and frequency of urination at night; blood in urine, painful urination, incontinence; history of sexually transmitted infection, past and present.
5. Cover the pelvic area with a sheet or drape at all times when the client is not actually being examined. Position the client supine.

#### Assessment

| Assessment                                                                                                                                                             | Normal Findings                                                                                                                                                                                                   | Deviations from Normal                                                                             |
|------------------------------------------------------------------------------------------------------------------------------------------------------------------------|-------------------------------------------------------------------------------------------------------------------------------------------------------------------------------------------------------------------|----------------------------------------------------------------------------------------------------|
| 6. Inspect the distribution, amount, and characteristics of pubic hair.                                                                                                | There are wide variations; generally kinky in the menstruating adult, thinner and straighter after menopause<br>Distributed in the shape of an inverse triangle                                                   | Scant pubic hair (may indicate hormonal problem)<br>Hair growth should not extend over the abdomen |
| 7. Inspect the skin of the pubic area for parasites, inflammation, swelling, and lesions. To assess pubic skin adequately, separate the labia majora and labia minora. | Pubic skin intact, no lesions<br>Skin of vulva area slightly darker than the rest of the body<br>Labia round, full, and relatively symmetric in adult females                                                     | Lice, lesions, scars, fissures, swelling, erythema, excoriations, varicosities, or leukoplakia     |
| 8. Inspect the clitoris, urethral orifice, and vaginal orifice when separating the labia minora.                                                                       | Clitoris does not exceed 1 cm (0.4 in.) in width and 2 cm (0.8 in.) in length<br>Urethral orifice appears as a small slit and is the same color as surrounding tissues<br>No inflammation, swelling, or discharge | Presence of lesions<br>Presence of inflammation, swelling, or discharge                            |
| 9. Palpate the inguinal lymph nodes. ① Use the pads of the fingers in a rotary motion, noting any enlargement or tenderness.                                           | No enlargement or tenderness                                                                                                                                                                                      | Enlargement and tenderness                                                                         |



① Lymph nodes of the groin area.

### INTERPROFESSIONAL PRACTICE

Assessing the female genitals and inguinal area is also within the scope of practice for health care providers other than nurses, specifically physician assistants conducting their own health assessment. Although these providers may verbally communicate their findings and plan to other health care team members, the nurse must also know where to locate their documentation in the client's medical record.

## Assessing the Female Genitals and Inguinal Area—continued

10. Remove and discard gloves. Perform hand hygiene.
11. Document findings in the client record using printed or electronic forms or checklists supplemented by narrative notes when appropriate.

### EVALUATION

- Perform a detailed follow-up examination of other systems based on findings that deviated from expected or normal for the client. Relate findings to previous assessment data if available.
- Significant deviations from normal indicate the need for an internal vaginal examination.

## LIFESPAN CONSIDERATIONS Assessing the Female Genitals and Inguinal Area

### INFANTS

- Infants can be held in a supine position on the parent's lap with the knees supported in a flexed position and separated.
- In newborns, because of maternal estrogen, the labia and clitoris may be edematous and enlarged, and there may be a small amount of white or bloody vaginal discharge.
- Assess the mons and inguinal area for swelling or tenderness that may indicate presence of an inguinal hernia.

### CHILDREN

- Ensure that you have the parent or guardian's approval to perform the examination and then tell the child what you are going to do. Preschool children are taught not to allow others to touch their "private parts."
- Girls should be assessed for Tanner staging of pubertal development (Box 30-9).
- Girls should have a Papanicolaou (Pap) test done if sexually active, or by age 18 years.
- The clitoris is a common site for syphilitic chancres in younger females.

### OLDER ADULTS

- Labia are atrophied and flattened.
- The clitoris is a potential site for cancerous lesions.
- The vulva atrophies as a result of a reduction in vascularity, elasticity, adipose tissue, and estrogen levels. Because the vulva is more fragile, it is more easily irritated.
- The vaginal environment becomes drier and more alkaline, resulting in an alteration of the type of flora present and a predisposition to vaginitis. Dyspareunia (difficult or painful intercourse) is also a common occurrence.
- The cervix and uterus decrease in size.
- The fallopian tubes and ovaries atrophy.
- Ovulation and estrogen production cease.
- Vaginal bleeding unrelated to estrogen therapy is abnormal in older women.
- Prolapse of the uterus can occur in older females, especially those who have had multiple pregnancies.

## BOX 30-9 Five Stages of Pubic Hair Development in Females

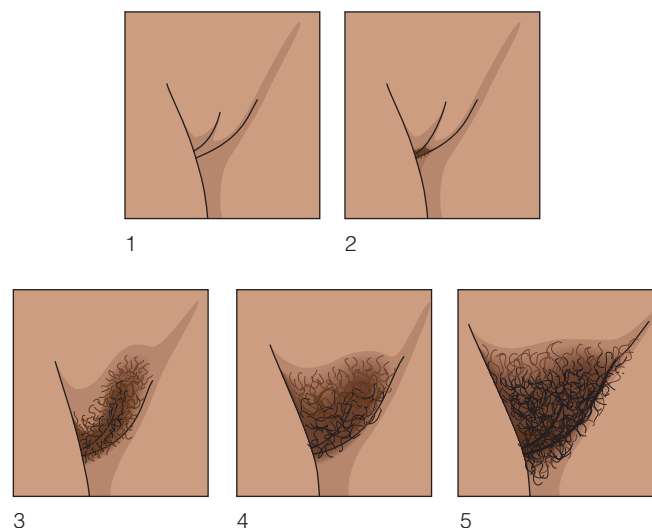
*Stage 1:* Preadolescence. No pubic hair except for fine body hair.

*Stage 2:* Usually occurs at ages 11 and 12. Sparse, long, slightly pigmented curly hair develops along the labia.

*Stage 3:* Usually occurs at ages 12 and 13. Hair becomes darker in color and curlier and develops over the pubic symphysis.

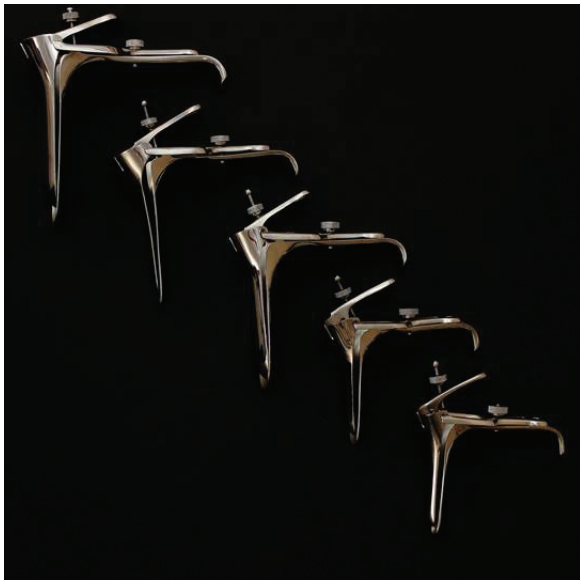*Stage 4:* Usually occurs between ages 13 and 14. Hair assumes the texture and curl of the adult but is not as thick and does not appear on the thighs.

*Stage 5:* Sexual maturity. Hair assumes adult appearance and appears on the inner aspect of the upper thighs (Figure 30-35 ■).



**Figure 30-35** ■ Stages of female pubic hair development.





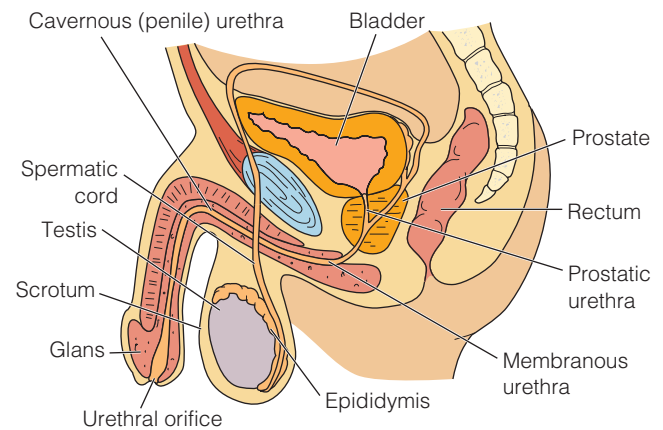
**Figure 30-36** ■ Different sizes of metal vaginal specula.

In many agencies only nurse practitioners examine the internal genitals. However, generalist nurses often assist with this examination and need to be familiar with the procedure. Examination of the internal genitals involves (a) palpating Skene's and Bartholin's glands, (b) assessing the pelvic musculature, (c) inserting a vaginal speculum to inspect the cervix and vagina, and (d) obtaining a Papanicolaou smear.

The speculum examination of the vagina involves the insertion of a plastic or metal speculum that consists of two blades and an adjustable thumb screw. Various sizes are available (small, medium, and large); the appropriate size needs to be selected for each client (Figure 30-36 ■). The speculum may be lubricated with water-soluble lubricant if specimens are not being collected. Most examiners lubricate the speculum with warm water. After visualizing the cervix, the examiner takes smear specimens from one or more of the sites.

The nurse's responsibilities when assisting with an examination of the internal female genitals include the following:

1. **Assembling equipment.** These include drapes, gloves, vaginal speculum, warm water or lubricant, and supplies for cytology and culture studies.
2. **Preparing the client.** Advise the client not to douche prior to the procedure. Explain the procedure. It should take only 5 minutes and is normally not painful. Assist the client to a lithotomy position as needed, and drape her appropriately.
3. **Supporting the client during the procedure.** This involves explaining the procedure as needed, and encouraging the client to take deep breaths that will help the pelvic muscles relax.
4. **Monitoring and assisting the client after the procedure.** Assist the client from the lithotomy position and with perineal care as needed.
5. **Documenting the procedure.** Include the date and time it was performed, the name of the examiner, and any nursing assessments and interventions.



**Figure 30-37** ■ The male urogenital tract.

## MALE GENITALS AND INGUINAL AREA

In adult men, a complete examination includes assessment of the external genitals and prostate gland, and for the presence of any hernias. Nurses in some practice settings performing routine assessment of clients may assess only the external genitals. The male reproductive and urinary systems (Figure 30-37 ■) share the urethra, which is the passageway for both urine and semen. Therefore, in physical assessment of the male these two systems are frequently assessed together.

Examination of the male genitals by a female practitioner is becoming increasingly common, although not all agencies permit a female practitioner to examine the male genitals. Some agencies may require the presence of another person during the examination so that there is no question of unprofessional behavior. Most male clients accept examination by a female, especially if she is emotionally comfortable about performing it and does so in a matter-of-fact and competent manner. If the female nurse does not feel comfortable about this part of the examination or if the client is reluctant to be examined by a woman, the nurse should refer this part of the examination to a male practitioner.

Development of secondary sex characteristics is assessed in relationship to the client's age. See Table 30-12 for the five Tanner stages of the development of pubic hair, the penis, and the testes and scrotum during puberty.

All male clients should be screened for the presence of inguinal or femoral hernias. A **hernia** is a protrusion of the intestine through the inguinal wall or canal. Cancer of the prostate gland is the most common cancer in adult men and occurs primarily in men over age 50. Examination of the prostate gland is performed with the examination of the rectum and anus (see Skill 30-20).

Testicular cancer is much rarer than prostate cancer and occurs primarily in young men ages 15 to 35. Testicular cancer is most commonly found on the anterior and lateral surfaces of the testes. Testicular self-examination should be conducted monthly (see Chapter 40 ∞).

The techniques of inspection and palpation are used to examine the male genitals. Skill 30-19 describes how the nurse can conduct an assessment of the male genitals and inguinal area.

**TABLE 30–12** Tanner Stages of Male Pubic Hair and External Genital Development (12 to 16 Years)

| Stage | Pubic Hair                                                                   | Penis                                               | Testes/Scrotum                                 |
|-------|------------------------------------------------------------------------------|-----------------------------------------------------|------------------------------------------------|
| 1     | None, except for body hair like that on the abdomen                          | Size is relative to body size, as in childhood      | Size is relative to body size, as in childhood |
| 2     | Scant, long, slightly pigmented at base of penis                             | Slight enlargement occurs                           | Becomes reddened in color and enlarged         |
| 3     | Darker, begins to curl and becomes more coarse; extends over pubic symphysis | Elongation occurs                                   | Continuing enlargement                         |
| 4     | Continues to darken and thicken; extends on the sides, above and below       | Increase in both breadth and length; glans develops | Continuing enlargement; color darkens          |
| 5     | Adult distribution that extends to inner thighs, umbilicus, and anus         | Adult appearance                                    | Adult appearance                               |

## Assessing the Male Genitals and Inguinal Area

### PLANNING DELEGATION

Due to the substantial knowledge and skill required, assessment of the male genitals and inguinal area is not delegated to UAP. However, individuals other than the nurse may record any aspect that is observed during usual care. Abnormal findings must be validated and interpreted by the nurse.

### Equipment

- Clean gloves

### INTERPROFESSIONAL PRACTICE

Assessing the male genitals and inguinal area is within the scope of practice for health care providers other than nurses, specifically physician assistants conducting their own health assessment. Although these providers may verbally communicate their findings and plan to other health care team members, the nurse must also know where to locate their documentation in the client's medical record.

## Assessing the Male Genitals and Inguinal Area—continued

### IMPLEMENTATION

#### Performance

- Prior to performing the procedure, introduce self and verify the client's identity using agency protocol. Explain to the client what you are going to do, why it is necessary, and how he can participate. Discuss how the results will be used in planning further care or treatments.
- Perform hand hygiene, apply gloves, and observe other appropriate infection prevention procedures.
- Provide for client privacy. Request the presence of another health care provider if desired, required by agency policy, or requested by the client.
- Inquire about the following: usual voiding patterns and changes, bladder control, urinary incontinence, frequency, urgency, abdominal pain; symptoms of sexually transmitted infection; swellings that could indicate presence of hernia; family history of nephritis, malignancy of the prostate, or malignancy of the kidney.
- Cover the pelvic area with a sheet or drape at all times when not actually being examined.

| Assessment                                                                                                                                                                                                                                                                                                                              | Normal Findings                                                                                                                                                                                                                                                                           | Deviations from Normal                                                                                                                                                    |
|-----------------------------------------------------------------------------------------------------------------------------------------------------------------------------------------------------------------------------------------------------------------------------------------------------------------------------------------|-------------------------------------------------------------------------------------------------------------------------------------------------------------------------------------------------------------------------------------------------------------------------------------------|---------------------------------------------------------------------------------------------------------------------------------------------------------------------------|
| <b>PUBIC HAIR</b>                                                                                                                                                                                                                                                                                                                       |                                                                                                                                                                                                                                                                                           |                                                                                                                                                                           |
| 6. Inspect the distribution, amount, and characteristics of pubic hair.                                                                                                                                                                                                                                                                 | Triangular distribution, often spreading up the abdomen                                                                                                                                                                                                                                   | Scant amount or absence of hair                                                                                                                                           |
| <b>PENIS</b>                                                                                                                                                                                                                                                                                                                            |                                                                                                                                                                                                                                                                                           |                                                                                                                                                                           |
| 7. Inspect the penile shaft and glans penis for lesions, nodules, swellings, and inflammation.                                                                                                                                                                                                                                          | Penile skin intact<br>Appears slightly wrinkled and varies in color as widely as other body skin<br>Foreskin easily retractable from the glans penis<br>Small amount of thick white smegma between the glans and foreskin                                                                 | Presence of lesions, nodules, swellings, or inflammation<br>Foreskin not retractable<br>Large amount, discolored, or malodorous substance                                 |
| 8. Inspect the urethral meatus for swelling, inflammation, and discharge.                                                                                                                                                                                                                                                               | Pink and slitlike appearance<br>Positioned at the tip of the penis                                                                                                                                                                                                                        | Inflammation; discharge<br>Variation in meatal locations (e.g., hypospadias, on the underside of the penile shaft, and epispadias, on the upper side of the penile shaft) |
| <b>SCROTUM</b>                                                                                                                                                                                                                                                                                                                          |                                                                                                                                                                                                                                                                                           |                                                                                                                                                                           |
| 9. Inspect the scrotum for appearance, general size, and symmetry. <ul style="list-style-type: none"> <li>Inspect all skin surfaces by spreading the rugated surface skin and lifting the scrotum as needed to observe posterior surfaces.</li> </ul>                                                                                   | Scrotal skin is darker in color than that of the rest of the body and is loose<br>Size varies with temperature changes (the dartos muscles contract when the area is cold and relax when the area is warm)<br>Scrotum appears asymmetric (left testis is usually lower than right testis) | Discolorations; any tightening of skin (may indicate edema or mass)<br>Marked asymmetry in size                                                                           |
| <b>INGUINAL AREA</b>                                                                                                                                                                                                                                                                                                                    |                                                                                                                                                                                                                                                                                           |                                                                                                                                                                           |
| 10. Inspect both inguinal areas for bulges while the client is standing, if possible. <ul style="list-style-type: none"> <li>First, have the client remain at rest.</li> <li>Next, have the client hold his breath and strain or bear down as though having a bowel movement. Bearing down may make the hernia more visible.</li> </ul> | No swelling or bulges                                                                                                                                                                                                                                                                     | Swelling or bulge (possible inguinal or femoral hernia)                                                                                                                   |
| 11. Remove and discard gloves. Perform hand hygiene.                                                                                                                                                                                                                                                                                    |                                                                                                                                                                                                                                                                                           |                                                                                                                                                                           |
| 12. Document findings in the client record using printed or electronic forms or checklists supplemented by narrative notes when appropriate.                                                                                                                                                                                            |                                                                                                                                                                                                                                                                                           |                                                                                                                                                                           |

### EVALUATION

- Perform a detailed follow-up examination of other systems based on findings that deviated from expected or normal for the client. Relate findings to previous assessment data if available.
- Report deviations from expected or normal findings to the primary care provider.

**LIFESPAN CONSIDERATIONS** Assessing the Male Genitals and Inguinal Area**INFANTS**

- The foreskin of the uncircumcised infant is normally tight at birth and should not be retracted. It will gradually loosen as the baby grows and is usually fully retractable by 2 to 3 years of age. Assess for cleanliness, redness, or irritation.
- Assess for placement of the urethral meatus.
- Palpate the scrotum to determine if the testes are descended; in the newborn and infant, the testes may retract into the inguinal canal, especially with stimulation of the cremasteric reflex.
- Assess the inguinal area for swelling or tenderness that may indicate the presence of an inguinal hernia.

**CHILDREN**

- Ensure that you have the parent or guardian's approval to perform the examination and then tell the child what you are going to do. Preschool children are taught to not allow others to touch their "private parts."

- In young boys, the cremasteric reflex can cause the testes to ascend into the inguinal canal. If possible have the boy sit cross-legged, which stretches the muscle and decreases the reflex.
- Table 30–12 on page 594 shows the five Tanner stages of development of pubic hair, penis, and testes/scrotum.

**OLDER ADULTS**

- The penis decreases in size with age; the size and firmness of the testes decrease.
- Testosterone is produced in smaller amounts.
- More time and direct physical stimulation are required for an older man to achieve an erection, but he may have less premature ejaculation than he did at a younger age.
- Seminal fluid is reduced in amount and viscosity.
- Urinary frequency, nocturia, dribbling, and problems with beginning and ending the stream are usually the result of prostatic enlargement.

**ANUS**

For the generalist nurse, anal examination, an essential part of every comprehensive physical examination, involves only

inspection. Skill 30–20 describes how to assess the rectum and anus.

**Assessing the Anus****PLANNING**  
**DELEGATION**

Due to the substantial knowledge and skill required, assessment of the anus is not delegated to UAP. However, many aspects are observed during usual care and may be recorded by individuals other than the nurse. Abnormal findings must be validated and interpreted by the nurse.

**Equipment**

- Clean gloves

**IMPLEMENTATION****Performance**

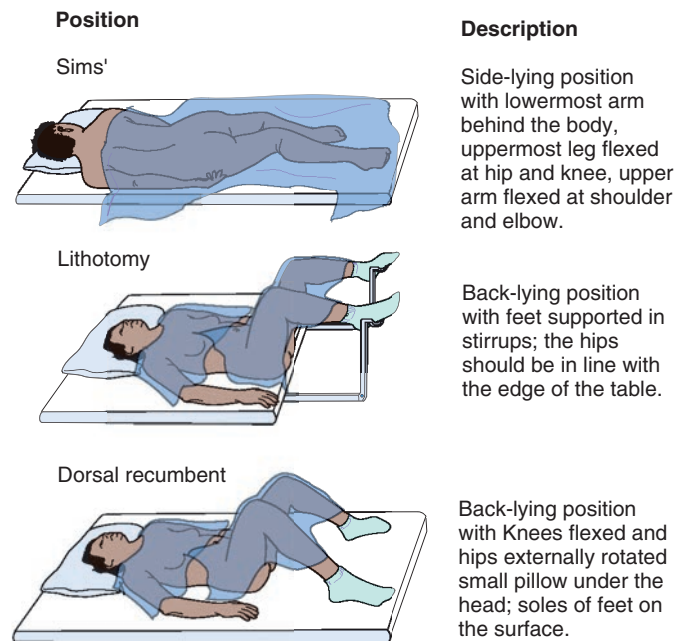
1. Prior to performing the procedure, introduce self and verify the client's identity using agency protocol. Explain to the client what you are going to do, why it is necessary, and how he or she can participate. Discuss how the results will be used in planning further care or treatments.
2. Perform hand hygiene, apply gloves, and observe other appropriate infection prevention procedures for all rectal examinations.
3. Provide for client privacy. Drape the client appropriately to prevent undue exposure of body parts.
4. Inquire if the client has any history of the following: bright blood in stools, tarry black stools, diarrhea, constipation, abdominal

**INTERPROFESSIONAL PRACTICE**

Assessing the anus is within the scope of practice for health care providers other than nurses, specifically physician assistants conducting their own health assessment. Although these providers may verbally communicate their findings and plan to other health care team members, the nurse must also know where to locate their documentation in the client's medical record.

- pain, excessive gas, hemorrhoids, or rectal pain; family history of colorectal cancer; when last stool specimen for occult blood was performed and the results; and for males, if not obtained during the genitourinary examination, signs or symptoms of prostate enlargement (e.g., slow urinary stream, hesitance, frequency, dribbling, and nocturia).
5. Position the client. In adults, a left lateral or Sims' position with the upper leg acutely flexed is required for the examination. A dorsal recumbent position with hips externally rotated and knees flexed or a lithotomy position may be used. 1 For males, a standing position while the client bends over the examining table may also be used.

## Assessing the Anus—continued



1 Left Sims', lithotomy, and dorsal recumbent positions.

| Assessment                                                                                                                                                                                                                                                                                                                                                                                                                                                                                                                                                                                                                           | Normal Findings                                                                                                                                                                                    | Deviations from Normal                                                                                                                                                                                                                                                                                       |
|--------------------------------------------------------------------------------------------------------------------------------------------------------------------------------------------------------------------------------------------------------------------------------------------------------------------------------------------------------------------------------------------------------------------------------------------------------------------------------------------------------------------------------------------------------------------------------------------------------------------------------------|----------------------------------------------------------------------------------------------------------------------------------------------------------------------------------------------------|--------------------------------------------------------------------------------------------------------------------------------------------------------------------------------------------------------------------------------------------------------------------------------------------------------------|
| <p>6. Inspect the anus and surrounding tissue for color, integrity, and skin lesions. Then, ask the client to bear down as though defecating. Bearing down creates slight pressure on the skin that may accentuate rectal fissures, rectal prolapse, polyps, or internal hemorrhoids. Describe the location of all abnormal findings in terms of a clock, with the 12 o'clock position toward the pubic symphysis.</p> <p>7. Remove and discard gloves. Perform hand hygiene.</p> <p>8. Document findings in the client record using printed or electronic forms or checklists supplemented by narrative notes when appropriate.</p> | <p>Intact perianal skin; usually slightly more pigmented than the skin of the buttocks. Anal skin is normally more pigmented, coarser, and moister than perianal skin and is usually hairless.</p> | <p>Presence of fissures (cracks), ulcers, excoriations, inflammations, abscesses, protruding hemorrhoids (dilated veins seen as reddened protrusions of the skin), lumps or tumors, fistula openings, or rectal prolapse (varying degrees of protrusion of the rectal mucous membrane through the anus).</p> |

**EVALUATION**

- Perform a detailed follow-up examination based on findings that deviated from expected or normal for the client. Relate findings to previous assessment data if available.
- Report deviations from expected or normal findings to the primary care provider.

**LIFESPAN CONSIDERATIONS** Assessing the Anus**INFANTS**

- Lightly touching the anus should result in a brief anal contraction ("wink" reflex).

**CHILDREN**

- Erythema and scratch marks around the anus may indicate a pinworm parasite. Children with this condition may be disturbed by itching during sleep.

**OLDER ADULTS**

- Chronic constipation and straining at stool cause an increase in the frequency of hemorrhoids and rectal prolapse.



## Critical Thinking Checkpoint

A 75-year-old woman is admitted to your unit for evaluation after being found unconscious on the floor of her apartment. She is now awake but moving slowly. Her vital signs are within normal limits.

1. In the hospital, it is unrealistic to expect to be able to spend an uninterrupted 30 to 60 minutes with a single client performing an admission assessment. Which three systems would have top priority for her initial assessment and why?
2. While gathering relevant history data, what should you do if the client answers with simple one-word answers or gestures?
3. Because the client may be in significant discomfort from her fall, it is not easy for her to move about for the examination. How might you organize your assessment to minimize her need to change positions frequently?
4. If the client is unable to provide a detailed recent history, what other sources of these data could you consider?

See Critical Thinking Possibilities on student resource website.

# Chapter 30 Review

## CHAPTER HIGHLIGHTS

- The health examination is conducted to assess the function and integrity of the client's body parts. Initial findings provide baseline data against which subsequent assessment findings are compared.
- The health examination may entail a complete head-to-toe assessment or individual assessment of a body system or body part.
- The health assessment is conducted in a systematic manner that requires the fewest position changes for the client.
- Data obtained in the physical health examination supplement, confirm, or refute data obtained during the nursing history.
- Aspects of the physical assessment procedures should be incorporated in the assessment, intervention, and evaluation phases of the nursing process.
- Nursing history data help the nurse focus on specific aspects of the physical health examination.
- Data obtained in the physical health examination help the nurse establish nursing diagnoses, plan the client's care, and evaluate the outcomes of nursing care.
- Skills in inspection, palpation, percussion, and auscultation are required for the physical health examination; these skills are used in that order throughout the examination except during abdominal assessment, when auscultation follows inspection and precedes percussion and palpation.
- Knowledge of the normal structure and function of body parts and systems is an essential requisite to conducting physical assessment.

## TEST YOUR KNOWLEDGE

1. Which is a normal finding on auscultation of the lungs?
  1. Tympany over the right upper lobe
  2. Resonance over the left upper lobe
  3. Hyperresonance over the left lower lobe
  4. Dullness above the left 10th intercostal space
2. The nurse positions the client sitting upright during palpation of which area?
  1. Abdomen
  2. Genitals
  3. Breast
  4. Head and neck
3. After auscultating the abdomen, the nurse should report which finding to the primary care provider?
  1. Bruit over the aorta
  2. Absence of bowel sounds for 60 seconds
  3. Continuous bowel sounds over the ileocecal valve
  4. A completely irregular pattern of bowel sounds
4. If unable to locate the client's popliteal pulse during a routine examination, what should the nurse do next?
  1. Check for a pedal pulse.
  2. Check for a femoral pulse.
  3. Take the client's blood pressure on that thigh.
  4. Ask another nurse to try to locate the pulse.
5. Which of the following is an expected finding during assessment of the older adult?
  1. Facial hair that becomes finer and softer
  2. Decreased peripheral, color, and night vision
  3. Increased sensitivity to odors
  4. An irregular respiratory rate and rhythm at rest
6. List five aspects of the skin that the nurse assesses during a routine examination.
  - 1.
  - 2.
  - 3.
  - 4.
  - 5.

7. If the client reports loss of short-term memory, the nurse would assess this using which one of the following?
  1. Have the client repeat a series of three numbers, increasing to eight if possible.
  2. Have the client describe his or her childhood illnesses.
  3. Ask the client to describe how he or she arrived at this location.
  4. Ask the client to count backward from 100 subtracting seven each time.
8. Refer back to Figure 30–14. If the client can accurately read only the top three lines, what would be an appropriate nursing diagnosis?
  1. *Deficient Knowledge*
  2. *Impaired Memory*
  3. *Ineffective Tissue Perfusion*
  4. *Risk for Injury*
9. To palpate lymph nodes, the nurse uses which technique?
  1. Use the flat of all four fingers in a vertical and then side-to-side motion.
  2. Use the back of the hand and feel for temperature variation between the right and left sides.
  3. Use the pads of two fingers in a circular motion.
  4. Compress the nodes between the index fingers of both hands.
10. For a client whose assessment of the musculoskeletal system is normal, which does the nurse check on the medical record? (Select all that apply.)
  1.  Atrophied
  2.  Contractured
  3.  Crepitation
  4.  Equal
  5.  Firm
  6.  Flaccid
  7.  Hypertrophied
  8.  Spastic
  9.  Symmetrical
  10.  Tremor

See Answers to Test Your Knowledge in Appendix A.

## READINGS AND REFERENCES

### Suggested Reading

Stanley, S., & Laugharne, J. (2014). The impact of lifestyle factors on the physical health of people with a mental illness: A brief review. *International Journal of Behavioral Medicine*, 21, 275–281. doi:10.1007/s12529-013-9298-x  
*Because individuals with a mental illness are more likely to experience poor physical health than the general population, the nurse should conduct a detailed physical health assessment in this population. This paper reviews existing evidence relating to lifestyle factors among the mentally ill such as low exercise levels, poor diet and nutrition, high cholesterol levels, tobacco smoking and poor dental care, contributing to poor physical health such as a higher incidence of cardiovascular disease and type 2 diabetes.*

### Related Research

Martyn, K. L., Munro, M. L., Darling-Fisher, C. S., Ronis, D. L., Villarruel, A. M., Pardee, M., . . . Fava, N. M. (2013). Patient-centered communication and health assessment with youth. *Nursing Research*, 62, 383–393. doi:10.1097/NNR.0000000000000005

### References

- Bolek, B. (2006). Strictly clinical: Facing cranial nerve assessment. *American Nurse Today*, 1(2), 21–22.
- D'Amico, D., & Barbarito, C. (2012). *Health and physical assessment in nursing* (2nd ed.). Upper Saddle River, NJ: Pearson.
- de Vries Feyens, C., & de Jager, C. P. (2011). Images in clinical medicine: Decreased skin turgor. *New England Journal of Medicine*, 364(4), e6. doi:10.1056/NEJMicm1005144
- Smith, R. A., Manassaram-Baptiste, D., Brooks, D., Cokkinides, V., Doroshenk, M., Saslow, D., . . . Brawley, O. W. (2014). Cancer screening in the United States, 2014: A review of current American Cancer Society guidelines and current issues in cancer screening. *CA: A Cancer Journal for Clinicians*, 64, 31–51. doi:10.3322/caac.21212
- U.S. Preventive Services Task Force. (2009). Screening for breast cancer: U.S. Preventive Services Task Force recommendation statement. *Annals of Internal Medicine*, 151, 716–726. doi:10.7326/0003-4819-151-10-200911170-00008
- Weichbold, V., Holzer, A., Newesely, G., & Stephan, K. (2012). Results from high-frequency hearing screening in 14- to

15-year-old adolescents and their relation to self-reported exposure to loud music. *International Journal of Audiology*, 51, 650–654. doi:10.3109/14992027.2012.679747

### Selected Bibliography

- Bickley, L. S. (2012). *Bates' guide to physical examination and history taking* (12th ed.). Philadelphia, PA: Lippincott Williams & Wilkins.
- Jarvis, C. (2011). *Physical examination & health assessment* (6th ed.). St. Louis, MO: Elsevier.
- Rhoads, J., & Petersen, S. W. (2011). *Advanced health assessment and diagnostic reasoning* (2nd ed.). Burlington, MA: Jones & Bartlett.

## Meeting the Standards

*Vital Signs and Health Assessment*, the chapters in Unit 7 of *Fundamentals of Nursing: Concepts, Process, and Practice*, cover the most common knowledge, skills, and attitudes required of every registered nurse. Although the nurse does not perform the full spectrum of these activities during each encounter, at least some of the assessments are always essential in providing professional nursing care. Many other practitioners also perform the techniques of gathering the available data regarding clients' temperature, pulses, respirations, blood pressure, oxygen saturation, and systems functioning. However, it is the nurse's interpretation and responses to the data that have an impact on the client's health.

**Scenario:** Imagine that you are working the evening shift in a hospital on a general medical unit. As the registered nurse, you share an assignment of clients with an unlicensed nursing assistant. You have worked with this assistant previously and know that she does her work in an efficient and accurate manner. You are able to communicate effectively with her because she asks questions when she needs clarification and she reports relevant client data as indicated.

Among the clients you and the assistant are caring for are a female adult receiving intravenous chemotherapy for lung cancer, a female adult with a possible deep venous thrombosis, and a male adult who has chronic obstructive lung disease (COPD).

### Questions

**American Nurses Association Standard of Professional Performance #10 is Quality of Practice:** *The registered nurse systematically enhances the quality and effectiveness of nursing practice. This involves documenting the nursing process, and using creativity and quality improvement strategies to enhance client care.*

When you auscultate the lungs of the client with lung disease, you hear bronchovesicular sounds in the upper and middle lobes and adventitious sounds in both left and right lower lobes. The client reports no significant changes in the previous 24 hours and vital signs are substantially the same as previously. The day shift nurse had reported that the client's lungs were clear throughout, and the previous night shift nurse did not record the results of auscultated lung sounds in the client record.

1. How does this situation relate to Standard #10? Do you see opportunities to improve the quality of practice? Beyond the care of this individual client, what might you do to ensure that the nurses on this unit meet the competencies of the standard?

**American Nurses Association Standard of Professional Performance #14 is Professional Practice Evaluation:** *The registered nurse evaluates one's own nursing practice in relation to professional practice standards and guidelines, relevant statutes, rules, and regulations. This evaluation includes providing care that is appropriate for clients of different ages, cultures, and ethnicities; uses peer feedback; and incorporates evidence-based actions as part of the evaluation process.*

2. Imagine that when you assess the peripheral pulses of the client with a suspected thrombus, you have difficulty feeling the

dorsalis pedis or posterior tibial pulses on either leg. Considering the standard, what actions would be consistent with professional practice evaluation? Would your actions differ if this was the first time you had such difficulty or if you frequently find you are unable to palpate pedal pulses?

**American Nurses Association Standard of Professional Performance #15 is Resource Utilization:** *The registered nurse utilizes appropriate resources to plan and provide nursing services that are safe, effective, and financially responsible. This standard holds the registered nurse accountable for assessing client needs, allocating resources based on client needs, delegating care to others, and modifying practice as needed.*

In the scenario described, you will likely do all of those things. You have delegated the measurement of vital signs for all three clients to the assistant.

3. The assistant measures vital signs at 1600 and reports to you immediately that the client receiving chemotherapy has an oral temperature of 40°C (104°F). Describe your thinking in interpreting this data. What would be your response/next steps? List at least four things you would do and explain why they are necessary and appropriate.
4. In retrospect, do you think you should not have delegated measuring the vital signs on this client to the assistant? Why or why not?

American Nurses Association. (2010). *Nursing: Scope and standards of practice* (2nd ed.). Silver Spring, MD: Author.

See Suggested Answers to End-of-Unit Meeting the Standards Questions on student resource website.